

# Active Contour Based Developmental Hip Dysplasia Diagnosis with Graf Method

Kerim Kürşat ÇEVİK<sup>\*1</sup>, Hasan Erdinç KOÇER<sup>2</sup>

Accepted 3<sup>rd</sup> September 2016

**Abstract:** In this article, a study was carried on ultrasound (US) images for the automatic diagnosis of the disease of the developmental hip dysplasia (DDH). It was aimed with this study at minimizing the errors of the experts in DDH diagnosis. As a first step in the study; commonly known as the images and reduce noise in the US image, image filter are applied to improve the quality. In the second stage; by using Active Contour Model method it was determined acetabular roof and labrum areas. In the third stage; alpha and beta angles that is necessary to be applied Graf method and used DDH diagnosis are determined by using various morphological image algorithms on the image. In the last stage, the classification of Graf method was made and the performance of the system was measured by comparing expert data and the results. According to type conditions of Graf method, in the images of 40 out of 50 it was found the same due to software which was designed with expert data. In the remaining 10 images, expert result and program result are rather close especially for alpha angle. As a result, the success rate of the system for the 50 image is 80%. When considered the parameters such as the difficulty of physical examination of DDH diagnosis, decreasing quality of life in the people suffered from this disease, limb shortening, limping, functional disability, treatment costs, based on expert data and relativism of applying of Graf method on US images, the importance of DDH diagnosis system supported computer is seen.

**Keywords:** Developmental Hip Dysplasia, Ultrasound, Active Contour Model, Image Processing.

## 1. Introduction

Developmental dysplasia of the hip (DDH) is structural dysfunctionality resulted from or dislocation of the hip, femur (thigh) head and acetabulum (cup). The incidence of this disease prevalence (of which the risk of) in the world identified as 1/3000 higher than in Japan and the Mediterranean Basin [1]. DDH can be treated successfully with early diagnosis. Delays in diagnosis and treatment of extremity (limb) brevity can cause restricted movement disorders such as claudication and functional disability. Diagnosed in the newborn period and successful in 96% of infants who were treated as anatomical and radiological can be obtained in normal development [2]. There is no chance of conservative treatment in the children that are in toddler age. To get successful results in all cases with surgical treatments is also impossible. Even if surgical treatment is successful, negativities is too large to be ignored [3].

To determine DDH incidence, differences in the definition of this abnormal situation in the hips, method differences in examining of hip, knowledge level of the person carrying out the examination vary depending on the characteristics of the studied communities. The incidence of approximately 1 in 1000 births, birth is stated to range between 100 3-4 [4]. Physical examination and ultrasonography (US) seen with higher frequency are determined by imaging [4].

Scanning hip US widely used in the world. The reason is that cheap sonography extremely common and safe. It is estimated that by introducing the world every four base units [5]. Furthermore, US usage is to diagnose the possibility of eliminating the risk of radiation intake in new-born infants.

US findings and hip development disorder can be defined, and

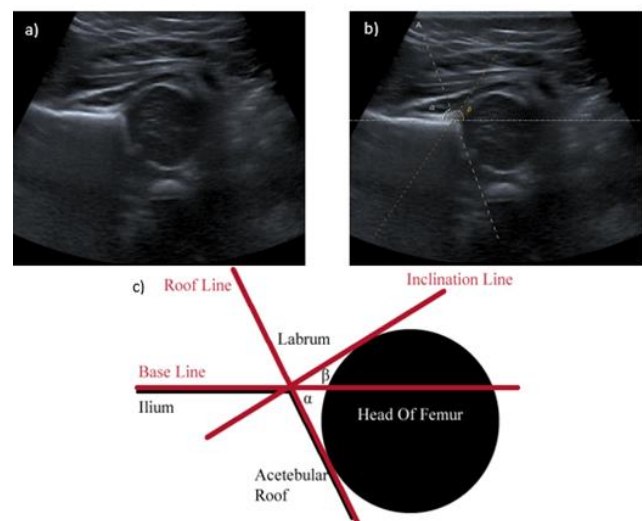
<sup>1</sup> Nigde University Bor Vocational High School, 51700, Turkey

<sup>2</sup> Selcuk University Technical Education Faculty, 42250, Turkey

\* Corresponding Author: Email: [kcevik@ohu.edu.tr](mailto:kcevik@ohu.edu.tr)

Note: This paper has been presented at the 3<sup>rd</sup> International Conference on Advanced Technology & Sciences (ICAT'16) held in Konya (Turkey), September 01-03, 2016.

treatment can be planned. Technically, Graf, Mortar, Harcke, and Terjesen methods are used [5]. Graf method is easy to learn compared to other methods is a simple method and is the most popular method worldwide hip US [6]. Europe has long been used in the study of new-born hip [7].

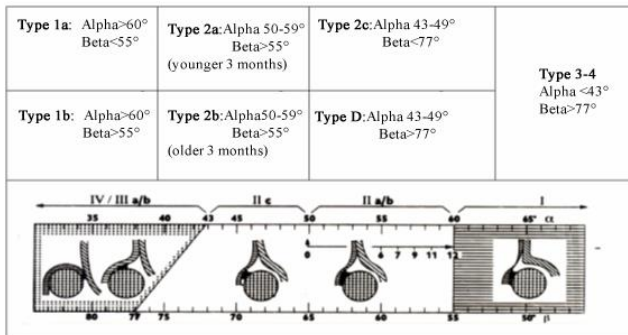


**Figure 1.** US image for the diagnosis of DDH: a) raw image, b) manually determined  $\alpha$  and  $\beta$  angles, c) diagnosis of DDH

Graf method is typing of hip morphology of hip angles that was measured on sonogram, and this was carried on tilted baby, and this is imagined on trochanter major in the standard plan of specific anatomical points with parallel placed the transducer to the body axis. Then the image shown in the standard plan and as seen in Figure 1, the hip joint angles ( $\alpha$  and  $\beta$ ) is determined by the value morphology [8]. However, overall poor image quality makes it difficult to determine the angle of the hip joint radiologist.

Roof angle alpha bone, cartilage roof gives information about the beta angle. There is a relationship between decrease in the value of the acetabular angle alpha and dysplasia, and in clinical studies, alpha angle lower thighs is seen as the hip that can be dislocated [9].

The Graf method is examined four groups in hip ultrasound identification. Alpha angle values are used in the original grouping. Beta angle values are secondary typing (type 1a-1b and type 2c-D in differentiation), the baby several months by type 2a-2b distinction, such as whether the labral degeneration 3a-3b distinction and perichondrium morphology types used in 3-4 divisions (Figure 2) [10].



**Figure 2.** Types of hip according to Graf classification

There are very few studies in the literature related to computer-aided diagnosis of DDH. The first study in the literature that was tried to recognize automatically is seen in 1998. Overhoff et al. [11] undertook a study on femoral automatically detect over 10 different images. not found any information about the performance of the system. Luis-Garcia and Lopez-Alberola have done several studies on the diagnosis of DDH. In their study, they tried to determine femur and acetabulum areas by segmenting US images. In their first study based on dividing of muscle area that are nonlinear and in this study, Dynamic Shape Priors method was used. Dynamic way of priority was also used in these studies, they suggested automatic creating in segmentation flow as well as anatomical knowledge. In their studies, they reported that the first impressions on real images showed promising results [12]. In 2006, they presented segmentation method for hip joint from 3D ultrasound data. Kullback-Leibler distance measurement is used as the actual difference measure; energy minimization is performed by estimating the optimal parameters of sphere and parabolic so that the femoral head and the acetabulum easier segmentation. Experimental results for a number of data set in this study; this approach has shown that the success of using simple geometric approach to the anatomy of the hip joint [13]. In 2007, ultrasound images of based on the Rayleigh distribution parameter which  $\sigma$ 'n local estimate of for analysing the ultrasound signal to have a new technique adopted as a model, the local estimator, the original ultrasound image conversion, it has been observed that the hip ultrasound images of increasing the feasibility allocated between different regions on [14]. Han-Yang et al., tried to implement a computer-aided design system for the treatment of DDH. Firstly, they used classic segmentation method in their studies, but they reported that these methods were giving unreliable results because of the difficulty of processing the images of US. Then they used a mixture of images-based algorithm for partial-volume segmentation and stated that they have achieved remarkable results [15].

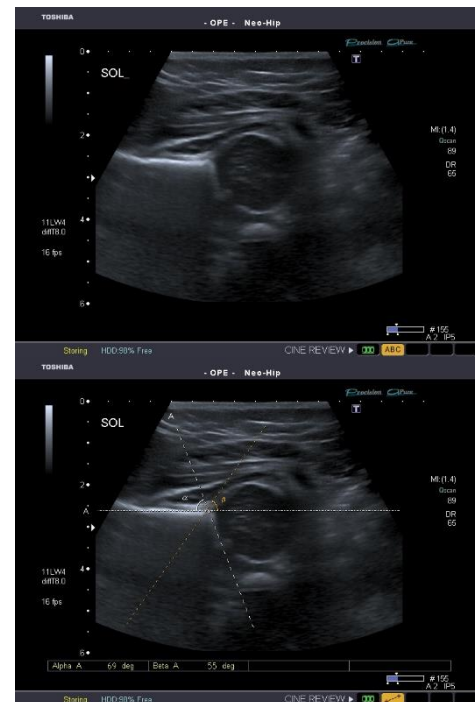
In the dividing of US images used in diagnosis of DDH disease is seen not fully achieved results. By this study, this operation to be

made independent from the DDH experts fault diagnosis it is provided with a high success rate.

## 2. Material

In the study, it was benefited from the US images used to diagnose DDH. Images are taken from Selcuk University Faculty of Medicine, Radiology Department. The US device used to collect the images is Toshiba Aplio 400. Image set, each image section has been created under the supervision of specialist doctors radiologists examined individually. It was provided to be labelled correctly by using radiology report depending on the images taken in the standard form of sonogram. Besides the raw images obtained, there are also images that have been diagnosed by the experts according to Graf method.

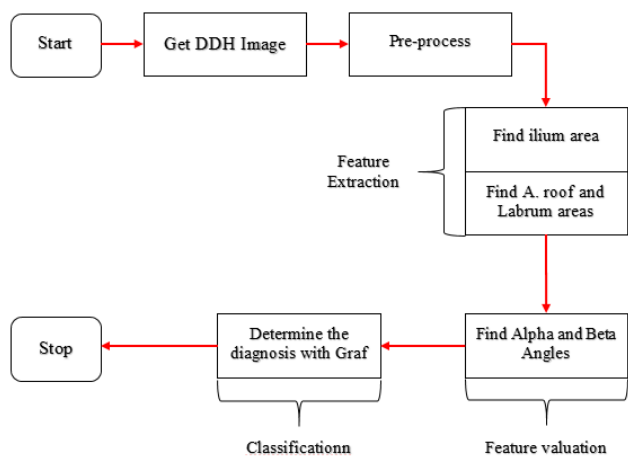
The raw hip US images is gray level and the JPEG format. Images are irrelevant background areas in 800x600 pixels. US raw images obtained for use in this study and a sample image is diagnosed by the expert according to the state of the Graf method is given in Figure 3. A total of 25 patients, including 50 from the right and left hip image were obtained. Patients' ages ranged from 0-3 months.



**Figure 3.** The ultrasound images used in the study a) raw image b) diagnosed image

## 3. Method

In this study, a software was performed by using image processing techniques to provide the computer-aided diagnosis of DDH disease. Figure 4 shows a block diagram of the study.



**Figure 4.** The image processing steps used in the study

Overall poor image quality makes it difficult to determine the angle of the hip joint for radiologist. Therefore, as the first; commonly known as the images and reduce noise in the US image, image filters have been applied to improve the quality (Mean, Median, Gaussian, Wiener, Perona & Malik Lee Frost). The most effective of measuring the effect on the image of this filter (Wiener) were applied to all images [16].

In the second stage; it was made detection of ilium area by using Active Contour Model (ACM). According to the state of ilium area, acetabular roof and labrum areas have been segmented by using ACM method.

In the third stage; "Base Line", "Roof Line" and "Inclination Line" were determined that were necessary for implementation of Graf method. Respectively various morphological image processing algorithms were used on ilium area that obtained to be determined these lines (Thinning, Skeletonization, Pruning and Branchpoints).

In the fourth stage; alpha and beta angles were determined with the help of these lines. And in the last stage, Graf method classification was made by using alpha and beta angles, and the system performance was measured by comparing the results with the expert data.

### 3.1. Image Filtering

The presence of noise in ultrasound images adversely impact on degradation of the image quality and successful detection process [17]. To process US images is difficult and time consuming period. Therefore pre-processing filters must be applied to the images to facilitate image processing. Increasing of image quality by applying filters and segmentation process are made more effective. In our study, the filters that were known common and increasing the image quality, also reduce noise (Mean, Median, Gaussian, Wiener, Perona & Malik, Lee, and Frost). The most effective one (wiener) was applied to all images by measuring the effect on the image [16].

### 3.2. Active Contour Model

In recent years, ACM has been commonly used for medical image segmentation. ACM is known as basic idea of the overall development curve fitting method curves converge to object called [18-22]. It is selected a curve segments around the object and then according to effects of internal and external forces converge process is performed. When representation of the curve, ACM is divided two as open [20, 23] and close [19, 24, 25]. Snake model that made open demonstration of growing curve can be shown as an example for open ACM [20, 23]. Level sets

modal that change the curve as parametric with a certain distance function can be shown as an example for close ACM [21, 26, 27]. Generally, close ACM's can cope with topological deformation more than open ACM's.

Unlimited ACM presented by Chan and Vese is a successful segmentation study that were used in many studies on various subjects [19]. It is based on Curve distribution, Mumford-Shah method and level set techniques [27]. It is known as Chan-Vese (CV model) region-based segmentation algorithm. This method is less sensitive to noise than other contour method. This model includes a function similar to the values of our energy to other mini-contour model. While determining the interior lines, it moves without depending on initial value. This feature is separated from the snake model. Zero level set of the surface image is a moving curve and this curve detected the object. The changes such as splitting and merging can be detected automatically. According to this method, an image is divided into homogeneous regions using this level function. This region is composed of image parts containing closed area value [28]. C-V algorithm divided by C is off limits  $u_0$  official  $F(c_1, c_2, C)$  describes the energy function. This function is shown in Equation 1.

$$F(c_1, c_2, C) = \mu \cdot Length(C) + v \cdot Region(inner(C)) + \lambda_1 \int_{inner(C)} |u_0(x, y) - c_1|^2 dx dy + \lambda_2 \int_{outer(C)} |u_0(x, y) - c_2|^2 dx dy \quad (1)$$

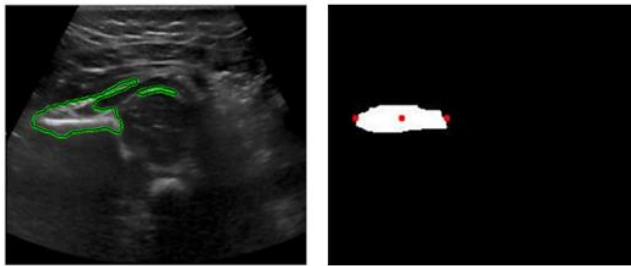
In equation 1,  $\mu \geq 0$ ,  $\lambda_1, \lambda_2 > 0$  are fixed parameters,  $c_1$  and  $c_2$  are changing parameters, also they are average value respectively remaining areas outside and inside of C contour. The first term is regularization term that prevents contour merging with a small area. The last two terms are fitting terms [29].

## 4. Implementation

A software that uses computer-aided Graf methods to put the diagnosis of DDH study was carried out on Matlab 8.3. Received by experts from US device 50 DDH image taken is processed by software designed and Graf method may be practiced alpha and beta angles were determined. Classifications in Graf method are carried out with these determined (alpha and beta) values. In the final stage, the outputs of software and the classifications which were applied by the radiologist were compared.

In the first stage of our study In the first phase of our work in order to facilitate the processing of US images; When the applied filter on the effect of quality improvement as measured DDH images; observer sensitivity, resulting image quality measurements and images made with segmentation of tests, wiener filter the ilium, acetabular segmentation of the roof and the labrum is determined to be more successful than other filter [16]. Consequently, all obtained images were passed through wiener filter in pre-process stage.


In the second stage wiener filter applied by applying the method improves the quality of images ACM estimated ilium region have been identified on the image. C-V ACM is used for segmentation of the ilium. As a result of estimated segmentation, the most-right and left areas were determined (Figure 5).



**Figure 5.** Segmentation process. a) The result of CV ACM process, b) R-E, L-E and C points.

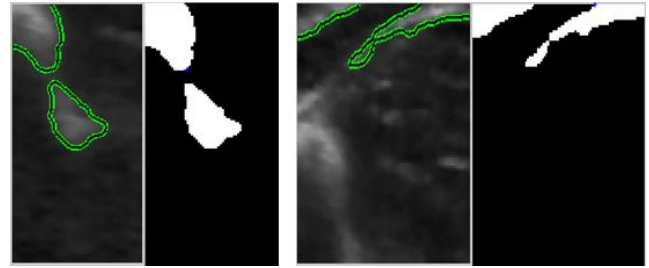
In the third step of our study, alpha and beta angles required to be applied Graf method provided to be determined used for DDH diagnosis. There must be a reference point drawn on ilium area and from base line to determine alpha and beta angles. The feature of this reference point in the negotiations with radiology specialists; the ilium area is divided. For the clarification of the estimated ilium identified in the previous section ACM method was once repeated between R-E, L-E and C.

Various morphological operations are applied to the resulting image in certain provinces. Thinning of the algorithm was first segment (thinning) has been converted into a pixel line subjected to the process (frame extraction). In this way, our image has taken a structure consisting of branches. After the thinning process is performed, the branch, and pruning was found that formation of unwanted images for the screening of the faulty branch (pruning) subjected to the process. Finding knot point to determine the latest stage in the branchpoint process is performed (Figure 6).



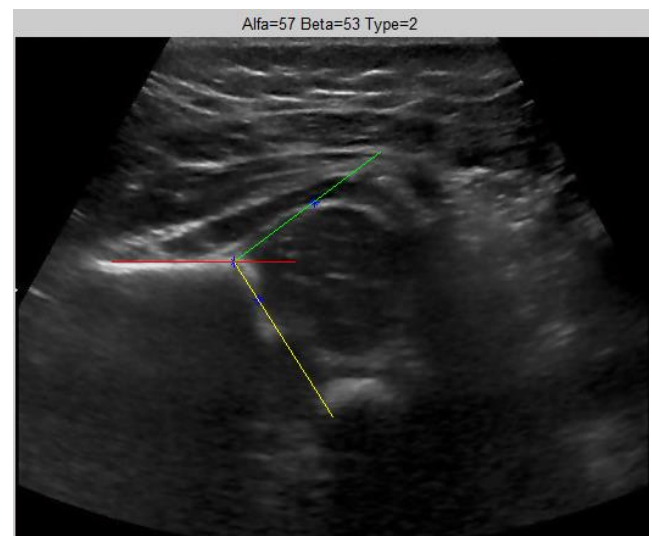
**Figure 6.** Morphological processing for detecting the reference point: a) Ilium identified in the region of estimated ilium, b) Segmentation results, c) thinning results, d) as a result of pruning, e) branch points process results.

After determining the correct reference point, there are two areas that need to be find. These are the acetabular roof and labrum. The line that was drawn between acetabular roof and reference point is "Roof Line" and is used to determine alpha angles. The line between labrum and reference point is "Inclination Line" and is used to determine beta angles. In the determination of these two areas, it was taken estimated areas and segmentation process was performed. It was benefited C-V ACM algorithm for this segmentation process (Figure 7).



**Figure 7.** Labrum and acetabular roof segmentation: a) segmentation results, b) determining the intersection point.

In the final stage of the study, reference, labrum and acetabular roof points were determined (Base Line, Roof Line, Inclination Line), and it was drawn lines between in these points, and beta and alpha angles were measured (Figure 8). The classification of Graf method was made in terms of these angles values.



**Figure 8.** Alpha and Beta angles with reference point.

## 5. Results

In the study, a computer-aided system was designed in order to make diagnosis of DDH. Through a pre-process stage, the acetabular roof and labrum areas were determined, alpha and beta angles were also determined, and the diagnosis was made utilizing the Graf method. In evaluation stage, Graf alpha and beta angles, from the designed software alpha and beta angles diagnosis were compared (Table 1). In Table 1, the computer results which don't match with expert evaluation is indicated as red. On the other hand, the missing result according to the beta angle is marked as green in Table 1.

**Table 1.** The comparison of expert assessment and the software results

Image Number	Expert Assessment				Computer Assessment			
	Alpha	Beta	Type I	Type II	Alpha	Beta	Type I	Type II
1	69	57	1	B	69	63	1	B
2	69	54	1	A	69	56	1	B
3	67	60	1	B	62	63	1	B
4	60	52	1	A	55	39	2	A
5	58	57	2	A	50	66	2	A
6	60	56	1	B	60	63	1	B
7	60	58	1	B	65	59	1	B
8	58	57	2	A	55	53	2	A
9	65	60	1	A	52	58	2	A

Image Number	Expert Assessment				Computer Assessment			
	Alpha	Beta	Type I	Type II	Alpha	Beta	Type I	Type II
10	69	60	1	B	60	62	1	B
11	62	57	1	B	72	64	1	B
12	60	50	1	A	52	59	2	A
13	59	58	2	A	59	52	2	A
14	56	56	2	A	52	51	2	A
15	59	57	2	A	52	53	2	A
16	60	50	1	A	46	72	2	A
17	60	58	1	B	60	73	1	B
18	59	57	2	A	56	59	2	A
19	63	52	1	A	49	38	2	A
20	59	56	2	A	50	53	2	A
21	60	58	1	B	48	59	2	A
22	60	57	1	B	60	69	1	B
23	58	60	2	A	52	65	2	A
24	55	58	2	A	48	54	2	A
25	57	56	2	A	47	54	2	A
26	64	55	1	A	64	55	1	A
27	60	52	1	A	56	41	2	A
28	59	55	2	A	55	53	2	A
29	60	59	1	B	62	76	1	B
30	66	57	1	B	63	60	1	B
31	60	57	1	B	55	67	2	A
32	58	59	2	A	57	45	2	A
33	56	56	2	A	56	40	2	A
34	65	59	1	B	57	48	2	A
35	58	57	2	A	55	67	2	A
36	60	57	1	B	62	74	1	B
37	60	59	1	B	66	65	1	B
38	69	59	1	B	73	72	1	B
39	61	58	1	B	63	67	1	B
40	60	56	1	B	61	56	1	B
41	59	56	2	A	59	78	2	A
42	60	53	1	A	65	55	1	B
43	60	58	1	B	62	66	1	B
44	60	59	1	B	67	69	1	B
45	60	51	1	A	66	49	1	A
46	60	52	1	A	51	47	2	A
47	58	56	2	A	59	77	2	A
48	59	58	2	A	59	60	2	A
49	60	57	1	B	61	81	1	B
50	65	58	1	B	78	58	1	B

Upon analyzing Table 1; when we look at only Type I, in 40 out of 50 images were matched with expert evaluation, on the other hand, in 38 out of 50 images were matched with expert evaluation by looking Type I and Type II together. As a result, the success rate is 80% based on only Type I, 76% based on Type I and Type II together.

## 6. Discussion

In the expert assessment of the results that calculated in the study; It was stated that the alpha value was near 60 degree had been an obstacle for the performance of the system. Because Type 1 Type 2 separation depends on keeping the value of alpha is 60 degrees or higher. For this reason experts; specifically stated that the results of the exit near the equivalent of close to 60 degrees of angle alpha. The shifting for 1-2 degrees completely change the diagnosis. These changes directly affect the performance of the system. For these reasons, with the recommendation of a system to alternative Graf method system success may increase. This system may be determined by Artificial Intelligence Applications used very often today.

## Acknowledgements

This study was carried out as doctorate thesis in Selçuk University-Department of Computer engineering.

## References

- [1] Doğruel, H., et al., Türkiye’de gelişimsel kalça displazisi sıklığının ve tarama programlarının değerlendirilmesi. Türkiye Klinikleri J Med Sci, 2008. 28: p. 357-360.
- [2] Tosun, H.B., Gelişimsel kalça displazisi taraması için yapılan kalça ultrasonografisi sonuçlarının değerlendirilmesi, in Tıp Fakültesi Ortopedi ve Travmatoloji Anabilim Dalı. 2010, Fırat Üniversitesi: Elazığ, Türkiye. p. 100.
- [3] Song, K. and A. Lapinsky, Determination of hip position in the Pavlik harness. Journal of Pediatric Orthopaedics, 2000. 20(3): p. 317-319.
- [4] Rosendahl, K., T. Markestad, and R. Lie, Ultrasound screening for developmental dysplasia of the hip in the neonate: the effect on treatment rate and prevalence of late cases. Pediatrics, 1994. 94(1): p. 47-52.
- [5] Herring, J.A., Tachdjian’s Pediatric Orthopaedics: From the Texas Scottish Rite Hospital for Children. Vol. 3. 2003, Philadelphia, U.S.A.: Elsevier-Saunders. 2144.
- [6] Tuncay, I.C., et al., Is prematurity important in ultrasonographic hip typing? Journal of Pediatric Orthopaedics B, 2005. 14: p. 168–171.
- [7] Harcke, H.T., Imaging methods used for children with hip dysplasia. Clin Orthop Relat Res., 2005. 434: p. 71-77.
- [8] Graf, R., Hip sonography: diagnosis and management of infant hip dysplasia. 2006: Springer Science & Business Media.
- [9] Şaşmaz, H.H., Gelişimsel kalça displazisi tanısında sonografik tarama tekniklerinin karşılaştırılması, in Tıp Fakültesi Radyoloji Anabilim Dalı. 2011, Gaziantep Üniversitesi: Gaziantep, Türkiye. p. 113.
- [10] Kapıcıoğlu, S., et al., 0-6 ay arası GKD ve PEV tanı ve tedavisi uygulamalı kursu kitapçığı. Vol. 4. 2006, Konya: TOTBİD.
- [11] Overhoff, H., et al., Computer-based determination of the newborn’s femoral head coverage using three-dimensional ultrasound scans, in Medical Image Computing and Computer-Assisted Intervention — MICCAI’98, W. Wells, A. Colchester, and S. Delp, Editors. 1998, Springer Berlin Heidelberg. p. 1024-1031.
- [12] Luis-García, R. and C. Alberola-López. Hip joint segmentation from 2D ultrasound data based on dynamic shape priors. in Proceedings of the 4th WSEAS international conference on Electronics, control and signal processing. 2005. World Scientific and Engineering Academy and Society (WSEAS).
- [13] Luis-García, R. and C. Alberola-Lopez. Parametric 3D hip joint segmentation for the diagnosis of developmental dysplasia. in Engineering in Medicine and Biology Society, 2006. EMBS '06. 28th Annual International Conference of the IEEE. 2006.
- [14] Luis-García, R., S. Aja-Fernandez, and R. Cardenas-Almeida, Analysis of ultrasound images based on local statistics. Application to the diagnosis of developmental dysplasia of the hip, in 2007 IEEE Ultrasonics Symposium. 2007. p. 2531-2534.
- [15] Chen, H.-Y., et al. Application of segmentation and

- measurement in the treatment of developmental dysplasia of the hip. in *Bioinformatics and Biomedical Engineering, 2007. ICBBE 2007. The 1st International Conference on. 2007.*
- [16] Çevik, K.K., H.E. Koçer, and Ş. Andaç, Segmentation of the Ilium and Femur Regions from Ultrasound Images for Diagnosis of Developmental Dysplasia of the Hip *J. Med. Imaging Health Inf.*, 2016. 6(2): p. 449-457.
- [17] Hafizah, W.M. and E. Supriyanto, Comparative evaluation of ultrasound kidney image enhancement techniques. *International Journal of Computer Applications*, 2011. 21(7): p. 15-19.
- [18] Chan, T.F., B.Y. Sandberg, and L.A. Vese, Active contours without edges for vector-valued images. *Journal of Visual Communication and Image Representation*, 2000. 11(2): p. 130-141.
- [19] Chan, T.F. and L.A. Vese, Active contours without edges. *Image Processing, IEEE Transactions on*, 2001. 10(2): p. 266-277.
- [20] Chenyang, X. and J.L. Prince, Snakes, shapes, and gradient vector flow. *Image Processing, IEEE Transactions on*, 1998. 7(3): p. 359-369.
- [21] Osher, S. and R. Fedkiw, *Level set methods and dynamic implicit surfaces*. Vol. 153. 2006, New York: Springer Science & Business Media. 280.
- [22] Sapiro, G., *Geometric partial differential equations and image analysis*. 2006, New York: Cambridge university press. 386.
- [23] Chesnaud, C., P. Réfrégier, and W. Boulet, Statistical region snake-based segmentation adapted to different physical noise models. *Pattern Analysis and Machine Intelligence, IEEE Transactions on*, 1999. 21(11): p. 1145-1157.
- [24] Chunming, L., et al. Level set evolution without re-initialization: a new variational formulation. in *Computer Vision and Pattern Recognition, 2005. CVPR 2005. IEEE Computer Society Conference on. 2005.*
- [25] Suri, J.S., et al., Shape recovery algorithms using level sets in 2-D/3-D medical imagery: a state-of-the-art review. *Information Technology in Biomedicine, IEEE Transactions on*, 2002. 6(1): p. 8-28.
- [26] Malladi, R., J. Sethian, and B.C. Vemuri, Shape modeling with front propagation: A level set approach. *Pattern Analysis and Machine Intelligence, IEEE Transactions on*, 1995. 17(2): p. 158-175.
- [27] Osher, S. and J.A. Sethian, Fronts propagating with curvature-dependent speed: Algorithms based on Hamilton-Jacobi formulations. *Journal of Computational Physics*, 1988. 79(1): p. 12-49.
- [28] Özmen, N., Image segmentation and smoothing via partial differential equations, in *The Graduate School Of Applied Mathematics. 2009, Middle East Technical University: Ankara. p. 102.*
- [29] Tunalı, I. and E. Kilic. Mass segmentation on mammograms using active contours. in *Signal Processing and Communications Applications Conference (SIU), 2013 21st. 2013.*