



CASE REPORT

Return to Job of A Construction Worker by Comprehensive Functional and Vocational Rehabilitation

Sandeep SHINDE^{1*} and Pradnya GHADAGE²

¹Krishna Institute Of Medical Sciences University Karād / INDIA

² Faculty of Physiotherapy, Krishna Institute of Medical Sciences (Deemed to be University), Karad, Maharashtra /INDIA

*Corresponding author: drsandeepshinde24@gmail.com

Abstract

Background: Employees in the construction industry perform a variety of tasks. In order to accomplish this work, individuals must repeatedly lift and carry objects overhead. To perform this work efficiently complete shoulder range of motion and strength of the rotator cuff muscles are important components. Here a patient with displaced two-part fracture of greater tuberosity and rotator cuff tear treated surgically has already reduced shoulder ROM and strength it is leading cause of absenteeism from work. This imposes a greater socioeconomic burden on patient. The purpose of this study was to improve range of motion and rotator cuff muscle strength as he has to resume his work as soon as possible. Case description: The patient was a 37 years old male, a construction worker by profession who sustained a shoulder injury as the result of fall. After the investigations, he was diagnosed with an isolated greater tuberosity fracture and rotator cuff tear. He was treated conservatively for 4 weeks, without success. Later, he was undergoing surgical treatment and referred for physiotherapy. Patient came with complaint of shoulder pain while performing shoulder movement and difficulty in initiating shoulder movement. Early Physiotherapy was given to reduce the pain, and improve strength of rotator cuff muscles and regain the range of motion and vocational rehabilitation.

Keywords

Overhead Activities, Rotator Cuff Tear, Muscular Imbalance, Gleno -Humeral Force Couple, Joint Stiffness.

INTRODUCTION

The occurrence of fracture of greater tuberosity either in the form of isolated fractures or in combination with anterior dislocation of glenohumeral joint. The mechanism of injury is commonly shows history of fall, direct blow to side of the shoulder results in comminuted fracture (Neer, 1970). This fracture subgroup according to Neer's classification system categories these fracture as one-, two-, three- or four-part fracture based on displacement and angulation of the parts which are head, shaft, greater tuberosity and lesser tuberosity (Bang and Deyle, 2000). Most common

displacements are superiorly and/or posteriorly displaced. The typical displacement is posterosuperior. 20% of all proximal humerus fractures are caused by isolated fractures of the greater tuberosity. Although radiographs are frequently used in the evaluation of shoulder discomfort following a fall, they might miss an isolated, nondisplaced fracture due to bone overlap or poor alignment. The advanced practise practitioner in these situations must take into account sophisticated imaging of the shoulder to check for a fracture or rotator cuff injury.

With immobilisation and early mobilisation, more than 95% of these fractures can be effectively treated nonoperatively without surgery.

Received: 21 April 2022 ; Accepted: 08 August 2022; Published: 20 December 2022

¹ORCID: 0000-0002-6466-3888, ²ORCID: 0000-0002-9992-0688

case of the Displaced two-part fractures of greater tuberosity which are managed with surgical intervention, scarcity of literature exists regarding functional recovery (Green and Izzi, 2003). Surgery is the preferred course of treatment for displaced greater tuberosity fractures, however this may limit shoulder function. Motion restriction and impairment are primarily brought on by rotator cuff muscle dysfunction and impingement brought on by superior or posterior displacement. The purpose of larger tuberosity open reduction and internal fixation is to avoid the greater tuberosity from impinging on the acromion in the near future and to maintain the rotator cuff's physiological functioning. (Goti and Shinde, 2020; La Briola and Mohagheh, 1975). According to previous research physiotherapy management after the surgical and conservative management of greater tuberosity fracture include joint range of motion exercise to elbow, wrist and fingers also mobilization to shoulder joint as pain permit. Some evidence suggests that friction massage and ultrasonic over the area of tendon helpful to treat the adhesion formation.

MATERIALS AND METHODS

Herein is a case, with associated imaging findings of a posteriorly displaced isolated greater tuberosity fracture of the right humerus.

History

37 years old male, a construction worker (daily wage labourer) with right-hand dominance presented to the orthopaedic clinic with a

complaint of shoulder pain and limited range of motion after sustaining a fall, reported as a slip and fall on a door. He explained that he accidentally struck his right shoulder on the door latch. He was conscious at that time and had immediate onset of shoulder pain, specifically to the proximal aspect of right humerus that resulted in the inability to raise his arm. So, he went to the orthopaedician where radiographs of right shoulder were taken and subsequently interpreted as a greater tuberosity fracture of the right humerus which was nondisplaced and there was no distal neurovascular deficit. Since it was nondisplaced fracture, he was treated conservatively for 3 weeks using sling and swath thereafter for follow-up, he again consulted an orthopaedician where radiographs were taken and doctor recommended him to continue wearing the sling for another week. After four weeks of conservative management sling and swath was removed. Despite removal of sling after 2 weeks the patient reported continuing lateral shoulder pain and weakness in right hand. Pain was mild and dull aching at rest. Symptoms aggravated with attempted movements of shoulder and difficulty in initiation of the activities with the right shoulder. This pain was described as sharp and focal to lateral shoulder. Patients consulted orthopaedician after the investigations were done, they found the displaced fracture fragment posteriorly (fig no 1,2). As per the advice he underwent for surgical intervention were with open reduction and internal fixation (fig no 3) and immobilized for 2 months.

Table 1. His examination revealed there was pain in right shoulder which was assessed by NPRS

	At rest	On activity Post Treatment
Pre Treatment	2/10	6/10
Post Treatment	0/10	0/10

Table 2. Range of motion – right shoulder

	Pre Treatment	Post Treatment
Right shoulder	Active ROM	Active ROM
Flexion	0-15 ⁰	0-170 ⁰
Extension	0-10 ⁰	0-30 ⁰
Abduction	0-15 ⁰	0-160 ⁰
Internal rotation	0-15 ⁰	0-60 ⁰
External rotation	0 ⁰	0-50 ⁰

Table 3. Manual muscle testing (Conroy And Hayes, 1998)

	Pre Treatment	Post Treatment
Right Shoulder	Grade	Grade
Shoulder flexor	I	V
Shoulder extensor	I	V
Shoulder abductor	I	V

Table 4. Physiotherapy intervention (Kim and Ha, 2000; Dvir, 1997; Shah and Shinde, 2018).

Early stage - week 1-4	
	Patient education Hot moist pack Gentle Maitland grade – I II Active assisted exercise within pain free range Isometric exercise, Desensitization program Wand exercise (fig no 8) Home exercise programme
Intermediate stage – week 5-8	
	Hot moist pack Maitland grade- III IV, Movement with Mobilization (MWM) Active exercise in side lying (gravity elimination) shoulder flexion and external rotation (fig no 5,6) Multiple angle isometrics – 5 sec holds at 30, 60, 120 degrees Shoulder range of motion exercises in scaption Grip strengthening exercise Home exercise program
Late stage – 8- 12 weeks	
	Above all intervention Scapular stabilization exercise – prone T Rowing Active assisted resisted exercise to shoulder flexors and abductors Strengthening of scapular stabilizers Grip strengthening exercises Endurance exercise for shoulder using low load with maximum repetition Home exercise program
Vocational rehabilitation – 12- 20 weeks (Goti and Shinde,2020)	
Work specific activities	
	1. Overhead activities of shoulder 2. Manual handling of load 3. Static posture 4. Repetitive work

The Borg General Scale was utilised to keep track of training intensity. Before beginning the job, the patient was given a brief explanation

of the scale. He was asked to rate the training session using the scale when it was over.

RESULTS

There was grade 1 tenderness overlying the greater tuberosity. Range of motion of elbow and wrist were complete. Grip strength was slightly reduced. He was screened for the functional assessment according to ICIDH2 with these findings there was significant impact on his activity limitation (E.g., right shoulder overhead

activities, lifting loads and moving one place to another), participation limitations (limitations at work place), participation restriction it is leading cause of absenteeism from work. This imposes a greater socioeconomic burden on patient. Based upon these findings’ physiotherapy management was started on 7th September 2021 which was continued for 12 weeks.

This pain was described as sharp and focal to lateral shoulder. Patients consulted orthopaedician after the investigations were done, they found the displaced fracture fragment posteriorly (fig no 1,2). As per the advice he underwent for surgical intervention were with open reduction and internal fixation (fig no 3) and immobilized for 2 months.

By 24 weeks post-surgery the patient demonstrated functional range of motion of right

shoulder i.e., 160° of shoulder abduction (fig no 9), 170° of shoulder flexion (fig no 10) extension 30° , internal rotation 60° , external rotation 50° . Strength (4/5) of his rotator cuff muscles. He was relatively pain free. Now, he can successfully perform overhead activities with necessary strength. In addition to meeting the criteria for returning to work.

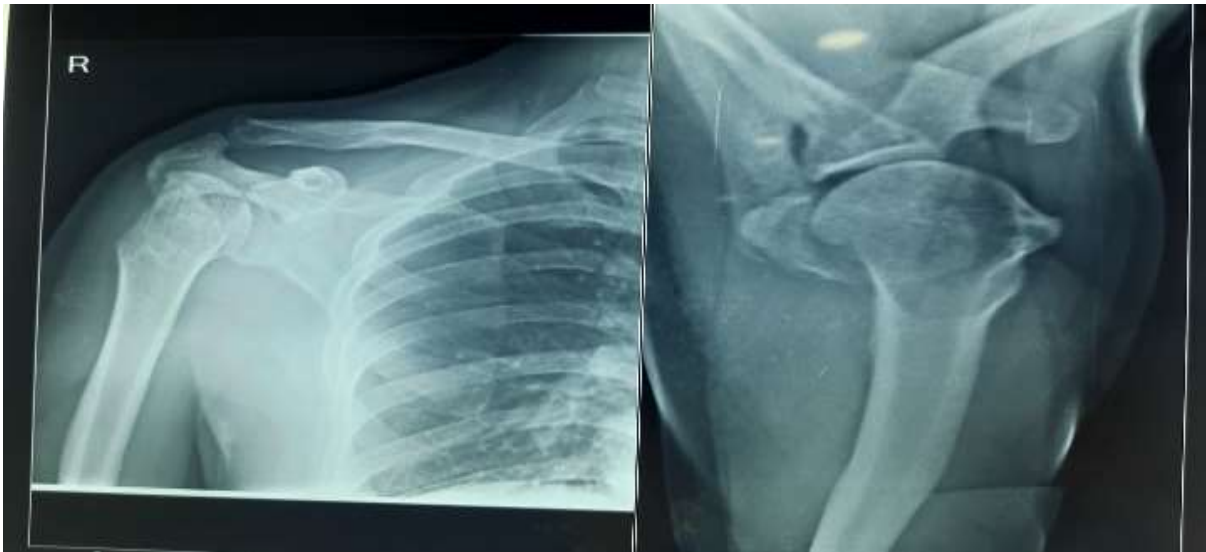

Figure 1,2. Plane radiographs findings revealed a displaced fracture of the greater tuberosity.

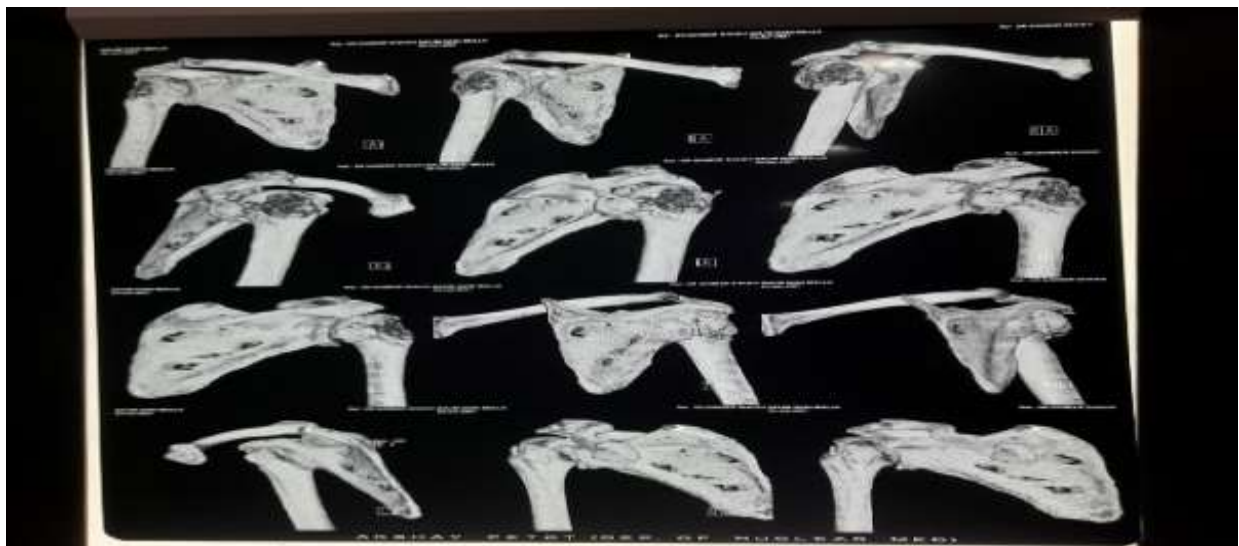


Figure 3. 3D CT findings – greater tuberosity fracture and displaced posteriorly

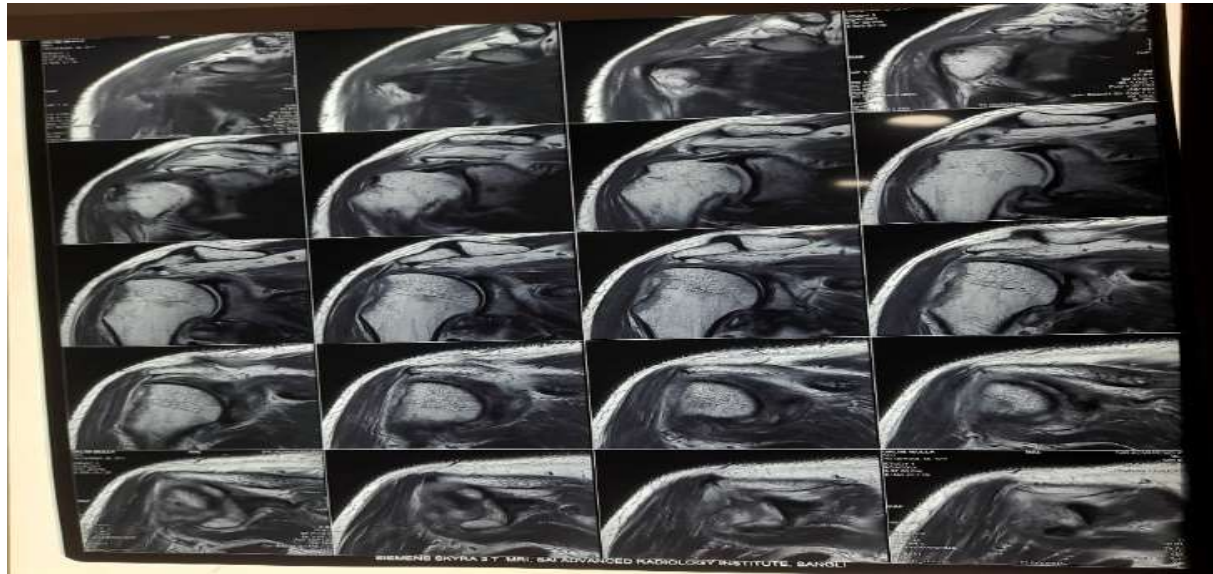


Figure 4. MRI findings of right shoulder revealed that displaced fracture of greater tuberosity.

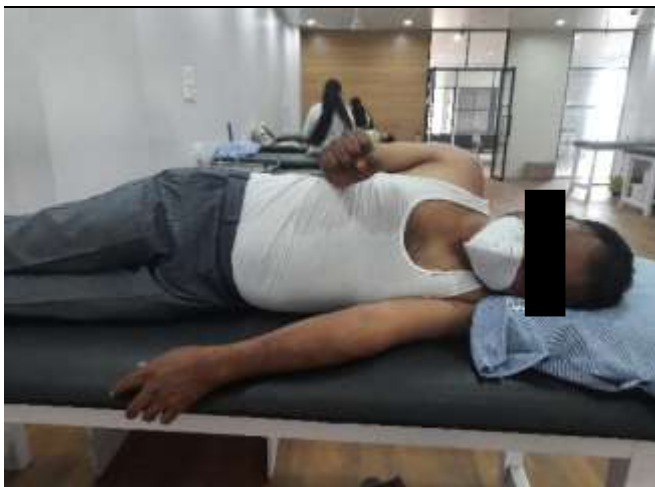

Figure 5

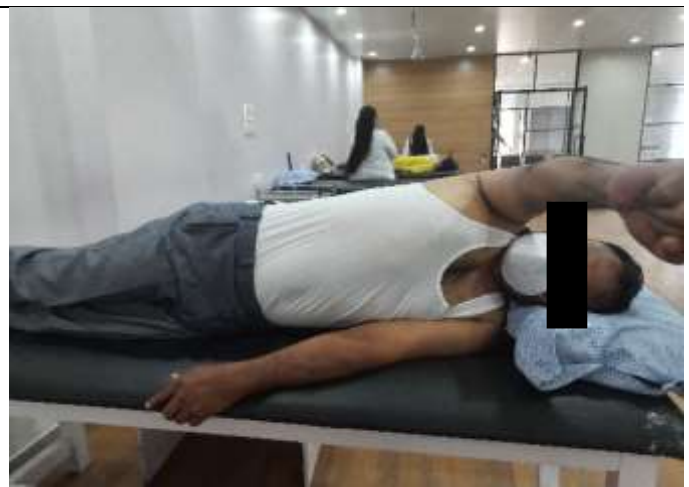

Figure 6



Figure 7



Figure 8

Figure 5,6. Active exercise in side lying (gravity elimination) shoulder flexion and external rotation
Figure 7,8. Home exercise program



Figure 9. Shoulder abduction

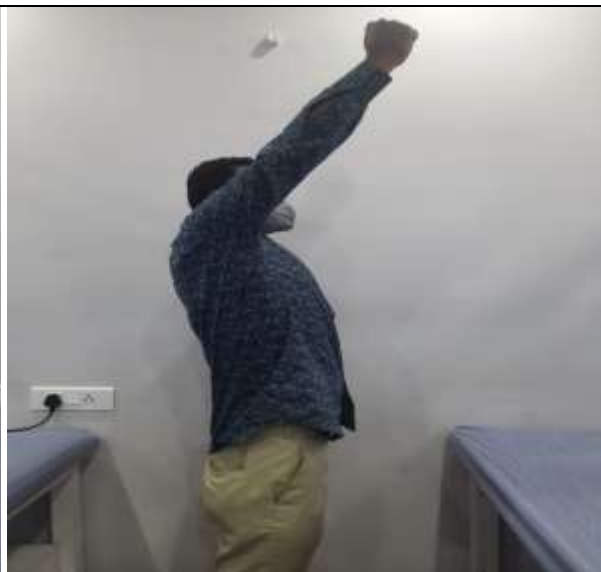

Figure 10. Shoulder flexion



Figure 11. Overhead activities using weight

DISCUSSION

A worker's readiness to work with work-related musculoskeletal disorders can be conceptualized as a complex behavioural change, including physical recovery, motivation, behaviour and being affected by a variety of medical factors, professional and personal as well as insurance systems. It is even more of a financial problem for the worker who is on long-term sick leave. There is evidence to suggest that to facilitate the return-to-work process, clinical interventions need to be

linked to the workplace (Kim and Ha, 2000). Vocational rehabilitation program appeared to be more effective in facilitating the return-to-work process of the injured worker as assessed immediately following intervention. The results of our study revealed good functional outcome after physiotherapy intervention.

Generally, fractures of the greater tuberosity requiring surgical intervention are rare is depends upon the amount of displacement of fracture fragment and account for less than 2% of operatively treated proximal humeral fractures (Kim and Ha, 2000; Goti and Shinde, 2020). Only a few number of authors have up to this point provided follow-up information on the surgical treatment of displaced greater tuberosity fractures. At an average of 4.5 years following open reduction and internal fixation, Flotow et al. evaluated 12 patients. They reported on six good and six excellent functional outcomes within 6-8 weeks (La Briola and Mohaghegh, 19975). Radiographs may not reveal a larger tuberosity fracture if it is not displaced, as was the case with this patient. The correct identification of the displaced fracture made possible by the use of cutting-edge imaging techniques like PET CT and MRI let the orthopaedic surgeon design a surgical intervention that would allow for proper healing. The presence of soreness and pain on the lateral wall of the greater tuberosity and limited range of motion in the afflicted shoulder is the only non-imaging examination that has been documented as clinically helpful in diagnosing an isolated

nondisplaced greater tuberosity fracture (Jaju and Shinde, 2019). One could say that greater tuberosity tenderness could also be the result of inflammation of the supraspinatus and infraspinatus tendon at its attachment, either from overuse or as the result of a tear.

The presence of adhesive capsulitis, an anterior labral tear, glenohumeral arthritis, as well as the presence of a tumour may also cause tenderness in this region. Post-operative management for this patient, focusing on arthroscopic surgery for reduction of displaced fracture fragment, rest, maintenance of ROM, symptom-driven progression of rotator cuff strengthening, and a restoration of shoulder function, resulted in a good initial outcome. The patient had functional range of motion, no pain while at rest, and was able to perform all of his normal activities without incident. This programme demonstrated a considerable weakness in the strength of external rotation and abduction. Hence, strengthening exercises are important in improving the functions (Zanetti et al., 1999; Flatow et al., 1991).

The adoption of suitable treatment methods, communication with the referring surgeon's staff, and prompt and effective treatment plans contributed to a positive overall outcome. Workplace based rehabilitation program was done during the 12 to 16 weeks. After 16 weeks, the rehabilitation program was continued with a home exercise program 3-4 times/ week. He returned for reassessment after 24 weeks postoperatively. His range of motion was near normal and overhead movements were relatively pain free, also he had gained strength and he had started his work. Now he is fulfilling the criteria for doing his work at construction site successfully requiring repeated lifting heavy weight.

Conclusion

In this case report of a 37 years male, Construction worker with a displaced right greater tuberosity fracture and rotator cuff complete tear. Postoperatively the comprehensive rehabilitation program consisted of a functional and vocational physiotherapy rehabilitation that decreased its post-operative complications, improved shoulder mobility and strength. All these effects enhanced patients overall shoulder function. He was able to resume his routine pre-operative activities at construction work place successfully.

Conflict of interests

The authors have no conflict of interests to declare. No financial support was received for this study

Ethical Consideration

The study protocol was carried out in accordance with the Helsinki Declaration of 1975 and Written informed consent forms were obtained from all participants prior to the study.

Author Contributions

Sandeep Shinde and Pradnya Ghadage conducted literature review for this manuscript, developed introduction section of the manuscript together with the discussion of the study findings, collected data, and analyzed the data. All the authors read and approved the final manuscript.

REFERENCES

- Bang, M.D., Deyle, G.D. (2000). Comparison of supervised exercise with and without manual physical therapy for patients with shoulder impingement syndrome. *J Orthop Sports Phys Ther*;30:126-137.
- Conroy, D.E., Hayes, K.W. (1998). The effect of joint mobilization as a component of comprehensive treatment for primary shoulder impingement syndrome. *J Orthop Sports Phys Ther*.;28:3-14.
- Davies GJ, Gould JA, Larson RL. Functional examination of the shoulder girdle. *Phys Sportsmed*. 1981;9:82-104.
- Determe D, Rongieres M, Kany J, et al. Anatomic study of the tendinous rotator cuff of the shoulder. *Surg Radiol Anat*. 1996;18:195-200.
- Dvir, Z. (1997). Grade 4 in manual muscle testing: the problem with submaximal strength assessment. *Clin Rehabil*;11:36-41.
- Flatow, E.L, Cuomo, F., Maday, M.G., Miller S.R., McIlveen, S.J., Bigliani, L.U. (1991). Open reduction and internal fixation of two part fractures of the greater tuberosity of the proximal part of the humerus. *J Bone Joint Surg (Am)*; 73:1213-1218.
- Green, A., Izzi, J. (2003). Isolated fractures of the greater tuberosity of the proximal humerus. *J Shoulder Elbow Surg*;12:641-649.
- Goti, T.S., Shinde, S.B. (2020). (Effect of scapular position-motion maintenance exercise programme during post traumatic shoulder immobilization. *Indian Journal of Public*

- Health Research & Development*; Jan 1;11(1):702-8.
- Kim, S., Ha, K. (2000). Arthroscopic treatment of symptomatic shoulders with minimally displaced greater tuberosity fractures. *Arthroscopy*; 16:695–700.
- Kei Cheng, A.S., Kim Hung, L. (2007). Randomized Controlled Trial of Workplace-based Rehabilitation for Work-related Rotator Cuff Disorder: *J Occup Rehabil*; 17:487–503.
- La Briola, J.H., Mohaghegh, H.A. (1975). Isolated avulsion fracture of the lesser tuberosity of the humerus. A case report and review of the literature. *J Bone Joint Surg Am*;57:1011.
- Jaju, C.S., Shinde, S. (2019). Prevalence of peripheral neuropathy in chronic musculoskeletal oedematous conditions. *Int J Physiother*; 6(6): 282-286.
- Neer, C.S. (1970). 2nd. Displaced proximal humeral fractures. Part I. Classification and evaluation. *J Bone Joint Surg (Am)*; 52:1077–1089.
- Shah, P.S., Shinde, S.B. (2018). Effect of desensitization methods during the early mobilization phase in post-fracture conditions of upper extremity. *Asian journal of pharmaceutical and clinical research*; Jul 7:93-6.
- Zanetti, M., Weishaupt, D., Jost, B., Gerber, C., Hodler, J. (1999). MR imaging for traumatic tears of the rotator cuff: high prevalence of greater tuberosity fractures and subscapularis tendon tears. *AJR Am J Roentgenol*;172:463-467.

How to cite this article: Shinde, S. and Ghadage, P. (2022). Return to Job of A Construction Worker by Comprehensive Functional and Vocational Rehabilitation. *Int J Disabil Sports Health Sci*;5(2):97-104. <https://doi.org/10.33438/ijdshs.1106819>

