

INVESTIGATION OF THE EFFECT OF CHLOROQUINE ON ADRIAMYCIN-INDUCED KIDNEY DAMAGE

Emin KAYMAK¹, Ali Tuğrul AKIN², Tayfun CEYLAN³, Derya
KARABULUT³

¹Bozok University, Department of Histology-Embryology, Yozgat, Turkey.

²Biology Department, Faculty of Science, Erciyes University, Kayseri, Turkey

³Histology-Embryology Department, Faculty of Medicine, Erciyes University, Kayseri,

Abstract

Although Adriamycin (ADR) is an important anticancer drug used in chemotherapy, it causes nephrotoxicity. The inflammation pathway has an important role in ADR-induced nephrotoxicity. Chloroquine (CLQ), which is used as an antimalarial drug, is used in many diseases. Also, CLQ is known as an anti-inflammatory. In this study, we aimed to investigate the effect of CLQ against nephrotoxicity caused by ADR through the inflammatory pathway. Groups were formed as follows; Control (n = 8), CLQ (n = 8) 50 mg / kg intraperitoneally (i.p.) per day, ADR (n = 8) 2 mg / kg i.p. every 3 days, ADR + CLQ (n = 8) 2mg / kg / i.p. ADR + 50 mg / kg / i.p. CLQ. The experiment took a total of 30 days. At the end of the experiment, kidney tissues were taken from the rats under anesthesia. After fixation in the removed kidney tissues, the tissues were embedded in paraffin by histological methods. Sections were taken from kidney tissues. Renal tissue histopathology and Tumor necrosis factor-alpha (TNF- α) and Nuclear factor- κ B p65 (NF- κ B p65) immunoreactivities were evaluated. When the kidney tissue was examined, it was seen that damage was caused by ADR. In addition, it was observed that TNF- α and NF- κ B p65 immunoreactivities in the kidney significantly increased in the ADR group ($p < 0.05$). Damage and inflammatory markers were found to be decreased in the ADR + CLQ group ($p < 0.05$). Chemotherapeutically administered ADR appears to cause nephrotoxicity. CLQ administered was found to reduce this toxicity. As a result, we showed that the damage caused by ADR-induced nephrotoxicity decreased with the application of CLQ through the TNF- α and NF- κ B p65 inflammation pathway.

Keywords: Adriamycin, Chloroquine, Inflammation, Kidney

*Corresponding author: Emin KAYMAK. Tel: +90 554 861 00 47.e-mail:
e_kaymak@hotmail.com. Orcid ID: 0000-0002-3818-2693

Introduction

Chronic kidney disease is known as an important health problem in the world. Kidney disease is usually associated with loss of kidney function (1). Among the various factors that contribute to kidney disease, many factors such as inflammatory processes and oxidative stress play a role (2). ADR, also known as doxorubicin, is an important anthracycline antibiotic and is used in cancer treatment. In addition, the use of ADR causes toxicity in the heart and kidney (3, 4). ADR ensures the removal of histone proteins from the chromatin and prevents DNA replication by inhibiting the topoisomerase II enzyme (5). This cytotoxicity of ADR occurs due to ADR-induced toxicity, free radical formation, and oxidative stress (6). Kidney damage caused by ADR includes events such as free radical formation, oxidative damage and inflammation, which leads to tissue damage (7). After ADR is taken into the cell, it causes cell damage and apoptosis due to the breaking of the DNA chain, inhibition of macromolecule biosynthesis, and formation of hydroxyl radicals. ADR enables the generation of reactive oxygen species (ROS) (8). Depending on the increase in oxidative damage, a significant degree of ADR-induced nephrotoxicity is seen in inflammation, and the increased

inflammation may lead to fibrosis in the kidney (9, 10).

TNF- α is a cytotoxic factor, plays a key role in the pathogenesis of fibrosis, is involved in many inflammatory responses that can induce the release of many cytokines, and act as a chemotactic molecule to take up neutrophils and monocytes (11). TNF- α triggers the activation of I κ B kinase (IKK) / NF- κ B and mitogen-activated protein kinase (MAPK) / AP-1 pathways, which are necessary for the expression of proinflammatory cytokines and induction of many biological substances (12). NF- κ B is known as the transcription factor widely expressed in various cells and tissues and can respond rapidly to various inflammatory stimuli (13). One of the subunits of NF κ B is p65 (14). Activated NF- κ B (ie free NF- κ B p50 / p65) leads to the release of pro-inflammatory cytokines such as TNF- α (15).

Expression of NF- κ B / TNF- α is found in almost all mammalian cells, and this is activated by a number of stimuli. The NF- κ B / TNF- α pathway plays an important role in the normal physiological regulatory network of immune and inflammatory responses (16, 17).

Antimalarial drugs (eg Chloroquine) have been developed primarily to treat malaria; However, they are beneficial in many

dermatological, immunological, rheumatological, and severe infectious

The effect of CLQ on the NF- κ B p65 / TNF- α pathway, which plays an important role in inflammation in ADR-induced kidney damage, is unknown. In light of all the above-mentioned information, we aimed to determine the effects of CLQ on NF- κ B p65/ TNF- α in ADR-induced kidney damage.

Materials and methods

In this study, 8-week-old 150-200 gr adult male 32 Wistar albino type rats produced in Erciyes University Hakan Çetinsaya Experimental Research Application and Research Center (DEKAM) were used. The rats kept in the cages were kept at 21 ° C and 12 hours in a light / dark environment in the normal order of the day and their water and nutrient needs were met. Experimental groups were formed by weighing the subjects and bringing them together so that their weights were close to each other.

Experimental procedure

Rats were divided into four groups as follows;

1. Control group (n = 8) untreated rats,
2. CLQ (Chloroquine (N4 -(7-Chloro-4-quinolinyl)-N1 ,N1 -dimethyl,1,4-pentanediamine diphosphate salt) Sigma

diseases and are known as an anti-inflammatory (18).

Aldrich C6628) group (n = 8) group for 30 days intraperitoneally (i.p.) 50 mg / kg CLQ (CLQ was dissolved in saline)(19),

3. ADR group (Koçak Farma) (n=8) 2 mg / kg ADR intraperitoneally (i.p.) every three days for 30 days (20),

4. ADR + CLQ group (n = 8) every three days i.p. 2 mg / kg ADR and for 30 days 50 mg / kg/i.p. of CLQ was administered.

At the end of the study rats were decapitated after intraperitoneal ketamine (Pfizer) (75mg/kg)+xylazine (Rompun, Bayer) (10mg/kg). After the kidney tissues were taken from the rats, they were put in formaldehyde for histopathological and immunohistochemical examination.

Histopathological evaluation

Histopathological evaluation of the kidney tissue was made using routine histological methods. Kidney tissues were fixed in 10% formalin solution for 24-48 hours, dehydrated with alcohol, purged with xylene, and embedded in paraffin and cut into 5 μ m thick sections. Hematoxylin-eosin (H&E) staining was performed to evaluate histopathological changes in tissue samples (21). Photos were taken under a light microscope (Olympus BX53;

Olympus, Tokyo, Japan) and analyzed by the study group.

Immunohistochemistry

The immunohistochemistry method was used to determine the immunoreactivity of TNF- α and NF- κ B p65 antibodies in kidney tissues. Avidin biotin peroxidase method was used to determine the difference in TNF- α (bs-2081R, Bioss) and NF- κ B p65 (bs-0465R, Bioss) expression. Paraffin sections were deparaffinized with xylene. For antigen recovery, 0.01M 10% citrate buffer was applied at 600w for 7 minutes in the microwave and then allowed to cool for 10 minutes at room temperature. Parts washed with phosphate buffer (PBS) were treated with 3% hydrogen peroxide (H₂O₂) for 12 minutes to prevent endogenous peroxidase activity. It was washed 3 times with PBS again for 5 minutes. The staining kit (TA-125-HDX, Thermo Fisher Scientific, Waltham, MA, USA) was used for the next steps. After washing again 3 times in PBS, the ultra v block solution was added to the tissues and kept in the tank for 10 minutes. TNF- α and NF- κ B p65 antibodies were then added to the tissues

and incubated at 4 ° C overnight. After rewashing, the peroxidase present in the kit and displaying diaminobenzidine (DAB) (TA-060-HDX, Thermo Fisher Scientific, Waltham, MA, USA) was treated with the peroxidase substrate for 1.5 minutes to make its immunoreactivity visible (21). Photos were taken under a light microscope (Olympus BX53; Olympus, Tokyo, Japan) and analyzed by the study group. To evaluate antibody expressions, each group was scored in 30 different areas by 3 histologists according to the staining intensity. These scores are summarized as follows;

0: no staining, 1: little staining, 2: moderate staining, 3: intense staining.

Statistical analysis

Kolmogorov - Smirnov test was used to determine the normal distribution of the data. One-way analysis of variance and posthoc Tukey test were used to determine differences between groups. Results are presented as mean \pm Standard deviation (SD). Graph pad Prism 8.0 software was used for statistical analysis. P <0.05. It was considered statistically significant.

Results

Histopathology results

The image of Hematoxylin & eosin in kidney tissue is given in figure 1. Healthy

kidney tissue is seen in the control group. When looking at the ADR group, tubular damage, glomerular degeneration, and hemorrhagic areas are seen. When we looked at the ADR + CLQ group, it was seen that these damages did not exist.

Immunohistochemistry results

TNF- α and NF- κ B p65 immunoreactivity results and immunohistochemistry staining images are shown in Table 1 and Figure 2. TNF- α and NF- κ B p65 immunoreactivity increased significantly in the ADR group compared to the control group ($p < 0.05$). A statistically significant decrease in TNF- α and NF- κ B p65 immunoreactivity was observed in the ADR + CLQ group compared to the ADR group ($p < 0.05$).

Discussion

ADR is a promising drug for cancer patients, which is used in many cancer treatments. However, side effects are seen in patients. One of these side effects is nephrotoxicity. ADR is a chemotherapeutic that causes kidney damage in particular. ADR shows its harmful effects on cells by inhibiting transcription and replication (22). ADR-induced nephrotoxicity is one of the best-known models of chemotherapy-induced kidney injury. ADR causes

functional and morphological changes in the kidney (9). CLQ, which is used in malaria and pulmonary hypertension, is also known as an autophagy inhibitor (23). Autophagy plays a role in the pathophysiology of many diseases. CLQ, an important autophagy inhibitor, and its derivative, hydroxychloroquine, are important drugs (24). CLQ was originally used and discovered in the treatment of inflammatory diseases. CLQ is known to have anti-inflammatory properties (18). Recently, it has also been used as an anti-inflammatory in the treatment of COVID-19 (25). In the present study, we also induced nephrotoxicity with ADR. In the present study, ADR was applied chronically. We have shown that there is an effect between the kidney damage that occurs and the increased inflammation. When the effect of ADR, which we applied chronically, was examined at the end of the experiment, we observed that similar to other studies, it had negative effects such as tubular epithelial shedding, glomerular damage, and hemorrhage in the kidney (26). We observed that these apparent damages decreased in the ADR + CLQ group. Oxidative stress and inflammation play an important role in the formation of these damages (9).

The inflammatory response has a complex mechanism. The exact mechanisms underlying the effect of ADR on inflammation are unclear. Studies have shown that there may be an interaction between inflammation and nuclear factor kappa B (NF- κ B) (27). It has been proven that NF- κ B, an important transcriptional activator, regulates the expression of inflammatory factors (28). As a result of increased phosphorylation of NF- κ B, it has been stated that the inflammatory response is significantly increased (29). TNF- α is known as a proinflammatory cytokine. It is produced by many cells in the kidney as a result of ADR application (30). TNF cytokine family members are the best inducers of NF- κ B. Cytokines belonging to the TNF family primarily stimulate genes that regulate inflammation through the NF- κ B pathway. It contains a transactivation site to initiate p65 transcription from NF- κ B proteins (16). Two pathways are involved in the stimulation of NF- κ B, the canonical and noncanonical pathways. The most important target of these is canonical p65 (31). NF- κ B is stimulated by cytokines such as TNF- α (32). ADR administration promotes inflammation and increases the level of NF- κ B p65. Reactive oxygen species increase in the body with the application of ADR. This leads to oxidative stress and leads to cell damage (33). In the present study, NF- κ B p65 and TNF- α

immunoreactivity increased significantly with the application of ADR. Activation of this pathway also increases TNF- α expression. In previous studies, it has been reported that ADR increases NF- κ B p65 and TNF- α expressions in the kidney (34-36). In another study, it was reported that inflammation increased due to the increase of oxidative stress by ADR and accordingly, proinflammatory cytokines increased (10). In our study, an increase in NF- κ B p65 and TNF- α immunoreactivity was observed. In the ADR + CLQ group, it is seen that inflammatory cytokines are decreased. Some studies say that with the activation of autophagy, kidney damage is reduced (37). There are also studies showing that increased autophagy will cause kidney damage (38). In another study, it was found that CLQ application increased lipid peroxidation in kidney tissue and damage occurred in tubules. They think this is due to the long-term use of CLQ (23, 39). They showed that the autophagy activator has a destructive role in kidney stone formation, while the autophagy inhibitor CLQ inhibits the adhesion of crystals to kidney epithelial cells. They also showed that CLQ attenuated renal cell damage and oxidative damage (40). The autophagy inhibitor CLQ used in the current study appears to reduce this damage through inflammation.

Limitation of this study; Since the study was not conducted with financial support, many more parameters could not be looked at. Therefore, it is important in that it provides the basis for future studies. In new large-scale studies, it will shed light on both histological and biochemical parameters.

Conclusion

The results of the present study indicate that ADR-induced nephrotoxicity occurs. As a result of this nephrotoxicity, damage occurs in the kidney tissue. The importance of the NF- κ B p65 / TNF- α pathway is remarkable in our study, which shows that especially inflammation plays an important role in the injury. In addition, we see that CLQ, which we use as an anti-inflammatory, reduces inflammation and associated kidney damage. It has been shown that CLQ affects this effect through the NF- κ B p65 / TNF- α pathway and inhibits this pathway. With the studies to be conducted, demonstrating the importance of the inflammatory pathway in reducing the side effects of different chemotherapeutic agents used in cancer treatment and determining anti-inflammatory agents against them will play an important role in reducing these damages. It will also play an important role in determining this controversial and research-open feature of CLQ.

Acknowledgements

Ethical approval: The approval of Erciyes University Experimental Animals Ethics Committee (Decision number: 19/205 and Date: 06.11.2019) was obtained.

Conflict of interest: There is no conflict of interest between the authors.

Financial support: No financial support received.

Peer-review: Externally and internally peerreviewed.

Author Contributions

ATA and EK designed the study, and EK, ATA, TC and DK performed the experiment. EK and ATA contributed in analyzing the data. EK wrote the manuscript.

References

1. Wei MG, He WM, Lu X, et al. JiaWeiDangGui Decoction Ameliorates Proteinuria and Kidney Injury in Adriamycin-Induced Rat by Blockade of TGF- β /Smad Signaling. Evidence-based complementary and alternative medicine : eCAM. 2016;2016:5031890.
2. Rybi-Szumińska A, Wasilewska A, Michaluk-Skutnik J, et al. Are oxidized low-density lipoprotein and C-reactive protein markers of atherosclerosis in nephrotic children? Irish journal of medical science. 2015;184(4):775-80.
3. Pillai VB, Kanwal A, Fang YH, et al. Honokiol, an activator of Sirtuin-3 (SIRT3) preserves mitochondria and protects the heart from doxorubicin-induced cardiomyopathy in mice. Oncotarget. 2017;8(21):34082-98.
4. Liang CL, Zhang PC, Wu JB, et al. Zhen-wu-tang attenuates Adriamycin-induced nephropathy via regulating AQP2 and miR-92b.

- Biomedicine & pharmacotherapy = Biomedecine & pharmacotherapie. 2019;109:1296-305.
5. Yokochi T, Robertson KD. Doxorubicin inhibits DNMT1, resulting in conditional apoptosis. *Molecular pharmacology*. 2004;66(6):1415-20.
 6. Liu LL, Li QX, Xia L, et al. Differential effects of dihydropyridine calcium antagonists on doxorubicin-induced nephrotoxicity in rats. *Toxicology*. 2007;231(1):81-90.
 7. Zordoky BN, Anwar-Mohamed A, Aboutabl ME, et al. Acute doxorubicin toxicity differentially alters cytochrome P450 expression and arachidonic acid metabolism in rat kidney and liver. *Drug metabolism and disposition: the biological fate of chemicals*. 2011;39(8):1440-50.
 8. Rivankar S. An overview of doxorubicin formulations in cancer therapy. *Journal of cancer research and therapeutics*. 2014;10(4):853-8.
 9. Szalay CI, Erdélyi K, Kőkény G, et al. Oxidative/Nitrative Stress and Inflammation Drive Progression of Doxorubicin-Induced Renal Fibrosis in Rats as Revealed by Comparing a Normal and a Fibrosis-Resistant Rat Strain. *PloS one*. 2015;10(6):e0127090.
 10. Zhu MM, Wang L, Yang D, et al. Wedelolactone alleviates doxorubicin-induced inflammation and oxidative stress damage of podocytes by IκK/IκB/NF-κB pathway. *Biomedicine & pharmacotherapy = Biomedecine & pharmacotherapie*. 2019;117:109088.
 11. Sahraoui A, Dewachter C, de Medina G, et al. Myocardial Structural and Biological Anomalies Induced by High Fat Diet in *Psammomys obesus* Gerbils. *PloS one*. 2016;11(2):e0148117.
 12. Baud V, Karin M. Signal transduction by tumor necrosis factor and its relatives. *Trends in cell biology*. 2001;11(9):372-7.
 13. Rahman I, Marwick J, Kirkham P. Redox modulation of chromatin remodeling: impact on histone acetylation and deacetylation, NF-kappaB and pro-inflammatory gene expression. *Biochemical pharmacology*. 2004;68(6):1255-67.
 14. Ghosh S, Karin M. Missing pieces in the NF-kappaB puzzle. *Cell*. 2002;109 Suppl:S81-96.
 15. Borgohain MP, Lahkar M, Ahmed S, et al. Small Molecule Inhibiting Nuclear Factor-kB Ameliorates Oxidative Stress and Suppresses Renal Inflammation in Early Stage of Alloxan-Induced Diabetic Nephropathy in Rat. *Basic & clinical pharmacology & toxicology*. 2017;120(5):442-9.
 16. Hayden MS, Ghosh S. Regulation of NF-κB by TNF family cytokines. *Seminars in immunology*. 2014;26(3):253-66.
 17. Pozniak PD, White MK, Khalili K. TNF-α/NF-κB signaling in the CNS: possible connection to EPHB2. *Journal of neuroimmune pharmacology : the official journal of the Society on NeuroImmune Pharmacology*. 2014;9(2):133-41.
 18. Al-Bari MA. Chloroquine analogues in drug discovery: new directions of uses, mechanisms of actions and toxic manifestations from malaria to multifarious diseases. *The Journal of antimicrobial chemotherapy*. 2015;70(6):1608-21.
 19. Long L, Yang X, Southwood M, et al. Chloroquine prevents progression of experimental pulmonary hypertension via inhibition of autophagy and lysosomal bone morphogenetic protein type II receptor degradation. *Circulation research*. 2013;112(8):1159-70.
 20. Shivakumar P, Rani MU, Reddy AG, et al. A study on the toxic effects of Doxorubicin on the histology of certain organs. *Toxicology international*. 2012;19(3):241-4.
 21. Kaymak E, Akin AT, Tufan E, et al. The effect of chloroquine on the TRPC1, TRPC6, and CaSR in the pulmonary artery smooth muscle cells in hypoxia-induced experimental pulmonary artery hypertension. *Journal of biochemical and molecular toxicology*. e22636.
 22. Park EJ, Kwon HK, Choi YM, et al. Doxorubicin induces cytotoxicity through upregulation of pERK-dependent ATF3. *PloS one*. 2012;7(9):e44990.
 23. Wang B, Guo H, Ling L, et al. The Chronic Adverse Effect of Chloroquine on Kidney in Rats through an Autophagy Dependent and Independent Pathways. *Nephron*. 2020;144(2):96-108.
 24. Mauthe M, Orhon I, Rocchi C, et al. Chloroquine inhibits autophagic flux by decreasing autophagosome-lysosome fusion. *Autophagy*. 2018;14(8):1435-55.
 25. Zhang W, Zhao Y, Zhang F, et al. The use of anti-inflammatory drugs in the treatment of people with severe coronavirus disease 2019 (COVID-19): The Perspectives of clinical immunologists from China. *Clinical immunology (Orlando, Fla)*. 2020;214:108393.
 26. Guo NF, Cao YJ, Chen X, et al. Lixisenatide protects doxorubicin-induced renal fibrosis by activating wNF-κB/TNF-α and TGF-β/Smad pathways. *European review for medical and pharmacological sciences*. 2019;23(9):4017-26.
 27. Kim DR, Lee SY, Kim JS, et al. Ameliorating Effect of Gemigliptin on Renal Injury in Murine Adriamycin-Induced Nephropathy. 2017;2017:7275109.
 28. Cortez M, Carmo LS, Rogero MM, et al. A high-fat diet increases IL-1, IL-6, and TNF-α production by increasing NF-κB and attenuating PPAR-γ expression in bone marrow mesenchymal stem cells. *Inflammation*. 2013;36(2):379-86.
 29. Reiterer G, Toborek M, Hennig B. Quercetin protects against linoleic acid-induced porcine endothelial cell dysfunction. *The Journal of nutrition*. 2004;134(4):771-5.
 30. Neale TJ, Rieger BM, Macaulay H, et al. Tumor necrosis factor-alpha is expressed by glomerular visceral epithelial cells in human membranous nephropathy. *The American journal of pathology*. 1995;146(6):1444-54.

31. Liu T, Zhang L, Joo D, et al. NF- κ B signaling in inflammation. Signal transduction and targeted therapy. 2017;2:17023.
32. Hoffmann A, Baltimore D. Circuitry of nuclear factor kappaB signaling. Immunological reviews. 2006;210:171-86.
33. Altinkaynak Y, Kural B, Akcan BA, et al. Protective effects of L-theanine against doxorubicin-induced nephrotoxicity in rats. Biomedicine & pharmacotherapy = Biomedecine & pharmacotherapie. 2018;108:1524-34.
34. Entezari Heravi N, Hosseinian S, Naji Ebrahimi Yazd Z, et al. Doxorubicin-induced renal inflammation in rats: Protective role of Plantago major. Avicenna journal of phytomedicine. 2018;8(2):179-87.
35. Zhang Q, Wu G, Guo S, et al. Effects of tristetraprolin on doxorubicin (adriamycin)-induced experimental kidney injury through inhibiting IL-13/STAT6 signal pathway. American journal of translational research. 2020;12(4):1203-21.
36. Wang Z, Huang W, Li H, et al. Synergistic action of inflammation and lipid dysmetabolism on kidney damage in rats. Renal failure. 2018;40(1):175-82.
37. Liu WJ, Luo MN, Tan J, et al. Autophagy activation reduces renal tubular injury induced by urinary proteins. Autophagy. 2014;10(2):243-56.
38. Havasi A, Dong Z. Autophagy and Tubular Cell Death in the Kidney. Seminars in nephrology. 2016;36(3):174-88.
39. Magwere T, Naik YS, Hasler JA. Effects of chloroquine treatment on antioxidant enzymes in rat liver and kidney. Free radical biology & medicine. 1997;22(1-2):321-7.
40. Duan X, Kong Z, Mai X, et al. Autophagy inhibition attenuates hyperoxaluria-induced renal tubular oxidative injury and calcium oxalate crystal depositions in the rat kidney. Redox biology. 2018;16:414-25.

Figure Legends

Figure 1. Hematoxylin and eosin (H&E) staining image of the groups. A. Control group, B. CLQ group, C. ADR group, D. ADR + CLQ group. Yellow arrow: Hemorrhagic area, arrowhead: glomerular degeneration and black arrow: Tubular damage, Image magnification x200.

Abbreviations: ADR: Adriamycin, CLQ: Chloroquine

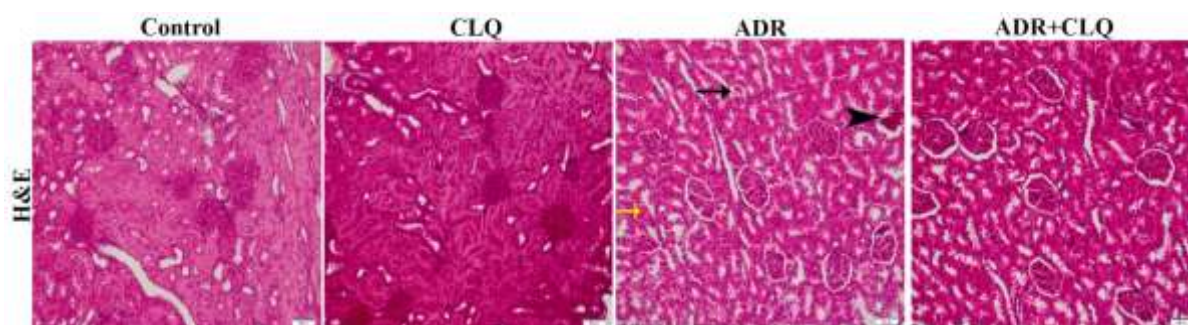


Figure 2. TNF- α and NF- κ B p65 immunohistochemistry staining images in kidney groups. Image magnification X200.

Abbreviations: ADR: Adriamycin, CLQ: Chloroquine, TNF- α : Tumor necrosis factor- α , NF κ -B p65: Nuclear Factor kappa B

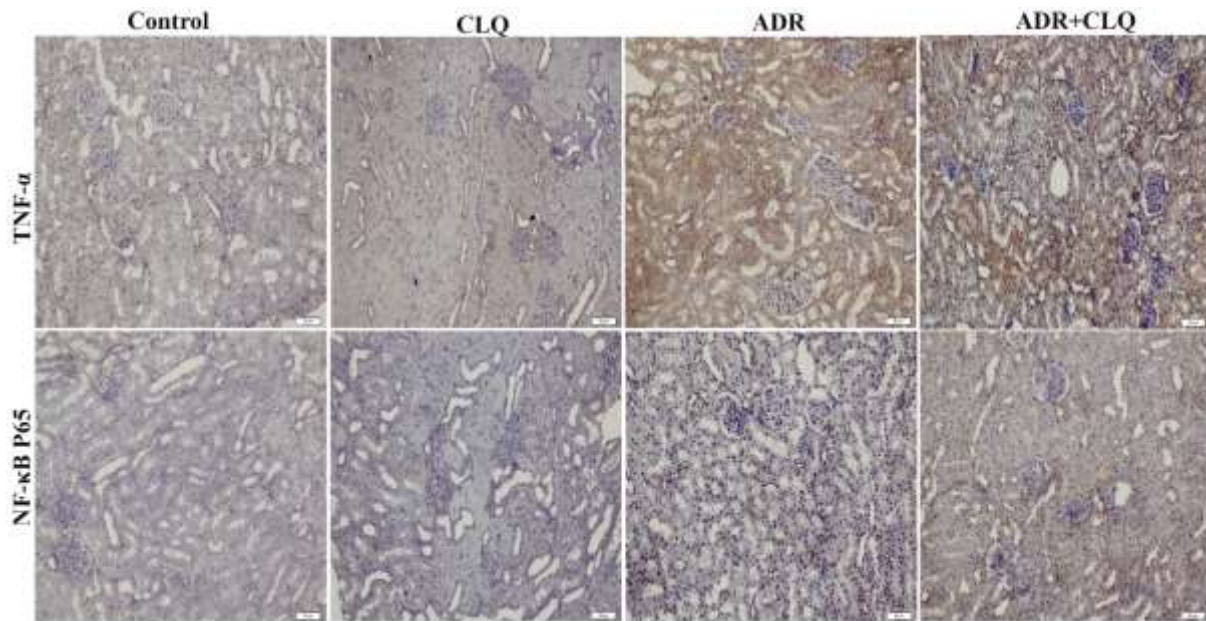


Table 1. TNF- α and NF- κ B p65 immunohistochemistry results between groups

Gruplar	Kontrol	CLQ	ADR	ADR+CLQ	<i>p</i>
TNF-α immunoreactivity	0.33 \pm 0.47 ^a	0.23 \pm 0.43 ^a	2.70 \pm 0.46 ^b	1.26 \pm 0.52 ^c	0.0001
NF-κB p65 immunoreactivity	0.20 \pm 0.40	0.16 \pm 0.37	2.80 \pm 0.40	1.36 \pm 0.55	0.0001

Data are expressed as mean \pm standard deviation. There is no significant difference between groups containing the same letter. $p < 0.05$ was considered significant.

Abbreviations: ADR: Adriamycin, CLQ: Chloroquine, TNF- α : Tumor necrosis factor- α , NF- κ B p65: Nuclear Factor kappa B P65