

Isolated Dorsal Dislocation of the 5th Carpometacarpal Joint; A Missed Injury

Ümit Aygün¹, Alikemal Yazıcı²

¹Istinye University Faculty of Medicine, VM Medical Park Samsun Hospital, Department of Orthopedics and Traumatology, Istanbul, Turkey.

²Near East University Faculty of Medicine, Department of Orthopedics and Traumatology, Nicosia, Cyprus.

Abstract

5th carpometacarpal (CMC) joint dislocations of the wrist region are very rare and easily overlooked injuries. In this type of injury, which causes serious functional problems in the hand if not treated appropriately, closed methods are generally used in the treatment. In this study, we present a case with fracture-dislocation of the 5th CMC joint. Fracture-dislocation of the 5th CMC joint of a 25-year-old patient who was admitted to the emergency department due to wrist pain was not noticed. The diagnosis was made during the follow-up of the patient, and the joint was reduced with closed method and fixed with a K wire. No serious problems were encountered in the patient's controls. Undiagnosed 5th CMC joint dislocation disrupts the transverse and longitudinal arches of the hand, so the patient has a weak and painful gripping function. Radiological findings may be unclear on anterior-posterior and lateral views, and additional images may be obtained if in doubt.

Keywords: Carpometacarpal dislocation, missed injury, fracture, closed reduction

Introduction

CMC joint dislocations constitute less than 1% of all carpal region injuries. Isolated dislocations of the fifth carpometacarpal - hamatometacarpal (HMC) joint are even rarer¹. The most common mechanism of this type of injury is blunt trauma to the ulnar side of the hand. Fractures and dislocations of the fifth CMC joint are more common than dislocations alone, and dorsal dislocations occur more frequently than volar dislocations². Insufficient care of the physician in clinical examination and radiographic examinations may cause such injuries to be easily overlooked, especially in clinics with a large patient population, and this may lead to long-term pain and poor grip strength in the hand^{2,3}. While stable HMC joint dislocations can be easily treated with reduction and casting, stabilizing the 5th CMC joint with various methods such as K wire in unstable injuries prevents long-term complications⁴. This case report aims to increase awareness regarding 5th CMC dislocations.

Case Report

A 25-year-old girl patient applied to the emergency service because of right wrist pain as a result of a motorcycle

accident. On physical examination, there was swelling and tenderness in the wrist, especially in the lateral region, and no neurovascular injury. The patient was told that there was no problem with the radiographs (Figure 1) and a follow-up visit was required one week later, making a short arm splint with the anti-inflammatory drug and recommendations. The patient came to the follow-up examination one month later and stated that she had removed her splint voluntarily one week after the event. In the radiographs of the patient (Figure 2) whose pain continued, there was a fracture-dislocation of the right-hand 5th CMC joint. The patient who did not want additional examination due to the fear of magnetic resonance imaging was recommended to intervene under anesthesia in terms of reduction because of a long time elapsed. Closed reduction was attempted under anesthesia but due to the instability observed, the 5th metacarp was reduced to the hamatum with one K wire (Figure 3 A, B). When the patient came to the follow-up after 4 weeks, the K wire was removed and the splint was terminated and the exercise was started. In the 3rd month, joint movements and muscle strength were observed to be complete. At the 10th month follow-up, such as postoperative radiographs it was observed that the 5th CMC joint was in the proper position in the hand radiography (Figure 3 C, D). A written informed consent was obtained from the patient for the publication of this study.

Corresponding Author: Ümit Aygün **e-mail:** aygun.umat@yahoo.com

Received: 23.04.2022 • **Revision:** 12.08.2022 • **Accepted:** 15.08.2022

DOI: 10.33706/jemcr.1108021

©Copyright 2020 by Emergency Physicians Association of Turkey - Available online at www.jemcr.com

Cite this article as: Aygun U, Yazici A. Isolated dorsal dislocation of the 5th carpometacarpal joint; a missed injury. Journal of Emergency Medicine Case Reports. 2022;13(3): 98-100

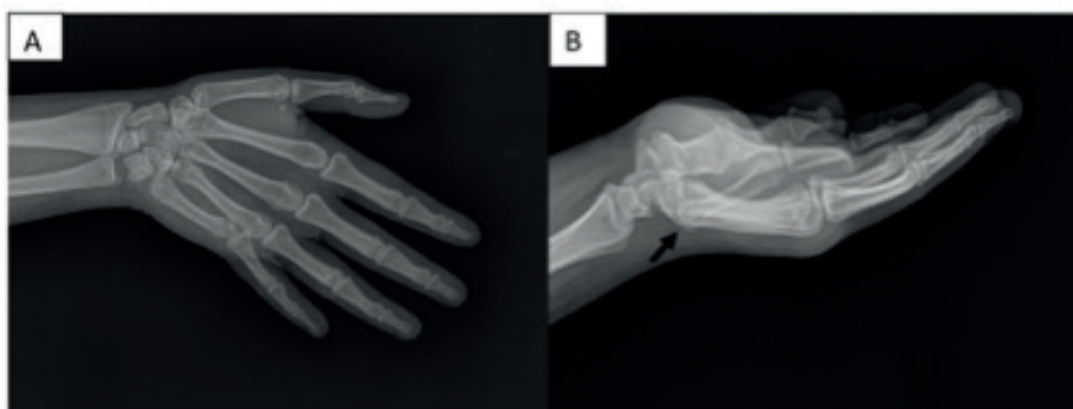

Figure 1. A) AP and B) lateral radiographs of the first arrival at the hospital, arrow; undiagnosed 5th CMC joint dislocation.

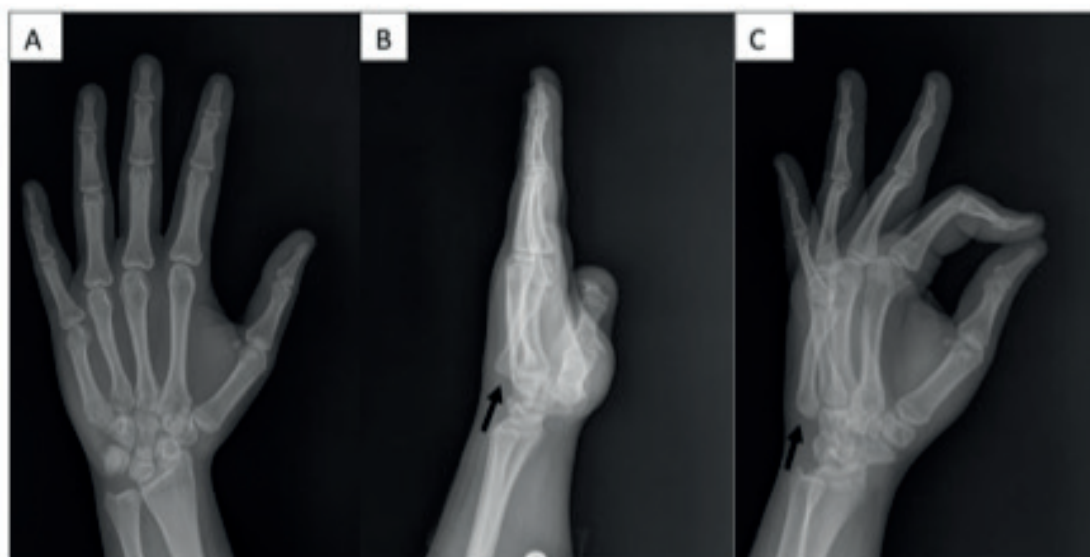


Figure 2. A) AP, B) lateral, and C) oblique radiographs of the second arrival at the hospital, arrow; fracture-dislocation of the 5th CMC joint.

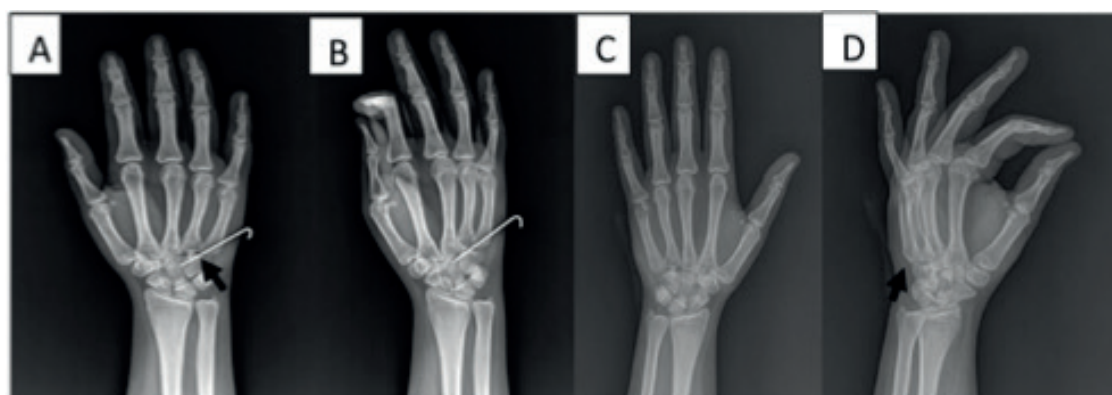

Figure 3. A) AP, B) lateral, and C) oblique radiographs of the second arrival at the hospital, arrow; fracture-dislocation of the 5th CMC joint.

Discussion

Dislocation of the 5th CMC joint, which can easily be overlooked in trauma patients, is seen rarely^{5,6}. These types of injuries are usually the result of severe events such as

traffic accidents and mostly concern the young age group. It was stated that 7% of dislocations in this region were missed in the first application of patients to the emergency department, and 25% of those that were overlooked were realized by senior registrars and orthopedic consultants.

Only one-third of the patients were correctly diagnosed at the time of the first injury⁷. In another study, decreased joint movements and weakened grip strength were observed in all patients with delayed diagnosis, and CMC arthrodesis was applied to approximately half of these cases⁸.

A remarkable feature of the⁵. CMC joint that distinguishes it from other CMC joints is that the radioulnar inclination in the frontal plane allows 10-20° supination, as seen when the little finger is opposing the thumb. This additional mobility causes the instability of the 5th CMC joint to increase and dislocations to be seen more in this region compared to other CMC joints⁹. The HMC joint has strong interosseous, dorsal, and volar ligaments. Although the dorsal ligaments are stronger, dorsal dislocations occur more frequently. However, the most prominent structure for stability is the intermetacarpal ligament between the 4th and 5th metacarpals. It was showed that even if other attachments of this region were damaged, keeping this ligament intact prevented subluxation or dislocation of the 5th CMC joint¹⁰.

Physical examination and radiological evaluation are important in the diagnosis of CMC joint dislocations. Dynamic muscles (extensor-flexor carpi ulnaris, hypothenar muscles) adhered to the base of the 5th metacarp with the deterioration of the articular surface pull the bone structure proximally and overlap the hamate, causing the little finger to appear proximally on physical examination⁵. AP images reveal loss of parallelism between CMC joints and overlapping of joint surfaces². An appropriate lateral radiograph is critical, especially to identify occult CMC joint subluxations, and should be carefully evaluated due to overlapping bony structures. Oblique radiographs are particularly stimulating to evaluate the ulnar region CMC joints^{3,6}. However, it may not be sufficient to define the features of fractures and to see occult subluxations with radiographs alone. Ultrasonography is an auxiliary method in evaluations and it should be considered that it provides dynamic research without radiation, its reproducibility is low and it has factors such as dependence on the person applying³. Therefore, computed tomography is the best diagnostic tool that makes the diagnosis definitively and clearly shows the relationship of the articular surfaces with each other².

This type of injury can be easily reduced by physical manipulation for up to ten days. In unstable reductions, fixation can be achieved with a K wire⁷. It can be healed by closed reduction and well molding in plaster without the need for internal fixation^{3,4,6}. Also the reduction loss can be seen in the first two weeks after physical manipulation⁶. Therefore, close follow-up with postoperative radiographs is important. This complication can be avoided with a K wire sent in one go after the reduction of the dislocated

joint. In cases encountered after 3 weeks, open reduction may be required^{2,3}. The deep motor branch of the ulnar nerve runs on the palmar surface of the 5th CMC joint and runs around the hook of the hamate. Therefore, the neurological evaluation of the hand should not be missed in the physical examination⁵.

Conclusion

CMC joint injuries are rare and can be overlooked. Undiagnosed 5th CMC joint dislocation disrupts the transverse and longitudinal arches of the hand, so the patient has a weak and painful gripping function. Radiological findings may be unclear on anterior-posterior and lateral views, and additional images may be obtained if in doubt. An unstable HMC joint dislocation is generally treated by closed or open reduction and internal fixation using a K wire.

References

1. Gaheer RS, Ferdinand RD. Fracture dislocation of carpometacarpal joints: a missed injury. *Orthopedics*. 2011;18:399.
2. Syed AA, Agarwal M, Giannoudis PV, Matthews SJE. Dorsal hamatometacarpal fracture-dislocation in a gymnast. *Br J Sports Med*. 2002;36:380-2.
3. Elghoul N, Jalal Y, Bouya A, Zine A, Jaafar A. Pure Isolated Dorsal Hamatometacarpal Dislocation in a Rider: A Case Report and Review of Literature. *J Orthop Case Rep*. 2018;8:29-31.
4. Metikala S, Herickhoff P. Isolated Dorsal Dislocations of the Fourth and Fifth Carpometacarpal Joints: A Case Report and Review of Literature. *Cureus*. 2020;12:e12310.
5. Beekhuizen S, de Witte PB, Rutgers M, Ohanis D. Isolated ulnopalmar dislocation of the fifth carpometacarpal joint. *BMJ Case Rep*. 2018;2018:bcr2018225363.
6. Cobb WA, Dingle L, Adami RZ, Rodrigues J. Management of fracture-dislocations of the little finger carpometacarpal joint: a systematic review. *J Hand Surg Eur Vol*. 2018;43:530-8.
7. Henderson JJ, Arafa MA. Carpometacarpal dislocation. An easily missed diagnosis. *J Bone Joint Surg Br*. 1987;69:212-4.
8. Miyamoto H, Adi M, Taleb C, Zemirline A, Bodin F, Gay A, et al. Fifth carpometacarpal fracture dislocations fixed with Meta-HUS ®: a series of 31 cases. *Eur J Orthop Surg Traumatol*. 2015;25:477-82.
9. Pundkare GT, Patil AM. Carpometacarpal Joint Fracture Dislocation of Second to Fifth Finger. *Clin Orthop Surg*. 2015;7:430-5.
10. Berg EE, Murphy DF. Ulnopalmar dislocation of the fifth carpometacarpal joint-successful closed reduction: review of the literature and anatomic reevaluation. *J Hand Surg Am*. 1986;11:521-5.