

Hand-Foot Syndrome Accompanied by Severe Oral Lesions during Capecitabine Therapy for Metastatic Colon Carcinoma

Metastatik Kolon Karsinomu Tedavisinde Kapesitabin'e Bağlı Ağır Oral Lezyonların Eşlik Ettiği El-Ayak Sendromu

Zehra Aşiran SERDAR¹, Işık GÖNENÇ², Şirin YAŞAR¹, Tuğba DORUK¹, Nurhan DÖNER¹

¹Haydarpaşa Numune Training and Research Hospital, Dermatology, İstanbul, Turkey

²Haydarpaşa Numune Training and Research Hospital, Family Medicine, İstanbul, Turkey

Abstract

Hand-foot syndrome (HFS) is a side effect of some chemotherapeutics appearing as dysesthesia, sharp-edged plaques and symmetrical lesions on palmoplantar areas. Our case is a 68-year-old male patient who developed a slight erythema and desquamation on the palms and soles of the feet during the third cycle of capecitabine treatment for advanced metastatic carcinoma. With this case report we aimed to draw attention to the development of HFS in patients receiving chemotherapy with capecitabine and raise awareness in the issue. The nonexistence of data in contemporary literature about the occurrence of hemorrhagic bullae in the oral mucosa makes our case noteworthy. (*Marmara Medical Journal 2011;24:200-2*)

Key Words: Chemotherapy-induced, Palmoplantar erythema, Side effect, Chemotherapeutics, Drug-induced reaction, Capecitabine

Özet

El-ayak sendromu (EAS) bazı kemoterapötiklerin yan etkisi olarak dizestezi, keskin kenarlı plaklarla ve palmoplantar alanlarda simetrik lezyonlar şeklinde görünür. Olgumuz ileri evre metastatik karsinom için kapesitabin tedavisinin üçüncü döngüsünde avuç içi ve ayak tabanlarında hafif eritem ve deskuamasyon gelişen, 68 yaşındaki erkek hastadır. Bu olgu sunumu ile kapesitabin kemoterapisi alan hastalarda gelişebilen EAS konusuna dikkat çekmeyi ve bilinç düzeyini yükseltmeyi amaçladık. Günümüz literatüründe ağız mukozasında hemorajik bül oluşumu hakkında bilgiye rastlanmaması nedeniyle olgumuz dikkat çekicidir. (*Marmara Üniversitesi Tıp Fakültesi Dergisi 2011;24:200-2*)

Anahtar kelimeler: Kemoterapiye bağlı, Palmoplantar eritem, Yan etki, Kemoterapötikler, İlaça bağlı reaksiyon

Introduction

Hand-foot syndrome (HFS), also known commonly as palmar-plantar erythrodysesthesia is a drug-induced reaction due to some chemotherapeutics^{1,2}. It is characterized by symmetrical involvement of the palmar and plantar surfaces with varying degrees of sharply demarcated erythematous plaques with edema accompanied by tingling, pain, dryness, increased pigmentation, pruritus and numbness, generally appearing after the second cycle of chemotherapy. Capecitabine is a prodrug of 5-fluorouracil used orally for metastatic colorectal carcinoma and breast cancer. The

prevalence of capecitabine related HFS is reported to be between 45-68 %¹⁻⁴. HFS, although commonly encountered in oncology departments, is a rare entity in dermatology clinics⁵.

Here, a case of HFS in a male patient during capecitabine therapy for metastatic colorectal carcinoma is presented. Permission was received from the deceased patient's relatives in order to report his case in medical publications.

Case Report

A sixty-eight year old man applied to our dermatology clinic with erythema and burning sensation on his palms and soles.

Correspondence to/İletişim: Işık Gönenc, M.D., Haydarpaşa Numune Training and Research Hospital, Family Medicine, İstanbul, Turkey
E-mail: gonenc68@yahoo.com

Submitted/Başvuru Tarihi: 03.08.2011 **Accepted/Kabul Tarihi:** 16.09.2011

© Marmara Medical Journal, Published by Galenos Publishing. / © Marmara Üniversitesi Tıp Fakültesi Dergisi, Galenos Yayınevi tarafından basılmıştır.

He reported that he was diagnosed with colon carcinoma two years ago and had been on capecitabine therapy for the last two months for metastasis. Although he had no complaints during the first two cycles of the therapy he developed erythema on the palmoplantar areas during the third cycle of chemotherapy. Dermatological examination at that time revealed slight erythema and desquamation on palmoplantar areas and the patient was evaluated as grade 1 HFS. Histopathological diagnosis could not be carried out since the patient refused biopsy so it was decided to continue with the chemotherapy and use topical steroids. On the tenth day of the fourth cycle the patient developed painful, edematous, livid red plaques and pigmented macules on both the palmoplantar and dorsal areas of his hands and feet and diffuse hemorrhagic bullae and erosions under the tongue (Figures 1- 2).

Oral capecitabine therapy was stopped immediately after evaluating the patient as progressing to grade 3, and orally administered 300mg/day pyridoxine, topical corticosteroids and emollients were started. On the 15th day of the reaction the lesions regressed with treatment.

The patient's death, due to multiple organ failure and sudden cardiac arrest two months after his admission, was reported by his relatives.

Discussion

HFS, also known as palmar-plantar dysesthesia (PPD), chemotherapy-induced acral erythema, acral erythema (AE), palmoplantar erythema, peculiar AE, or Burgdorf reaction, was first described in the literature in 1974 after treatment of hypernephroma with mitotan¹. In a metanalysis published in 1998, it was reported to be occurring more commonly in elderly women

but in 2002 studies done by Abushullaih et al. and Cassidy et al. revealed that its occurrence was independent of age and sex^{6,7}. Abushullaih also stated that HFS due to capecitabine therapy occurred most commonly and severely during the first two cycles of treatment⁶ whereas our case developed mild side effects on the third cycle and severe reactions on the fourth cycle of therapy.

HFS is characterized by acral erythema, numbness, tingling, dysesthesia or paresthesia on the palms and soles. These findings are rarely seen on the body, neck, chest, scalp or extremities¹. In advanced cases, desquamation, ulcerations, and blisters may occur following edema of the skin accompanied by pain. In our case, livid colored painful and edematous plaques, pigmented macules were detected both on the palmoplantar and dorsal parts of the hands and feet as well as diffuse hemorrhagic bullae and erosions under the tongue. Two different studies revealed HFS and stomatitis, as the most frequently encountered adverse events caused by capecitabine^{8,9}. The frequency of side effects concerning the oral mucosa described as stomatitis or mucositis of all grades occurring with capecitabine has been reported to be 11-15%. Although the underlying pathogenetic mechanism of capecitabine, causing stomatitis is not well documented, its stomatitis causing effect has been ascribed to a toxic effect on the basal keratinocytes and upper corion microvessels of the oral mucosa, with inhibition of DNA synthesis causing a subsequent apoptosis and decreased salivary flow rate¹⁰. Hemorrhagic bullae and ulcers of the oral mucosa observed in our patient were classified as grade 3 stomatitis but the literature lacks information about the formation of hemorrhagic bullae of the oral mucosa as observed in our case. There is only one case,

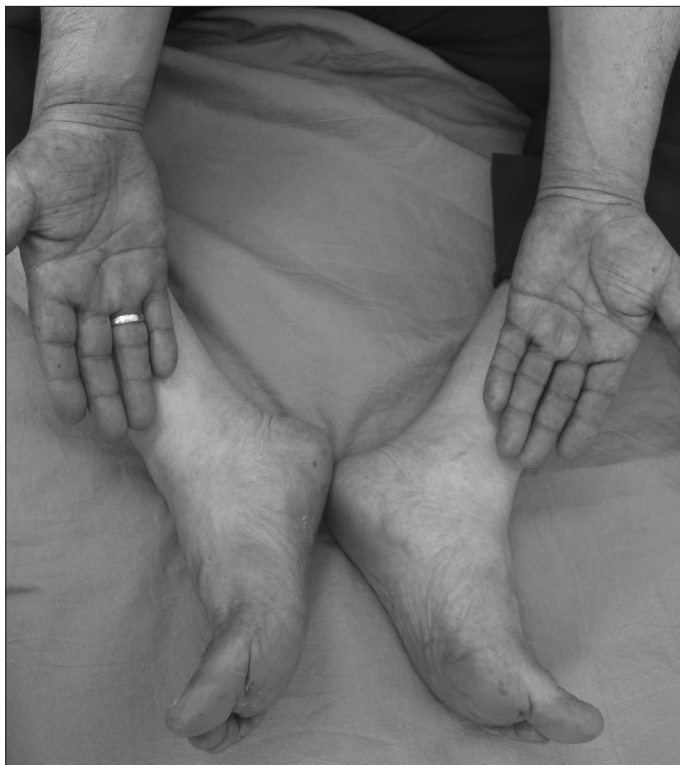

Figure 1. Livid colored painful edematous plaques and pigmented macules on the palms and soles

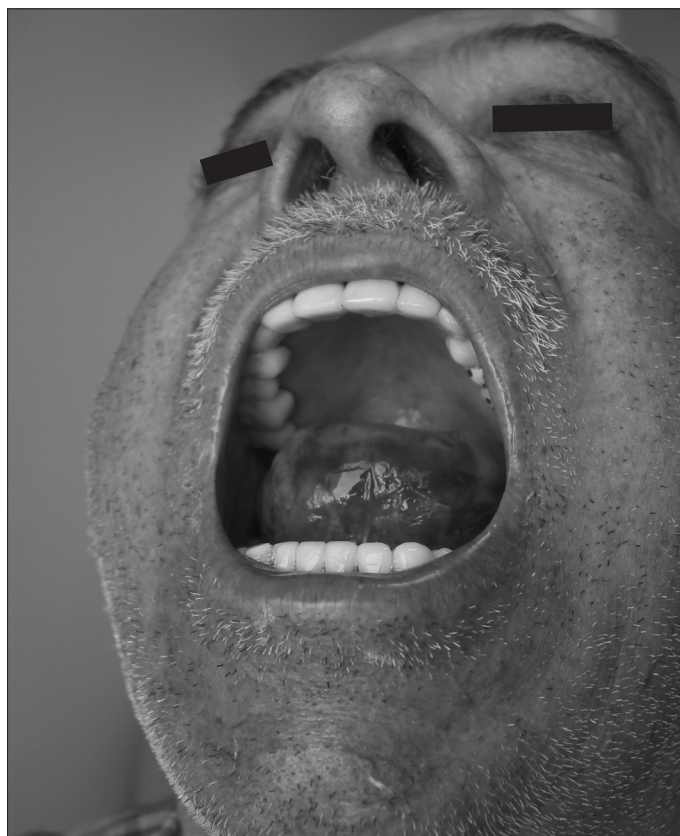


Figure 2. Hemorrhagic bullae and erosions under the tongue

reported by Mignogna and his colleagues, presenting with bullous and erythematous areas on the oral mucosa during lapatinib and capecitabine therapy¹⁰.

Although not a life threatening condition, HFS can interfere with the patients' daily activities and reduce the quality of life¹. No tests that measure the quality of life index were applied to our patient regarding capecitabine side effects but it could be clearly observed that the palmoplantar erythematous plaques and hemorrhagic bullous lesions in the mouth interrupted with the patient's daily activity of life and pain deteriorated the quality of his life.

While the World Health Organization (WHO) uses four grades, The National Cancer Institute (NCI) classifies HFS according to three grades⁴.

We graded our patient according to the definitions of NCI⁴ which classifies the HFS as:

Grade 1: Minimal skin changes such as erythema and peeling with altered sensations like numbness, tingling or burning that do not interfere with daily activities.

Grade 2: Although the skin surface remains intact, the pain accompanying the skin changes cause little interference with daily activities

Grade 3: The tissue breakdown is evident with peeling, blisters, bleeding and edema. Severe pain coexisting with ulcerative dermatitis or skin changes restricts activities of daily living considerably.

The WHO grading system however defines pain only in the fourth grade where as the first three grades mainly describe the syndrome limited to touch sensation and cutaneous lesions⁴.

Treatment of HFS depends on the cycle of the capecitabine therapy in which it appeared and will vary according to the complexity of the situation. While grade 1 HFS does not necessitate the need of dose reduction or discontinuation of therapy, in grade 2 or 3 HFS the treatment is stopped principally then continued again with a reduced dose calculated according to the patient's state¹.

The treatment of capecitabine related grade 1 HFS is mainly symptomatic. In this situation, topical steroids and moisturizers are generally preferred and sufficient. There is supporting literature regarding the benefits of regular applications of petroleum jelly in reducing the symptoms¹. Pyridoxine is thought to accelerate the skin barrier repair and prevent epithelial hyperplasia through antagonism of the P2X purigenic receptor. Doses of 100–500 mg/d of pyridoxine have been used for treating and preventing HFS^{1,2,4,5,11}. Saif commented on studies held among small patient groups regarding the positive effects of pyridoxine on patients receiving 5-FU for both the prophylaxis and treatment of HFS⁴.

These limited study results contradict the Korean randomized, double-blind, phase III study which shows no benefit of pyridoxine on 389 patients receiving capecitabine treatment for gastrointestinal malignancies¹².

Our case was evaluated as grade 1 upon his first application when the symptoms first appeared and his chemotherapy was continued with the same dose, but on the fourth cycle of therapy as blisters appeared progressively on the lesions the patient was considered as grade 3 and capecitabine treatment was stopped promptly, and 300 mg/day pyridoxine, topical steroids and moisturizers were started.

HFS due to capecitabine is a common side effect encountered in oncology departments but rarely seen in dermatology practice since these patients' symptoms resolve when the drug is discontinued. Attention should be paid to capecitabine treated patients in terms of side effects in order to ensure an optimal quality of life. Support treatment should be implemented when needed, in order to reverse side effects.

References

1. Lassere Y, Hoff P. Management of hand-foot syndrome in patients treated with capecitabine (Xeloda). *Eur J Oncol Nurs* 2004;31-40 doi:10.1016/j.ejon.2004.06.007
2. Turkmen M, Gerceker Turk B, Kılinc Kararslan I, Dereli T. Hand-foot syndrome induced by capecitabine: case report. *Turkiye Klinikleri J Dermatol* 2009;19:214-7.
3. Karatay E, Akbal E, Koca D, et al. Kapesitabin tedavisi alan hastada gelişen atipik el ayak sendromu: olgu sunumu. *Turk Onkol Dergisi*. 2008; 23(3):140-1
4. Saif MW, Elfiky AA. Identifying and treating fluoropyrimidine-associated hand and foot syndrome in white and non-white patients. *J Support Oncol* 2007;5:337–43.
5. Uslu G , Karaman FG , Uslu M, et al. Metastatik meme karsinomu nedeniyle kapesitabin tedavisi alan hastada gelişen el-ayak sendromu. *Turkderm* 2006;40(3):105-7
6. Abushullaih S, Saad Ed, Munsell M, Hoff PM. Incidence and severity of hand-foot syndrome in colorectal cancer patients treated with capecitabine: a single- institution experience. *Cancer Invest* 2002; 20:3-10.
7. Cassidy J , Twelves C , Van Cutsem E , et al. Capecitabine Colorectal Cancer Study Group. First line oral capecitabine therapy in metastatic colorectal cancer: a favorable safety profile compared with intravenous 5-fluorouracil/leucovorin. *Ann Oncol* 2002; 13:566-75. doi:10.1093/annonc/mdf089
8. Walko CM, Lindley C. Capecitabine: a review. *Clin Ther* 2005; 27:23-44. doi:10.1016/j.clinthera.2005.01.005
9. Saif MW, Katirtzoglou NA, Syrigos KN. Capecitabine: an overview of the side effects and their management. *Anticancer Drugs* 2008; 19:447–64.
10. Mignogna MD, Fortuna G, Falletti J, Leuci S. Capecitabine-induced stomatitis: a likely pathogenetic mechanism of oral lichenoid mucositis. *Eur J Clin Pharmacol* 2009; 65: 1057- 9. doi:10.1007/s00228-009-0674-z
11. Tavares-Bello R. Capecitabine-induced hand-foot syndrome and cutaneous hyperpigmentation in an elderly vitiligo patient. *J Eur Acad Dermatol Venereol*. 2007; 21: 1434- 5. doi:10.1111/j.1468-3083.2007.02242.x
12. Jeung HCl, Chung HC..Is pyridoxine helpful in preventing palmar-plantar erythrodysesthesia associated with capecitabine? *Asia Pac J Clin Oncol* 2010;6: 141–3. doi: 10.1111/j.1743-7563.2010.01326.x