



## CASE REPORT

### PARASPINAL INFILTRATIVE LIPOMA COMPLICATED WITH PARAVERTEBRAL ABSCESS IN A CHRONIC RENAL FAILURE PATIENT

Tarkan Çalışaneller, Özgür Özdemir, Halil Kıyıcı, Elif Karadeli  
*Başkent Üniversitesi, Nöroşirürji, Konya, Türkiye*

#### ABSTRACT

Intramuscular lipoma is a deep-seated lipoma that arises in the muscle and, due to its infiltrative nature mimicking malignant tumors, it poses a great concern for clinicians and pathologists. Presentation of an intramuscular lipoma in the paraspinal muscles is extremely rare. In this report, we presented a rare case of thoracolumbar paraspinal infiltrative lipoma complicated with paravertebral abscess in a chronic renal failure patient.

**Keywords:** Infiltrative lipoma, Paravertebral abscess, Paraspinal muscle

### BİR KRONİK BÖBREK YETMEZLİĞİ HASTASINDA PARAVERTEBRAL ABSE İLE KOMPLİKE OLMUŞ PARASPİNAL İNFİLTRATİF LİPOM

#### ÖZET

İntramusküler lipom, kas içinden köken alan ve infiltratif karakteri nedeni ile malign tümörleri taklit edebilen, ve bu yüzden klinisyenler ve patoloğlar açısından önem arzeden derin yerleşimli bir tümördür. İntramusküler lipomun paraspinal kaslar içinde yerleşmesi oldukça nadir görülen bir durumdur. Bu makalede, bir kronik böbrek yetmezliği hastasında paravertebral abse ile komplike olmuş paraspinal kaslar içinde yerleşmiş bir intramusküler infiltratif lipom olgusu sunuldu.

**Anahtar Kelimeler:** İnfiltratif lipom, Paravertebral abse, Paraspinal kas

#### INTRODUCTION

Lipomas are the most common benign tumors of the soft tissues and classified into superficial (cutaneous) and deep-seated (subfacial) types<sup>1</sup>. Intramuscular lipoma is a deep-seated lipoma that arises in the muscle and, due to its infiltrative nature mimicking

malignant tumors; it poses a great concern for clinicians and pathologists<sup>1,2</sup>. Intramuscular lipomas are frequently located in the chest wall and in the extremities and, rarely they can originate in the muscles of the head and neck region<sup>3,4</sup>. Presentation of an intramuscular infiltrative lipoma in the

#### Corresponding author:

Tarkan Çalışaneller, M.D.

*Başkent Üniversitesi, Nöroşirürji, Konya, Türkiye*

*e-mail: tarkan@baskent-kon.edu.tr*

*Marmara Medical Journal 2009;22(2);150-154*

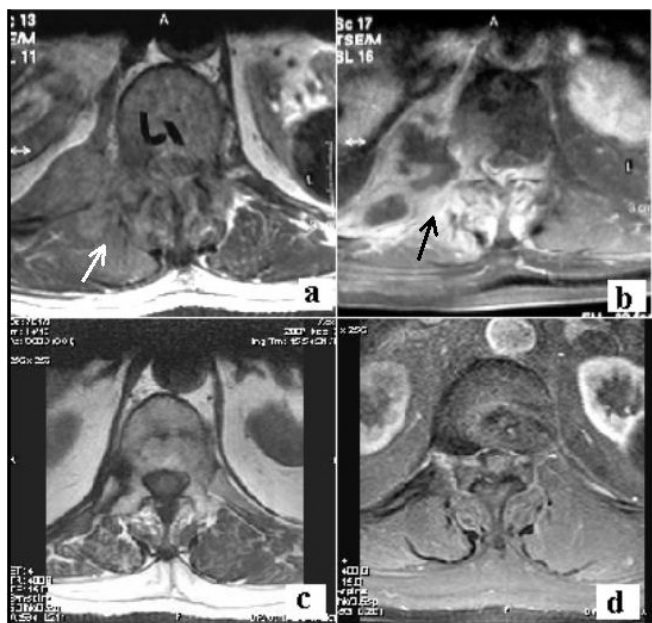


paraspinal muscles is extremely rare<sup>5</sup>. With this report, we present a thoracolumbar paraspinal infiltrative lipoma complicated with paraspinal abscess in a chronic renal failure patient.

### CASE REPORT

A 57-year-old male with a history of diabetes mellitus and chronic renal failure (under continuous ambulatory peritoneal dialysis for two years) was referred to our department complaining of severe back pain. He was hospitalized three weeks ago due to high fever and pain in the right upper quadrant of abdomen. Blood biochemistry displayed increased C-reactive protein level (166,1 mg/ml) and sedimentation rate (104 mm/h) without leucocytosis (10,2 K/iL). No source of infection could be identified during that period and intravenous ceftriaxone treatment was started due to positive blood cultures for staphylococcus aureus. On admission to our clinic, he was under ceftriaxone treatment for fifteen days. He was neurologically intact but there was right paraspinal muscle sensitivity at thoracal-12 (Th-12) and lumbar-1 (L-1) vertebral levels. Thoracolumbar magnetic resonance imaging (MRI) examination revealed a poorly demarcated, isointense soft tissue mass (11x7x4 cm) in the right paraspinal muscle at L-1 level on axial precontrast T1- weighted images (Fig-1a, white arrow). Fat-suppressed T1-weighted images following administration of intravenous gadolinium demonstrated peripherally enhanced heterogeneous cystic lesions within the right paravertebral muscles at Th-12 level. There was also diffuse contrast enhancement in the right paravertebral muscles and in the right pedicle of the Th-12 vertebra (Fig-1b, black arrow). Preoperative radiological diagnosis primarily suggested a paraspinal abscess or necrotic tumoral mass. A computerized tomography guided needle biopsy revealed non-diagnostic histopathological results and negative bacterial culture. Consequently, surgical intervention was planned.

Through a midline posterior approach between levels Th-12 and L-1 2levels, under general anesthesia, the lesion was identified beneath thoraco-lumbar fascia and surgical excision of the right paraspinal tissues was performed. Intraoperatively, the paraspinal tissues on the right side were yellowish in color and firm in texture. The lesion was infiltrative in nature and no clear dissection plane from surrounding structures was observed. Therefore, only subtotal excision of the posterior portion of the lesion could be achieved and the samples were sent for histopathological examination and bacterial cultures. Light microscopic examination revealed an infiltrative lesion composed of mature adipocytes in the striated muscle tissue (Fig-2). Irregular borders simulating an infiltrative pattern characterized the lesion histopathologically; but there were no cytological atypia, mitotic activity or necrosis. No significant fibrous or vascular proliferation was observed in the lesion. With these findings, the lesion was diagnosed as an infiltrative intramuscular lipoma. Bacterial cultures of the lesion revealed no bacterial proliferation. However, due to positive blood cultures for staphylococcus aureus and a strong suggestion of paravertebral abscess on the preoperative MRI examination, ceftriaxone treatment was changed to intravenous sulbactam-ampicilline treatment lasting for an additional month. The rest of the clinical course was uneventful and the patient was released from hospital on the sixth postoperative day. On the one-year follow-up thoracolumbar MRI examination, there was no recurrence of the tumor on axial precontrast T1- weighted images at the level of L-1 vertebra (Fig-1c). On fat-suppressed T1-weighted axial images with intravenous gadolinium, complete resolution of the abscess was observed and there was also no contrast enhancement in the paravertebral tissues at the level of Th-12 (Fig-1d). The C-reactive protein level was 9,5 mg/ml and the leukocyte count was 8,83 K/iL at the last blood biochemistry follow-up.



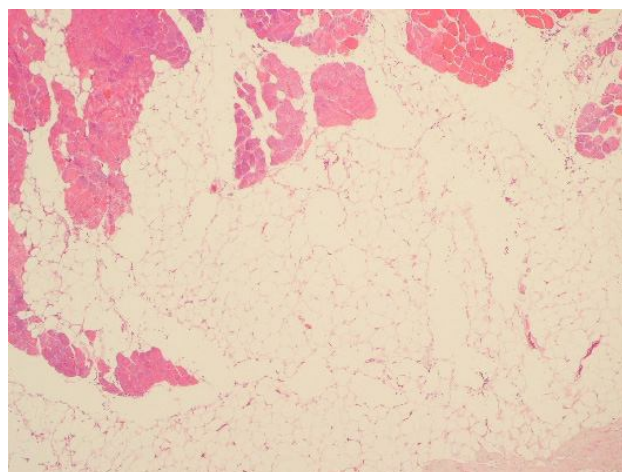
**Figure 1:** Figure 1: Axial precontrast T1- weighted image shows a soft tissue mass in the right paraspinal muscle at L1 level. The lesion is poorly demarcated, heterogeneous and isointense relative to paraspinal muscle (a). Fat- suppressed T1-weighted axial image following administration of intravenous gadolinium demonstrates peripherally enhanced heterogenous cystic lesions within right paravertebral muscles. There was diffuse contrast enhancement in the right paravertebral muscles secondary to inflammation (b). No recurrence of the tumor on axial precontrast T1-weighted images was observed at the level of L-1 vertebra (c). On fat-suppressed T1-weighted axial images with intravenous gadolinium, complete resolution of the abscess was observed and there was no contrast enhancement in the paravertebral tissues at the level of Th-12 (d).

## DISCUSSION

Lipoma is the most common benign mesenchymal tumor and classified as a superficial (cutaneous) or deep-seated (subfacial) type. Infiltrative lipoma is a relatively uncommon deep-seated benign tumor that arises in the muscle and poses a great concern for clinicians and pathologists due to its deep location and infiltrative nature mimicking malignant tumors. Although, benign tumors typically show a clear margin with surrounding tissues, infiltrative lipoma does not have a clear margin and shows proliferation of lipocytes between muscle

fibers and gradual replacement of muscle tissue by lipocytes.

Intramuscular lipomas are usually seen in adults over 40 years of age and generally presented as painless mass lesions<sup>6,8</sup>. There is general agreement that men afflicted more often than women. Tumors are mostly slow growing and painless, and they often become apparent only during muscle contraction, when the tumor is converted to a firm spherical mass. Sometimes, movement causes aching or pain but the pain is rarely severe. Tumor sizes vary considerably, ranging from minute lesions to tumors of 10 cm or more in diameter<sup>9</sup>.



**Figure 2:** Benign infiltrative lesion composed of mature adipocytes in the striated muscle tissue, 40x, H&E.

Typical locations of infiltrative intramuscular lipoma are the chest wall and the extremities, probably due to the large muscle bulk in these regions. It can sometimes originate in the muscles of the head and neck region and, presentation of an infiltrative lipoma in the paraspinal muscles is extremely rare. Although the etiology of lipoma is unclear, metaplasia, trauma, chronic irritation and congenital development are the suggested pathomechanisms<sup>7,10</sup>. A possible role of aberrant high mobility group proteins (HMGs) is suggested in the pathogenesis of infiltrative lipomas<sup>11,12</sup>.



For the preoperative diagnosis of infiltrative intramuscular lipoma, magnetic resonance imaging is the most useful radiological method. Lipomas may or may not contain radiologically detectable fat; however, classically, lipomas demonstrate high signal intensity on both T1- and T2-weighted images that is similar with subcutaneous fat<sup>13</sup>. On the other hand, infiltrative lipomas may have intermingled fat and muscle fibers which are isointense with normal muscle on both T1- and T2-weighted images<sup>9</sup>. The MRI findings of infiltrative lipoma vary from a small, single and homogenous mass to a large, inhomogeneous lesion with infiltrative margins. Fat-saturation sequences and the use of contrast agents can be helpful in the differentiation of lipomas from other types of tumors. Well-differentiated low-grade liposarcoma stands for the primary differential diagnosis and usually shows multinodularity and thick-irregular septa in MRI examinations<sup>9</sup>.

Histologically, infiltrative lipoma is composed of mature vacuolar fat cells without nuclear atypia<sup>1</sup>. Various amounts of stroma and capillary structures could also be observed. Cross sections of the intramuscular lipoma reveal gradual replacement of the muscle tissue by fat that may extend beyond the muscle fascia into the intermuscular connective tissue spaces. Microscopic examination reveals lipocytes that infiltrate muscle in a diffuse manner. The entrapped muscle fibers usually show few changes other than various degrees of muscular atrophy. Characteristically, the lipocytes are mature; there are no lipoblasts or cells with atypical nuclei as in well-differentiated liposarcoma. The existence of nuclear pleomorphism and multinuclear giant cells should suggest the diagnosis of liposarcoma. In some cases, well-differentiated intramuscular liposarcoma may be indistinguishable from intramuscular lipoma on Hematoxyline–eosin stained sections. For suspected cases, in situ Fluorescent Hybridization (FISH) technique may be useful for differential diagnosis.

Total resection is the treatment of choice and the prognosis is excellent if the tumor is

completely removed. In case of subtotal excision, the recurrence rate reported in the literature has varied from as little as 3.0% to as much as 62.5%<sup>8,10,14</sup>. Wide resection is suggested when recurrence occurs<sup>8</sup>.

In our patient, the infiltrative lipoma originated in a very atypical location and further, the diagnosis was complicated with a paravertebral abscess formation. The MRI characteristics of the paravertebral abscess together with the infiltrative nature of the lipoma primarily suggested the diagnoses of paravertebral abscess or necrotic metastatic tumor. Additionally, there was no clear margin of the lesion intraoperatively causing us to remove the lesion only subtotally. However, complete resolution of the contrast-enhanced paravertebral mass lesion after antibiotic treatment and the absence of recurrence in the surgical area at the one-year follow-up MRI examinations, supported the diagnosis of infiltrative paraspinal lipoma complicated with paravertebral abscess formation. In conclusion, paraspinal muscle is an extremely rare location for infiltrative lipoma and it can mimic several pathologies including malignant tumors. Since it is a benign tumor with an excellent prognosis, a high degree of suspicion is necessary for diagnosis

## REFERENCES

1. Enzinger FM, Weiss SW. Benign lipomatous tumors. In: Enzinger FM, Weiss SW, eds. Soft tissue tumors, 3rd edn. St. Louis: Mosby, 1995:381-430.
2. Fletcher CD, Martin-Bates E. Intramuscular and intermuscular lipoma: neglected diagnoses. *Histopathology* 1998; 12:275-287.
3. Mori K, Chano T, Matsumoto K, Ishizawa M, Matsusue Y, Okabe H. Type-selective muscular degeneration promotes infiltrative growth of intramuscular lipoma. *BMC Musculoskelet Disord* 2004; 18:5-20.
4. Ozcan C, Görür K, Talas D, Aydin O. Intramuscular benign lipoma of the sternocleidomastoid muscle: a rare cause of neck mass. *Eur Arch Otorhinolaryngol* 2005; 262(2):148-150.
5. Dattolo RA, Nesbit GM, Kelly KE, Cupp CL. Infiltrating intramuscular lipoma of the paraspinal muscles. *Ann Otol Rhinol Laryngol* 1995; 104(7):582-584.



6. Bennhoff DF, Wood JW. Infiltrating lipomata of the head and neck. Laryngoscope 1978; 88(5):839-848.
7. Lerosey Y, Choussy O, Gruyer X, François A, Marie JP, Dehesdin D, Andrieu-Guitrancourt J. Infiltrating lipoma of the head and neck: a report of one pediatric case. Int J Pediatr Otorhinolaryngol 1999; 47(1):91-95.
8. Mattel SF, Persky MS. Infiltrating lipoma of the sternocleidomastoid muscle. Laryngoscope 1983; 93(2):205-207.
9. Matsumoto K, Hukuda S, Ishizawa M, Chano T, Okabe H. MRI findings in intramuscular lipomas. Skeletal Radiol 1999; 28(3):145-152.
10. Péliissier A, Sawaf MH, Shabana AH. Infiltrating (intramuscular) benign lipoma of the head and neck. J Oral Maxillofac Surg 1991; 49(11):1231-1236.
11. Tallini G, Dal Cin P, Rhoden KJ, et al. Expression of HMGI-C and HMGI(Y) in ordinary lipoma and atypical lipomatous tumors: immunohistochemical reactivity correlates with karyotypic alterations. Am J Pathol 1997; 151(1):37-43.
12. Tkachenko A, Ashar HR, Meloni AM, Sandberg AA, Chada KK. Misexpression of disrupted HMGI architectural factors activates alternative pathways of tumorigenesis. Cancer Res 1997; 57(11):2276-2280.
13. Munk PL, Lee MJ, Janzen DL, et al. Lipoma and liposarcoma: evaluation using CT and MR imaging. AJR Am J Roentgenol 1997; 169(2):589-594.
14. Keskin G, Ustundag E, Ercin C. Multiple infiltrating lipomas of the tongue. J Laryngol Otol 2002; 116(5):395-397.