




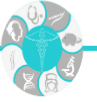Research Article | Araştırma Makalesi

NON-MASS ENHANCEMENT OF BREAST MRI: THE COMPARISON OF BENIGN AND MALIGNANT PATHOLOGICAL DIAGNOSIS AND ASSOCIATION OF INTERNAL ENHANCEMENT PATTERN AND DISTRIBUTION WITH BREAST CANCER MOLECULAR SUB-TYPES

MEME MRG'DE KİTLESEL OLMAYAN KONTRASTLANMA: BENIGN-MALİGN PATOLOJİK TANI VE MEME KANSERİNDE MOLEKÜLER ALT GRUPLARIN DAĞILIM VE KONTRASTLANMA PATERNLERİ İLE KARŞILAŞTIRILMASI

 Hande Uslu^{1*},  Mesude Tosun¹,  Arzu Serpil Arslan¹

¹Department of Radiology, School of Medicine, Kocaeli University, Kocaeli, Turkey.



ABSTRACT

Objective: The aim of our study is to investigate the distribution of lesions (focal, linear, segmental, regional, multiple regions, diffuse) and internal enhancement patterns (IEP) (homogeneous, heterogeneous, clumped, clustered ring) between benign and malignant type of non-mass enhancement (NME) and to evaluate the difference between Ki-67 and molecular subtypes (Luminal A, Luminal B, Basal-like, and HER2(+)) in malignant group.

Methods: A total of 923 women who underwent routine breast MRI between January 2015 and May 2018 were retrospectively reviewed. 88 MR images were included in the study. Histopathological results were 46 benign and 35 malignant lesions. We compared the distribution and IEPs between benign and malignant type of NME. In the malignant group, distribution and IEPs of different molecular subtypes and Ki-67 values were compared.

Results: Clustered ring internal enhancement were significantly associated with malignancy, while focal distribution and homogeneous enhancement pattern were associated with benignancy. A binomial logistic regression model explained 52.4% of the variance in benign-malignant status and correctly classified 77.3% of cases. Model sensitivity was 74.3%, specificity was 79.2%, positive predictive value was 70.2% and negative predictive value was 82.3%. There were not statistically significant differences in either distribution type of lesions or IEPs between molecular subtypes of malignant NME with different Ki-67 values.

Conclusion: 3-T MRI findings of focal distribution and homogeneous enhancement pattern were found to be a significant predictor of benign NME. Clustered ring enhancement can predict the probability of malignancy for non-mass like enhancement lesions.

Keywords: Breast MRI, non-mass enhancement, distribution, internal enhancement pattern, molecular sub-type, Ki-67.

Öz

Amaç: Çalışmamızın amacı, benign ve malign tip kitlesel olmayan kontrastlanma (KOK) ile malign grupta farklı Ki-67 değerleri ve moleküler alt gruplar (Luminal A, Luminal B, Bazal-benzeri ve HER2 (+)) arasında lezyonların dağılımı (fokal, lineer, segmental, rejyonel, multiple alanlar, diffüz) ve internal kontrastlanma paternleri (İKP) (homojen, heterojen, kümeli, kümelenmiş halka) açısından farklılık olup olmadığını değerlendirmektir.

Yöntem: Ocak 2015-Mayıs 2018 tarihleri arasında rutin meme MRG uygulanan toplam 923 kadın retrospektif olarak incelendi. Çalışmaya 88 MR görüntüsü dahil edildi. Histopatolojik sonuçlarda 46 benign ve 35 malign lezyon vardı. Benign ve malign KOK tipleri arasındaki dağılım ve İKP'leri karşılaştırdık. Malign grupta farklı moleküler alt gruplar ve Ki-67 değerleri dağılım ve İKP'leri ile karşılaştırıldı.

Bulgular: Kümelenmiş halka internal kontrastlanma paterni malignite ile anlamlı olarak ilişkiliyken, fokal dağılım ve homojen internal kontrastlanma paterni benignite ile ilişkiliydi. Binominal lojistik regresyon modeli, benign-malign durumdaki varyansın % 52.4'ünü açıklamış ve olguların % 77.3'ünü doğru sınıflandırmıştır. Model duyarlılığı %74.3, özgüllük %79.2, pozitif prediktif değer %70.2 ve negatif prediktif değer %82.3 idi. Farklı Ki-67 değerlerine sahip malign KOK'ların moleküler alt grupları arasında lezyonların dağılımı veya İKP'lerinde istatistiksel olarak anlamlı fark yoktu.

Sonuç: 3 Tesla (T) MRG'de fokal dağılım ve homojen internal kontrastlanma paterninin benign KOK'ların anlamlı bir belirleyicisi olduğu bulundu. Kümelenmiş halka internal kontrastlanma paterni, KOK'larda malignite olasılığını tahmin edebilir. **Anahtar Anahtar Kelimeler:** Meme MRG, kitlesel olmayan kontrastlanma, dağılım, internal kontrastlanma paterni, moleküler alt grup, Ki-67.

*İletişim kurulacak yazar/Corresponding author: Hande Uslu; Department of Radiology, School of Medicine, Kocaeli University Kocaeli, Turkey.

Telefon/Phone: +90 (530) 346 81 86 e-posta/e-mail: hande.uslu@kocaeli.edu.tr

Başvuru/Submitted: 09.06.2022

Kabul/Accepted: 09.09.2022

Online Yayın/Published Online: 15.10.2022

Introduction

According to the BI-RADS MRI lexicon, non-mass enhancement (NME) has been defined as an area of enhancement, distinct from the surrounding parenchyma and, not a space-occupying mass or focus (<5 mm area of enhancement).¹ NME can be distinguished from background parenchymal enhancement (BPE) and may be benign or malignant. 10-42% of the NME seen on MRI are malignant.² BI-RADS fifth edition mentions two morphologic characteristics of NME on MRI: IEP which includes homogeneous, heterogeneous, clumped, and clustered ring enhancement and distribution of lesion which includes focal, linear, segmental, regional, multiple regions, and diffuse.

Breast cancer subtypes were defined by clinicopathological criteria using molecular prognostic factors including ER, PR, HER2 and Ki-67 expressions. "Luminal" was defined ER and/or PR positive, HER2 negative with any Ki-67; "HER2(+)" (luminal) was defined ER and/or PR positive, HER2 overexpressed or amplified, any Ki-67; "HER2(+)" (non-luminal) was defined HER2 over-expressed or amplified, ER and PR negative; and "triple negative" was defined ER, PR and HER2 negative.^{3,4} For HER2 expression, scores of 0 and 1+ were accepted negative for overexpression of the HER2 gene, while scores of 3+ were accepted positive. Gene amplification by 'fluorescence in situ hybridization' (FISH) was used to determine HER2 status in tumors with a 2+ score. Ki-67 positive cancer nuclei of 14% or greater were considered a high value. Specifically, Luminal A tumors characterized by positive ER/PR and negative HER2, show the most favorable clinical features among the four subtypes. Luminal B tumors show less favorable clinical outcomes compared to Luminal A tumors. Triple negative tumors are characterized by the expression of cytokeratins 5/6 (CK5/6) and CK17 and are prevalent in patients with BRCA1 mutations.⁵ Triple negative and non-luminal HER2 over-expressing groups both are ER/PR-negative and have been associated with poor clinical features and survival.

In addition to conventional histopathologic parameters, proliferation is one of the major factors for the treatment decision in breast cancer patients and for predicting the risk of recurrence.⁶ Ki-67 proliferation index is a nuclear protein that is positively associated with cellular proliferation. Inwald et al. found that Ki-67 was an independent prognostic parameter of disease-free and overall survival in breast cancer patients and tumors with a high Ki-67 proliferation index were associated with poorer disease-free and overall survival than tumors with a low Ki-67 proliferation index.⁷

Although there are many studies of NME on breast MRI, there are few studies on the relationship between Ki-67 proliferation index and molecular subtyping. The aim of our study is to investigate the distribution of lesions (focal, linear, segmental, regional, multiple regions, diffuse) and IEP (homogeneous, heterogeneous, clumped, clustered ring) between benign and malignant

type of NME and to evaluate the difference between Ki-67 expression and molecular subtypes (Luminal A, Luminal B, Basal-like, and HER2(+)) in malignant group and report the situation in our department.

Methods

A total of 923 women (age range: 26-72) who underwent routine breast MRI with 3 Tesla (T) MR devices between January 2015 and May 2018 were retrospectively reviewed which was approved by our local ethical committee (KUGOKAEK2018/240). The inclusion criteria were as follows; a) presence of NME on breast MRI, b) patients with pathological diagnosis or no change in 2 years follow-up, c) molecular subtyping in malignant group, d) patients for whom MRI was indicated for preoperative staging prior to neoadjuvant chemotherapy and surgery. Patients with an NME lesion suggestive of BIRADS-3 but with follow-up duration shorter than 12 months, patients whose biopsy results were absent from our records and patients whose images were not accessible through the PACS database were excluded from the study. Regardless of the distribution, if enhancement was symmetrical or showed a slow onset increase of less than 50% with a persistent kinetic curve, it was considered as BPE and was not included in the study. According to these criteria, a total of 88 MR images (from 88 patients) were included in the study.

MRI Acquisition

All breast MRI were performed with a 3T MRI scanner (Achieva; Philips, Best, The Netherlands) using an 8-channel dedicated breast radiofrequency coil in a prone position before biopsy and treatment. The protocol included T1-weighted images, T2-weighted images, diffusion-weighted images, Short tau inversion recovery (STIR) images and a dynamic contrast enhancing (DCE) series. Axial T2 weighted images with fat suppression [repetition time (TR)/ echo time (TE), 4747/80 ms; flip angle (FA), 90°; field of view (FOV), 340x340 mm²; matrix size, 340x247; slice thickness, 3mm] were obtained. For the DCE series, post contrast axial T1 weighted images with fat suppression (TR/TE, 4.6/2.3ms; FA, 90°; FOV, 340x340 mm²; slice thickness, 2 mm, no gap) were obtained before and 1,2,3,4,5,6,7 min after an injection of 0.2 ml/kg of body weight of gadoteric acid (DOTAREM®; Guerbet, Aulnay-sous-Bois, France) at a rate of 3 ml/s, followed by a 20-ml saline flush. Axial images of both breasts were obtained for DCE-MRI.

Image Analysis

All 3T DCE-MR images were reviewed retrospectively for NME by three experienced breast radiologists (A.S.A., H.U. and M.T. with 20, 10 and 9 years of experience). Three radiologists worked independently of each other's evaluation and histopathological results. The evaluation of NME was based on IEP and the distribution type based on the descriptors of BI-RADS fifth edition. NME distribution was classified as focal, linear, segmental,

regional, multiple regions, diffuse; and IEP as homogeneous, heterogeneous, clumped, or clustered ring. Firstly, the NME lesion was identified on axial images via BPE (obtained at 128 seconds after contrast injection). Later, the distribution characteristics of lesions and IEP's were determined according to the following images: post-contrast axial images, maximum intensity projection (MIP) images and sagittal multi-planar reconstruction (MPR) images.

Pathologic Evaluation

Pathologic diagnoses were obtained from the electronic records at our institution, where all tissues' specimens were examined by a pathologist with more than 12 years of experience in breast pathology. The pathological diagnosis by surgical specimen, including excisional biopsy was representative; however, if the patients did not undergo surgery, the diagnosis was obtained by core needle biopsy (CNB) or stereotactic (ST) biopsy. The pathological diagnosis was established by core biopsy (n=10), excisional biopsy (n=7), or examination of lumpectomy or mastectomy specimens (n=64). There were histopathological results of 46 benign and 35 malignant lesions. NMEs with no changes in size and appearance for at least 2 years were included in benign group (n=7). Cases which were ER/PR-positive, CerbB2-negative and Ki-67 proliferation index \leq 14% were accepted as luminal A; ER/PR-positive, CerbB2-negative and Ki-67 proliferation index $>$ 14% were accepted luminal B; CerbB2-positive (ER/PR positive or negative) were accepted HER2(+); and ER/PR, CerbB2-negative were accepted triple negative molecular subtypes.

Statistical Analysis

A retrospective sample of 88 patients who had NME in DCE- MR imaging were included in the study. According to BI-RADS fifth edition, MR images were evaluated by three radiologists regarding the distribution of NME and IEP. Each radiologist rated the images in a room at different times where they could not influence each other's decision to avoid bias. Fleiss' kappa was run to determine if there was an agreement between radiologists' judgement on distribution type and IEP. Differences between benign and malignant NME groups in distribution types and IEP were analyzed by Fisher's exact test due to inadequate subgroup sample size for the chi-square test of homogeneity. With Fisher's exact test, molecular subtype groups were compared between distribution type and IEP. A one-way ANOVA test was conducted to determine if the mean Ki-67 proliferation index was different for distribution type and IEP for malignant NME's. All statistical analyses were performed using IBM SPSS for Windows version 23.0 (SPSS, Chicago, IL, USA).

Results

Study Participants

88 NMEs were identified in 88 patients (age range 26–72 years; mean age 47.5 years). The histopathologic analysis of the 88 NME lesions revealed 35 malignant (39.7%) and 53 benign (60.3%) lesions. The 35 malignant NME lesions were identified as : ductal carcinoma in situ (DCIS) (n=11), invasive lobular carcinoma (ILC) (n=1), and invasive ductal carcinoma (IDC) (n=23) while the 53 benign NME lesions were diagnosed as : atypical ductal hyperplasia (n=2), fibrocystic changes (n=10), intraductal papilloma (n=4), granulomatous mastitis (n=10), adenosis-fibrosis (n=2), and unspecified benign lesions or benign breast tissue (n=18).

Inter-observer Agreement Regarding the Distributions and Internal Enhancement Patterns of NMEs

Fleiss 'kappa was run to determine if there was agreement between radiologists' judgement on distribution type and IEP. There was very good and good agreement between the radiologists' judgements, $\kappa=0.97$ (95% CI, 0.90 to 1.03), $p<0.0005$ for distribution type and $\kappa=0.76$ (95% CI, 0.69 to 0.84), $p<0.0005$ for internal enhancement pattern, respectively.

Relations between Distributions and Internal Enhancement Patterns and Histopathologic Factors

Fisher's exact test was conducted due to an insufficient subgroup sample size for the chi-square test of homogeneity for analyzing NME distribution type. There was a statistically significant difference in distribution type of lesions between benign and malignant groups of NME, $p=0.011$. Observed frequencies and percentages of distribution type for benign and malignant NME are presented in Table 1.

Table 1. Crosstabulation of distribution type versus benign and malignant NME groups

Distribution of Lesions	Benign n (%)	Malignant n (%)	Post hoc p
Focal	25 (47.2)	4 (11.4)	<0.0005*
Linear	9 (17.0)	6 (17.1)	0.98
Segmental	9 (17.0)	13 (37.1)	0.04
Regional	7 (13.2)	7 (20.0)	0.55
Multiple Regions	2 (3.8)	3 (8.6)	0.38
Diffuse	1 (1.9)	2 (5.7)	0.56
Total	53 (100.0)	35 (100.0)	

*Statistically significant results at $p<0.0083$

Post hoc analysis involved pair-wise comparisons using multiple Fisher's exact tests (2x2) for distribution of lesions. Since distribution type of NME has six nominal category, a Bonferroni correction was applied, making the statistical significance at $p<0.0083$ ($0.05/6= 0.0083$). There was a statistically significant difference in the proportion of benign NME group compared to malignant one in focal distributions (n=25, 47.2% versus n=4, 11.4%), $p<0.0083$. No other pairwise comparisons were statistically significant in distribution type. Fisher's exact test was applied again to analyze IEP for the same reason.

There was a statistically significant difference in internal enhancement patterns between benign and malignant groups of NME, $p < 0.001$. Observed frequencies and percentages of IEP for benign and malignant NME are presented in Table 2.

Table 2. Crosstabulation of internal enhancement patterns versus benign and malignant NME groups

Internal Enhancement Patterns	Benign	Malignant	Post hoc p
	n (%)	n (%)	
Homogeneous	17 (32.1)	0 (0.0)	<0.0005*
Heterogeneous	30 (56.6)	21 (60.0)	0.82
Clumped	4 (7.5)	5 (14.3)	0.47
Clustered Ring	2 (3.8)	9 (25.7)	<0.006*
Total	53 (100.0)	35 (100.0)	

*Statistically significant results at $p < 0.0125$

For IEP, post hoc analysis involved pair-wise comparisons using multiple Fisher's exact tests (2x2). Since IEP of NME has four nominal category, statistical significance was accepted at $p < 0.0125$ ($0.05/4 = 0.0125$) with a Bonferroni correction. There were statistically significant differences between proportions of benign and malignant NME groups in homogeneous enhancement pattern ($n = 17, 32.1\%$ versus $n = 0, 0.0\%$), $p < 0.001$, and in clustered ring enhancement pattern ($n = 2, 3.8\%$ versus $n = 9, 25.7\%$), $p < 0.0125$. Differences in the proportion of benign NME group compared to malignant one in heterogeneous enhancement pattern ($n = 30, 56.6\%$ versus $n = 21, 60.0\%$), $p = 0.82$ or in clumped enhancement pattern ($n = 4, 7.5\%$ versus $n = 5, 14.3\%$), $p = 0.47$ were not statistically significant.

A binomial logistic regression was performed to ascertain the effects of lesion distribution type and IEP on the likelihood of having malignancy. The logistic regression model was statistically significant, $\chi^2(8) = 43.117$, $p < 0.0005$. The model explained 52.4% (Nagelkerke R²) of the variance in benign-malignant status and correctly classified 77.3% of cases. Sensitivity was 74.3%, specificity was 79.2%, positive predictive value was 70.2% and negative predictive value was 82.3% (Table 3). Of the two predictor variables only distribution type was statistically significant (as shown in Table 4). Since focal distribution significantly differed between benign and malign group, it was used as a reference category while comparing other categories with focal type. All distribution categories except diffuse type had higher odds to have malignancy compared to focal type, most prominent one was linear distribution with 32.15 times higher odds. IEP categories compared with homogeneous pattern as a reference, but none of them had significantly higher odds to have malignancy. In malignant groups of NME, distribution type and IEP of molecular subtype groups were compared with Fisher's exact test. Differences were not statistically significant in either distribution type of lesions or IEP, $p = 0.46$ and $p = 0.33$, respectively. Observed frequencies and percentages of distribution type and IEP for benign and malignant NME groups are presented in Table 5.

Table 3. Logistic regression model classification table

Observed	Predicted		
	Benign	Malignant	Correct Percentage
Benign	42	11	79.2% *
Malignant	9	26	74.3% †
Overall Percentage	77.3%6		

* Sensitivity; † Specificity

Table 4. Logistic regression predicting likelihood of malignancy based on lesion distribution type and internal enhancement pattern

	B	SE	Wald Statistics	df	p	Odds Ratio	95% CI for Odds Ratio	
							Lower	Upper
Distribution Type			11.047	5	0.050			
Linear	3.470	1.239	7.850	1	0.005	32.15	2.83	364.35
Segmental	1.530	0.743	4.243	1	0.039	4.61	1.07	19.79
Regional	1.975	0.831	5.648	1	0.017	7.20	1.41	36.73
Multiple Regions	2.060	1.087	3.588	1	0.058	7.84	0.93	66.11
Diffuse	19.794	7376.025	0.00	1	0.998	-	-	-
IEP			4.144	3	0.24			
Heterogeneous	35.808	10495.1	0.00	1	0.99	-	-	-
Clumped	36.739	10495.1	0.00	1	0.99	-	-	-
Clustered Ring	37.559	10495.1	0.00	1	0.99	-	-	-
Constant	-37.630	10495.1	0.00	1	0.99	-	-	-

Note: Reference categories were focal type and homogeneous pattern for distribution type and internal enhancement pattern, respectively (B: coefficient of predictor; SE: standard error; df: degree of freedom; CI: confidence interval; IEP: internal enhancement pattern)

A one-way ANOVA test was conducted to determine if the mean Ki-67 proliferation index was different for distribution type and IEP for malignant NME's. The differences between distribution type and IEP for malignant NME's was not statistically significant, $p = 0.93$ and $p = 0.95$, respectively.

Table 5. Crosstabulation of distribution type and internal enhancement patterns versus molecular subtype of malignant NME groups

Distribution of Lesions	Molecular Subtype								p
	Luminal A		Luminal B		HER2(+)		Triple (-)		
	n	%	n	%	n	%	n	%	0.46
Focal	2	15.4	0	0.0	1	8.3	1	33.3	
Linear	4	30.8	1	33.3	1	8.3	0	0.0	
Segmental	1	7.7	1	33.3	6	50.0	1	33.3	
Regional	4	30.8	1	33.3	1	8.3	1	33.3	
Multiple Regions	1	7.7	0	0.0	0	0.0	0	0.0	
Diffuse	1	7.7	0	0.0	1	8.3	0	0.0	
Internal Enhancement Patterns	n	%	n	%	n	%	n	%	0.33
Heterogeneous	10	76.9	1	33.3	5	41.7	3	100	
Clumped	1	7.7	0	0.0	3	25.0	0	0.0	
Clustered Ring	2	15.4	2	66.7	4	33.3	0	0.0	
Total	13	100%	3	100%	12	100%	3	100%	

Note: Homogeneous enhancement pattern not included to analysis due to lack of case.

Discussion

In the present study, the DCE features of breast NME lesions detected on 3.0 T MRI were analyzed to identify significant predictors of malignancy based on the fifth BI-RADS MRI lexicon. The study revealed that clustered ring internal enhancement pattern is a significant indicator of malignancy for breast NME ($p < 0.006$) (Table 1,2). The clustered ring internal enhancement pattern has been reported by several studies to be a reliable predictor of malignancy.^{5,8-10} The PPV of clustered-ring enhancement was 81.8%. Yang et al. showed that the most frequent

internal enhancement both for NMEs and malignant lesions was clustered ring (34.5% and 44.2%, respectively).¹¹ The frequency of clustered ring IEP was significantly different between malignant and benign lesions ($p=0.017$). The PPV for malignancy was 79.3%, which is higher than Uematsu's⁹ 12 result (77%), but lower than Tozaki's⁹ (96%). Our study's PPV result was similar with Yang et al.¹¹ However, the specificity and PPV values of clustered ring pattern vary from study to study; which may be explained by various factors such as, differences in study group size, use of different BI-RADS lexicons leading to different internal enhancement classifications, and variations in evaluation.

The most frequent internal enhancement pattern in our study was the heterogeneous pattern (Table 3). There was no association between malignancy and heterogeneous pattern enhancement which was also true when analysis was performed with distribution type and heterogeneous pattern combinations.

The results showed that in the benign group, focal distribution and homogeneous IEP were significantly frequent ($p<0.0005$, $p<0.0005$, respectively) (Table 4). The homogeneous pattern was not observed in any malignant lesions, making it the most favorable enhancement pattern. Likewise, various studies have reported a lack of association between malignancy and homogeneous pattern and very low PPV values.^{5,9,12-14}

Previous studies have reported a wide range of PPV results for focal and linear distribution; however, these values were consistently lower than that of segmental distribution. Furthermore, a couple of studies have reported that association with malignancy was the lowest with linear distribution.^{13,15} In our study, the most frequent distribution types were focal (32.9%), segmental (25%) and linear (17%) distribution. 4 (11.4%) of the 35 malignant lesions and 25 (47.2%) of 53 benign lesions showed focal distribution. Focal distribution pattern was more frequent in benign lesions than malignant lesions and the difference was statistically significant ($p<0.0005$). Baltzer et al. found that focal distribution was more frequent in benign lesions but it was not statistically significant.¹⁶ As reported in the literature, the PPV of segmental enhancement was the highest for malignant NME, ranging from 67% to 100% (10,15). 13 (37.1%) of the 35 malignant lesions and 9 (17%) of 53 benign lesions showed segmental distribution. While segmental was the second most frequent distribution type overall, it was the most frequent distribution type among malignant lesions; however, no statistically significant difference was found between benign and malignant lesions ($p=0.04$, cut-off p value accepted at 0.0083 with Bonferroni correction). This likely reflects the considerable size difference between benign and malignant lesions, which is discussed in the study limitations below. Other distribution patterns such as linear, regional, and multiple regions, were detected in both malignant and benign lesions with no significant differences.

A binomial logistic regression was performed to ascertain the effects of lesion distribution type and IEP on the

likelihood that having malignancy. The model explained 52.4% of the variance in benign-malignant status and correctly classified 77.3% of cases. Sensitivity was 74.3%, specificity was 79.2%, PPV was 70.2% and negative predictive value was 82.3%. Of the two predictor variables only distribution type was statistically significant. Since focal distribution significantly differed between benign and malign group, we took it as a reference category and compared other categories with focal type. All distribution categories except diffuse type had higher odds to have malignancy compared to focal type, most prominent one was linear distribution with 32.15 times higher odds. Liberman et al. reported that the overall PPV for linear- and branching-ductal patterns was 26%.¹⁷ Morakkabati-Spitz et al. found a 34% PPV for linear and segmental enhancement.¹⁸ Wilhelm et al. reported a 39.7% and 36.7% PPV for linear and ductal enhancement, respectively.¹⁹ Because "ductal" enhancement is reclassified as "linear" in the updated BI-RADS lexicon, we surmise that the previous PPV for "ductal" enhancement contributes to the high PPV for "linear" enhancement in the current data. When IEP categories were compared with homogeneous pattern as a reference, none of them had significantly higher odds to have malignancy.

In the malignant group, we found that most frequent subtypes were Luminal A and HER2(+) tumors (41.9% and 38.7% respectively). In Luminal A subtype, linear and regional distributions were most frequent (30.8%, either). In HER2 subtype, segmental distribution was the most frequent (50%). When we considered molecular subtype groups, differences were statistically not significant in either distribution type of lesions or IEP between molecular subtype of malignant NME, $p=0.46$ and $p=0.33$, respectively. Ko et al. described that HER2(+) tumors more often correspond to non-mass lesions compare to other breast cancer subtypes.²⁰ For HER2(+) cancers manifesting as masses, microlobulated or angular margins were most frequent type of margins. Also, Youk et al. described that the majority HER2(+) cancers presented most often round or oval shape, spiculated or irregular margins and heterogeneous enhancement.²¹ Other researchers have reported that the HER2(+) subtype often shows microcalcifications.^{22,23} However, no studies have examined the direct association of the HER2(+) subtype with NME, and more studies are required to determine the association of MRI findings with molecular subtypes.

In the present study, inter-observer agreement were very good and good, $\kappa=0.97$ (95% CI, 0.90 to 1.03), $p<0.0005$ for distribution type and $\kappa=0.76$ (95% CI, 0.69 to 0.84), $p<0.0005$ for internal enhancement pattern, respectively, whereas Machida et al.¹⁵ found only fair to moderate inter-observer agreement ($\kappa=0.26-0.45$) for the distributions and moderate agreement ($\kappa=0.41-0.42$) for a clustered ring IEP. We ascribe the better results obtained in the present study to the consensus pretesting conducted by the three readers using the BI-RADS lexicon fifth edition.

Lee et al. found that clustered ring IEP was significantly associated with invasive cancer, the absence of necrosis and high Ki-67 expression.² In the present study, we looked to determine if the mean Ki-67 proliferation index was different for distribution type and IEP for malignant NME's. The differences between distribution type and IEP for malignant NME's was not statistically significant, $p=0.93$ and $p=0.95$, respectively.

The greatest limitation of this study was a relatively small sample size where some of the tumor subtypes included a low number of tumors. Second limitation was the retrospective nature of our study; however, the design was unavoidable due to the rarity of NME lesions. Third limitation was the readers had different levels of experience, which might explain the different results, although overall inter-observer agreement was good to very good. Fourth limitation was our study included only NMEs without a mass, although cancers present more frequently as masses than NME lesions.

In conclusion, 3-T MRI findings of focal distribution and homogeneous enhancement pattern were found to be a significant predictor of benign NMEs. Clustered ring enhancement can predict the probability of malignancy for NMEs. Further prospective multi-institutional studies are warranted to validate our results.

Conflict of Interest

The authors declare no conflicts of interest.

Compliance with Ethical Standards

This study was approved by Kocaeli University local ethical committee (8 August 2018) (KUGOKAEK2018/240).

Author Contribution

HU: Study idea, hypothesis, study design; HU, MT, ASA: Material preparation, data collection and analysis; HU: Writing the first draft of the article; HU, MT, ASA: Critical review of the article finalization and publication process.

Financial Disclosure

The authors declared that this study has received no financial support.

References

- Ikeda D, Hylton N, Kuhl C. BI-RADS: Magnetic resonance imaging. In: D'Orsi CJ, Mendelson EB, Ikeda DM, et al, editors. Breast Imaging Reporting and Data System: ACR BI-RADS - Breast imaging atlas. 1st ed. Virginia: American College of Radiology; 2003.pp. 1-114.
- Lee SM, Nam KJ, Choo KS, et al. Patterns of malignant non-mass enhancement on 3-T breast MRI help predict invasiveness: using the BI-RADS lexicon fifth edition. *Acta Radiol.* 2018;59(11):1292-9. doi: 10.1177/0284185118759139
- Perou CM, Sørli T, Eisen MB, et al. Molecular portraits of human breast tumours. *Nature.* 2000;406(6797):747-52. doi: 10.1038/35021093
- Sorlie T, Tibshirani R, Parker J, et al. Repeated observation of breast tumor subtypes in independent gene expression data sets. *Proc Natl Acad Sci USA.* 2003;100(14):8418-23. doi: 10.1073/pnas.093269210.
- Sakamoto N, Tozaki M, Higa K, et al. Categorization of non-mass-like breast lesions detected by MRI. *Breast Cancer.* 2008;15(3):241-6. doi: 10.1007/s12282-007-0028-6.
- Wirapati P, Sotiriou C, Kunkel S, et al. Meta-analysis of gene expression profiles in breast cancer: toward a unified understanding of breast cancer subtyping and prognosis signatures. *Breast Cancer Res.* 2008;10(4):1-11. doi:10.1186/bcr2124.
- Inwald E, Klinkhammer-Schalke M, et al. Ki-67 is a prognostic parameter in breast cancer patients: results of a large population-based cohort of a cancer registry. *Breast Cancer Res. Treat.* 2013;139(2):539-52. doi :10.1007/s10549-013-2560-8.
- Yuen S, Uematsu T, Masako K, et al. Segmental enhancement on breast MR images: Differential diagnosis and diagnostic strategy. *Eur. Radiol.* 2008;18(10):2067-75. doi: 10.1007/s00330-008-0980-3.
- Tozaki M, Igarashi T, Fukuda K. Breast MRI using the VIBE sequence: clustered ring enhancement in the differential diagnosis of lesions showing non-masslike enhancement. *AJR Am J Roentgenol.* 2006;187(2):313-21. doi: 10.2214/AJR.05.0881
- Shimauchi A, Ota H, Machida Y, et al. Morphology evaluation of nonmass enhancement on breast MRI: Effect of a three-step interpretation model for readers' performances and biopsy recommendations. *Eur. J. Radiol.* 2016;85(2):480-8. doi: 10.1016/j.ejrad.2015.11.043.
- Yang Q-X, Ji X, Feng L-L, et al. Significant MRI indicators of malignancy for breast non-mass enhancement. *J. X-Ray Sci. Technol.* 2017;25(6):1033-44. doi: 10.3233/XST-17311.
- Uematsu T, Kasami M. High-spatial-resolution 3-T breast MRI of nonmasslike enhancement lesions: an analysis of their features as significant predictors of malignancy. *AJR Am J Roentgenol.* 2012;198(5):1223-30. doi: 10.2214/ajr.11.7350.
- Asada T, Yamada T, Kanemaki Y, et al. Grading system to categorize breast MRI using BI-RADS 5th edition: a statistical study of non-mass enhancement descriptors in terms of probability of malignancy. *Jpn J. Radiol.* 2018;36(3):200-8. doi: 10.1007/s11604-017-0717-9.
- Mahoney MC, Gatsonis C, Hanna L, et al. Positive predictive value of BI-RADS MR imaging. *Radiology.* 2012;264(1):51-8. doi: 10.1148/radiol.12110619.
- Machida Y, Tozaki M, Shimauchi A, et al. Two distinct types of linear distribution in nonmass enhancement at breast MR imaging: difference in positive predictive value between linear and branching patterns. *Radiology.* 2015;276(3):686-94. doi: 10.1148/radiol.2015141775.
- Baltzer PA, Benndorf M, Dietzel M, et al. False-positive findings at contrast-enhanced breast MRI: a BI-RADS descriptor study. *AJR Am J Roentgenol.* 2010;194(6):1658-63. doi:10.2214/AJR.09.3486.
- Lieberman L, Morris EA, Lee MJ-Y, et al. Breast lesions detected on MR imaging: features and positive predictive value. *AJR Am J Roentgenol.* 2002;179(1):171-8. doi: 10.2214/ajr.179.1.1790171.
- Morakkabati-Spitz N, Leutner C, Schild H, et al. Diagnostic usefulness of segmental and linear enhancement in dynamic breast MRI. *Eur. Radiol.* 2005;15(9):2010-7. doi: 10.1007/s00330-005-2755-4.
- Wilhelm A, McDonough MD, DePeri ER. Malignancy Rates of Non-masslike Enhancement on Breast Magnetic Resonance Imaging Using American College of Radiology

- Breast Imaging Reporting and Data System Descriptors. *Breast J.* 2012;18(6):523-6. doi: 10.1111/tbj.12008.
20. Ko ES, Lee BH, Kim H-A, et al. Triple-negative breast cancer: correlation between imaging and pathological findings. *Eur. Radiol.* 2010;20(5):1111-7. doi: 10.1007/s00330-009-1656-3.
 21. Youk JH, Son EJ, Chung J, et al. Triple-negative invasive breast cancer on dynamic contrast-enhanced and diffusion-weighted MR imaging: comparison with other breast cancer subtypes. *Eur. Radiol.* 2012;22(8):1724-34. doi: 10.1007/s00330-012-2425-2.
 22. Yamada T, Mori N, Watanabe M, et al. Radiologic-pathologic correlation of ductal carcinoma in situ. *Radiographics.* 2010;30(5):1183-98. doi: 10.1148/rg.305095073
 23. Tse G, Tan PH, Pang AL, et al. Calcification in breast lesions: pathologists' perspective. *J. Clin. Pathol.* 2008;61(2):145-51. doi: 10.1136/jcp.2006.046201.