



CASE REPORT

BRUCELLA EPIDIDYMO-ORCHITIS AS THE FIRST PRESENTING SIGN OF BRUCELLOSIS: A CASE REPORT AND REVIEW OF THE LITERATURE

Yılören Tanıdır, Abdülkadir Gümrah, Cem Akbal, Tufan Tarcan
Marmara University, School of Medicine, Department of Urology, İstanbul, Türkiye

ABSTRACT

While brucellosis is one of the causes of acute swelling of the testis, it is not encountered often in non-endemic regions. Although the most common genitourinary involvement of brucellosis is epididymo-orchitis, other findings may also occur. Herein, we report a patient with brucellosis presenting as the first sign as epididymo-orchitis, with the review of the current literature.

Keywords: Brucellosis, Epididymo-orchitis, Genitourinary infections

BRUSELLOZUN İLK BULGUSU OLARAK BRUSELLA EPİDİDİMO-ORŞİTİ: BİR OLGU SUNUMU VE LİTERATUR DERLEMESİ

ÖZET

Bruseloz testiste akut şişlik yapan nedenlerden biri olmakla beraber endemik olmayan bölgelerde sık rastlanılmaz. Brusellozda en sık genito üriner tutulum epididimo-orşit olmasına rağmen genelde kendisini brusellanın diğer bulgularıyla beraber gösterir. Biz bu olgu sunumunda, ilk bulgu olarak epididimo-orşit ile kendisini gösteren brusellozlu bir olguyu son literatür eşliğinde sunduk.

Anahtar Kelimeler: Brusella, Epididimo-orşit, Genitoüriner enfeksiyonlar

INTRODUCTION

Brucellosis is an infectious, zoonotic disease in various animals and humans caused by a gram-negative coccobacilli strain like *Brucella Melitensis* or *Brucella Abortus*. It is transmitted through contaminated and untreated meat, milk and milk products, and by direct contact with infected animals (cattle, sheep, goats, pigs, etc.), urine, body secretions and pregnancy materials. The incubation period is between one to four weeks. Brucellosis may be accompanied by aching muscles (myalgia), aching joints (arthralgia), gastrointestinal system symptoms such as nausea, vomiting, abdominal pain,

constipation, and rarely anemia, leucopenia, thrombocytopenia, localized and generalized lymphadenopathy; dermatological findings such as maculopapular rash; neurological findings such as meningitis, encephalitis; cardiac involvement such as endocarditis; and pulmonary or genitourinary involvement¹⁻³. Genitourinary involvement of brucellosis includes prostatitis, epididymo-orchitis, cystitis, pyelonephritis, interstitial nephritis, exudative glomerulonephritis and renal abscess. *Brucella* epididymo-orchitis is not a common clinical situation unless in an endemic area. Herein, we report a patient with brucellosis presenting with epididymo-orchitis, only.

İletişim Bilgileri:

Yılören Tanıdır, M.D.

*Marmara University, School of Medicine, Department of Urology,
Altunizade., İstanbul, Türkiye
e-mail: yiloren@yahoo.com*

Marmara Medical Journal 2008;21(1):056-060



CASE REPORT

A 16 -year-old sexually inactive male patient suffering from left testicular swelling, pain and high fever for the previous 4-5 days applied to our hospitals' emergency ward and was hospitalized in our urology clinic. The patient reported that he had had right testicular pain and swelling 3 months before and this was cured after antibiotic treatment.

His physical examination revealed left testicular swelling, tenderness and a temperature of 40 C°. Laboratory studies showed a mild leucocytosis (12600 /mm³), with an erythrocyte sedimentation rate of 52 mm/h, CRP 245 mg/l and urine microscopy of 2 white and 1 red blood cells per high power field. In the Doppler ultrasonographic examination of the scrotum, the right and left testis were 43x26x22 mm and 53x40x38 mm in size, respectively. Although parenchymal echogenicity was normal, there was a bilateral increase in blood flow, especially in the left testis. Right epididymis was normal but left epididymal echogenicity, blood flow and size was increased. Pyocele like appearance was observed in the left hemiscrotum (Figure 1). For differential diagnosis, tumor markers of testicular carcinoma were found to be within the normal limits (AFP: 1.03 U/L, hCG: <1 U/L). With these clinical findings the patient was started on standard epididymo-orchitis treatment with ciprofloxacin (200 mg i.v., b.i.d.), non-steroid anti-inflammatory medication, complete bed rest with scrotal elevation and local hypothermia application. But his fever and local symptoms did not decrease in the following 48 hours and scrotal swelling appeared to be larger on inspection. A pelvic-scrotal MRI was performed to rule out any pelvic pathology and testicular abscess (Figure 2). Due to resistant fever, the antibiotic regime was changed into i.v. sulbactam and ampicillin combination of 1 g, q.i.d. This new antibiotic schedule was continued for the following 48 hours but

again the clinical picture remained unchanged.

Thereafter, with a suspicion of Brucella-induced orchitis, Brucella spot and Wright agglutination tests were performed and each of them were found to be positive (the latter in a titer of 1/160). Among the former cultures which were taken during the admission period, bacteria in Brucella morphology were isolated from the blood culture but the urine culture was sterile. Relying on these clinical findings the patient was diagnosed as Brucella orchitis and medication composed of tetracycline in 100 mg p.o. b.i.d. and rifampicin 600 mg/day p.o. was started and continued for a 6-week period. Endocarditis and any cardiac involvement due to Brucellosis were ruled out by echocardiography. The symptoms completely resolved at the second week of treatment.



Figure 1: Doppler ultrasonographic examination of the left testis revealed increase in testicular blood flow and size with epididymal echogenicity. A pyocele like appearance was also observed in the left hemiscrotum.

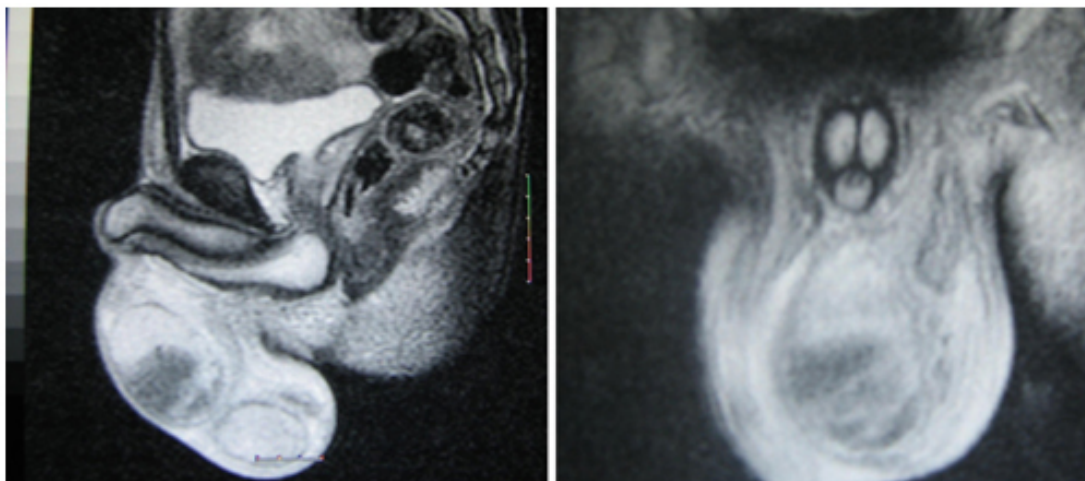


Figure 2: Scrotal MRI sections which was performed to rule out any testicular abscess, showed similar findings with scrotal ultrasonography.

DISCUSSION

Since Brucellosis is not an endemic disease in the Marmara Region of Turkey, presentation of the disease as Brucella epididymo-orchitis is not a common finding. The seropositivity rate in the healthy population in all geographical regions of Turkey is between 2-6%.⁴

Although epididymo-orchitis is the most common genitourinary involvement of Brucellosis, it is rarely the leading finding in most of the cases. In fact our patient did not present with typical findings of Brucellosis like muscle ache (myalgia), joint ache (arthralgia), gastrointestinal system symptoms such as nausea, vomiting, abdominal pain, constipation and rarely anemia, leucopenia, thrombocytopenia, localized and generalized lymphadenopathy, dermatological findings like maculopapular rash and neurological findings like meningitis, encephalitis and cardiac involvement like endocarditis and pulmonary involvement.

Hospitalization was indicated for our epididymo-orchitis patient who was suffering from fever-related fatigue with left testicular swelling and tenderness. Typical undulant fever pattern for Brucellosis was not observed

in our patient but his fever was always present between 39-40 C°. Testicular swelling can either be acute or chronic and it can be either unilateral as in our patient or bilateral in some of the cases⁵⁻¹³. As testicular swelling and fever are the leading features of almost every classical epididymo-orchitis case, the only key that made us suspect Brucella orchitis was resistant ongoing fever for 96 hours after 2 different antibiotic treatments. Wright agglutination test and blood culture were used in differential diagnosis to exclude other causes of epididymo-orchitis. The Brucella Wright titer was found to be 1/160 and Brucella sp was isolated in blood culture confirming the diagnosis of Brucella epididymo-orchitis. Urine culture and microscopy were negative as it is in almost 65 % of all Brucella epididymo-orchitis cases¹⁴.

In the literature, the incidence of epididymo-orchitis for Brucellosis in Turkey was noted between 2-12.7%⁷⁻⁹. Human brucellosis incidences cases in some Mediterranean countries are high, such as Greece and Spain where the true incidence for Brucella epididymo-orchitis is meant to be 12% and 2-20% respectively¹⁰⁻¹¹. In another study from Saudi Arabia the incidence was noted as 1.6%¹².



Differential diagnosis should include tumor, trauma, hematoma, cyst, torsion and other acute or chronic infections (abscess, gonorrhea, tuberculosis, mumps, syphilis, Chlamydia) which may lead to acute testicular swelling⁵. Beside clinical findings and physical examination, scrotal USG and testicular scintigraphy can also be used in differential diagnosis¹⁵. Scrotal USG findings in our case included parenchymal heterogeneity, pyocele and hydrocele formations but none of these particular findings helped us in differentiating the lesion from normal epididymo-orchitis. Pathological examination of Brucella epididymo-orchitis reveals a granulomatous inflammatory reaction and focal necrotizing areas. Most of these patients are reported to have a low fertility potential in the follow-up period⁸.

An interesting aspect of a study done by Akıncı et al showed clinical unilateral infection of the testis (brucella epididymo-orchitis) resulting in aspermia and oligospermia⁸. So they hypothesized that brucellosis causes decreased sperm counts and possibly caused infertility. Two possible explanations for these results were referred to Osegbe who found similar results in patients with unilateral epididymo-orchitis and performed bilateral testicular biopsies and to Ingerslev et al. who found a causal link between acute epididymitis and the development of antisperm antibodies¹⁶⁻¹⁷.

Antimicrobial therapy is generally enough in Brucellosis with uncomplicated epididymo-orchitis¹⁸. In antimicrobial therapy most common combinations are rifampicin plus either tetracycline, doxycycline or ofloxacin, and doxycycline plus streptomycin^{5,18-20}. There are several articles about the treatment efficiency of these combination therapies in the literature and the efficiency of each combination seems to be similar. The treatment period for the rifampicin plus doxycycline combination should be at least 6 weeks. The disease may relapse in some patients. In a report from Spain, the incidence of relapse was 25 %¹¹. Patients with necrotizing orchitis who cannot benefit from

antibiotic therapy may need orchiectomy^{5,13}, and²¹

In conclusion, Brucella epididymo-orchitis should be kept in mind for the etiology of epididymo-orchitis resistant to standard therapeutic approach especially in our country where Brucellosis is endemic in some regions.

REFERENCES

1. Levinson W, Jawetz E. (ed). Gram negative rods, related to animal sources. Chapter 20. In: Medical Microbiology and Immunology Examination and Board Review. Edition 4. Stamford, CT: Appleton & Lange, 1996: 116-117.
2. Akgün Y. Aktinomikoz Nokardiyoz. Topçu AW, Söyletir G, Doğanay M (ed). İnfeksiyon Hastalıkları. İstanbul :Nobel Tıp Kitabevleri, 1996:486-491 .
3. Hall WH, Khan MY. Brucellosis. In: Hoeprich PD, Jordan MC, eds. Infectious Diseases. Philadelphia: JB Lippincott Company, 1989:1281-1282.
4. Sözen TH. Bruselloz, In:Topçu AW, Söyletir G, Doğanay M, eds. İnfeksiyon Hastalıkları, 2. baskı. İstanbul:Nobel Tıp Kitabevleri, 2002:636-642.
5. Özsoy MF, Koçak N, Çavuşlu Ş. Brucella Orşiti: Beş olgu sunusu. KLİMİK Dergisi 1998;11:88-91.
6. Young EJ. An overview of human brucellosis. Clin Infect Dis 1995;21:283-290.
7. Aydoslu B, Çelik AD, Kuloğlu F, Tansel O, Akata F, Tuğrul M. Evaluation of brucellosis patients in Trakya University Hospital. Mikrobiyol Bul 2006 Jul;40:257-263.
8. Akıncı E, Bodur H, Çevik MA, et al. A complication of brucellosis: epididymo-orchitis. Int J Infect Dis 2006;10:171-177.
9. Yetkin MA, Erdinç FS, Bulut C, Tulek N. Epididymo-orchitis due to brucellosis in central Anatolia, Turkey. Urol Int 2005;75:235-238.
10. Papatsoris AG, Mpadra FA, Karamouzis MV, Frangides CY. Endemic brucellar epididymo-orchitis: a 10-year experience. Int J Infect Dis 2002 6:309-313.
11. Navarro-Martinez A, Solera J, Corredoira J, et al. Epididymo-orchitis due to Brucella mellitensis: a retrospective study of 59 patients. Clin Infect Dis 2001 ; 15;33:2017-2022.
12. Memish ZA, Venkatesh S. Brucellar epididymo-orchitis in Saudi Arabia: a retrospective study of 26 cases and review of the literature. BJU Int 2001; 88:72-76.
13. Reisman EM, Colquitt LA 4th, Childers J, Preminger GM. Brucella orchitis: a rare cause of testicular enlargement. J Urol 1990;143:821-822.
14. Al-Tawfiq JA. Brucella epididymo-orchitis: a consideration in endemic area. Int Braz J Urol 2006;32:313-315.
15. Tackett RE, Ling D, Catalona WJ, Melson GL. High resolution sonography in diagnosing testicular neoplasms: clinical significance of false positive scans. J Urol 1986;135:494-496.
16. Osegbe DN. Testicular function after unilateral bacterial epididymo-orchitis. Eur Urol 1991;19:204-208.



17. Ingerslev HJ, Walter S, Andersen JT, et al. A prospective study of antisperm antibody development in acute epididymitis. J Urol 1986 ;136:162-164.
18. Hall WH. Modern chemotherapy for brucellosis in humans. Rev Infect Dis 1990;12:1060-1099.
19. Kılıç D, Kurt H, Sözen TH, Kandilci S. Kan kültürlerinden izole edilen brucella cinsi bakterilerin antibiyotiklere duyarlılıkları ve klinik yönden değerlendirilmesi. Enfeksiyon Derg 1994;8:59-62.
20. Akova M, Uzun O, Akalın HE, Hayran M, Ünal S, Gür D. Quinolones in treatment of human brucellosis: comparative trial of ofloxacin-rifampin versus doxycycline-rifampin. Antimicrob Agents Chemother 1993 ;37:1831-1834.
21. Guy M, Nissim F, Eisenkraft S, Eliraz A. Brucella infection of the testis mimicking malignancy. Harefuah 1992 ;123:260-262.