



## CASE REPORT

### DOUBLE INTRAUTERINE DEVICE: PRESENTED WITH PROTRUDING URETHRAL STONE

Engin Kandıralı<sup>1</sup>, Mehmet Ata Topcuoğlu<sup>2</sup>, Atilla Semerciöz<sup>1</sup>, Ahmet Metin<sup>1</sup>

<sup>1</sup>Abant İzzet Baysal Üniversitesi, İzzet Baysal Tıp Fakültesi, Üroloji AD, Bolu, Türkiye <sup>2</sup>Abant İzzet Baysal Üniversitesi, İzzet Baysal Tıp Fakültesi, Kadın Hast. Doğum AD, Bolu, Türkiye

#### ABSTRACT

Intrauterine devices (IUDs) are widely used for reversible contraception. Perforation of the uterus and migration of the device into the retroperitoneal or abdominal cavity is a major but an infrequent complication. We present this report to highlight two interesting aspects of this case: One is that two IUDs were present simultaneously and second is that the patient presented with urethral stone after an asymptomatic period of 10 years.

**Keywords:** Migrated intrauterine device; Bladder stone; Complication

### ÜRETRA TAŞI İLE BAŞVURAN ÇİFT: İNTRAUTERİN ARAÇ

#### ÖZET

İntrauterin araçlar doğum kontrol yöntemi olarak sık kullanılmaktadır. Uterus perforasyonu ve intrauterin aracın yer değiştirmesi seyrek görülen ciddi bir komplikasyondur. Burada üretra taşı bulgusuyla başvuran hastada saptanan çift intrauterin araç vakası sunulmuştur.

**Anahtar Kelimeler:** İntrauterin araç, Mesane taşı, Komplikasyon

#### INTRODUCTION

The intrauterine device (IUD) is a highly effective, safe, cheap, and widely used reversible contraception method. A major but infrequent complication of IUD is perforation of the uterus and migration of the device into the retroperitoneal or abdominal cavity. Many authors have reported extrauterine mislocated IUD<sup>1-4</sup>. We present this report to highlight two interesting aspects of this case: Firstly that two IUDs were present simultaneously and secondly is that the patient presented with urethral stone after an asymptomatic period of 10 years.

#### İletişim Bilgileri:

Dr. Engin Kandıralı,  
Abant İzzet Baysal Üniversitesi, İzzet Baysal Tıp Fakültesi, Üroloji  
AD, Bolu, Türkiye  
e-mail: ekandirali@yahoo.com

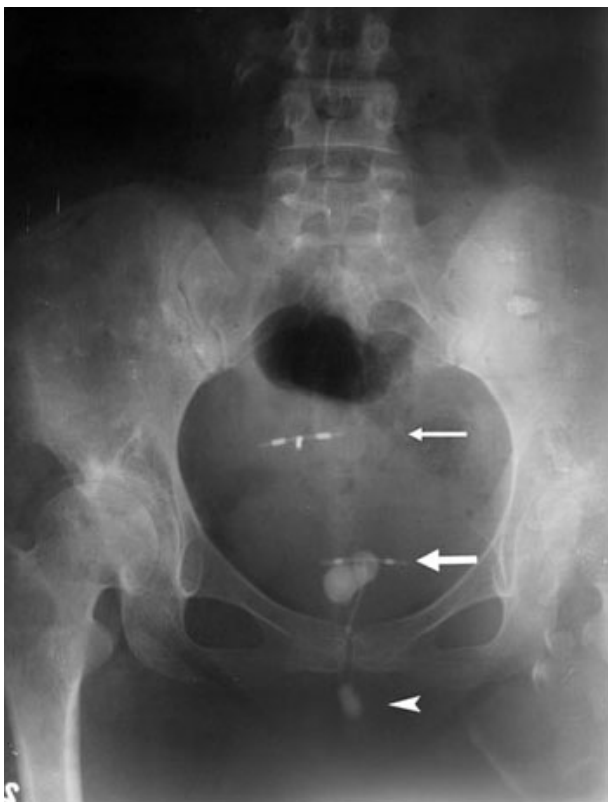
#### CASE REPORT

A 34-year-old woman, gravida 4, para 3, abortion 1, presented with protruding urethral stone attached to a string. The patient's medical history revealed that a copper-T IUD had been inserted in 1995, 6 months following her second normal vaginal delivery. She had unexpectedly conceived again three months after insertion and had a normal spontaneous vaginal delivery without any complication. It was assumed that the IUD had fallen out and another copper-T IUD was inserted one year after her third delivery. The

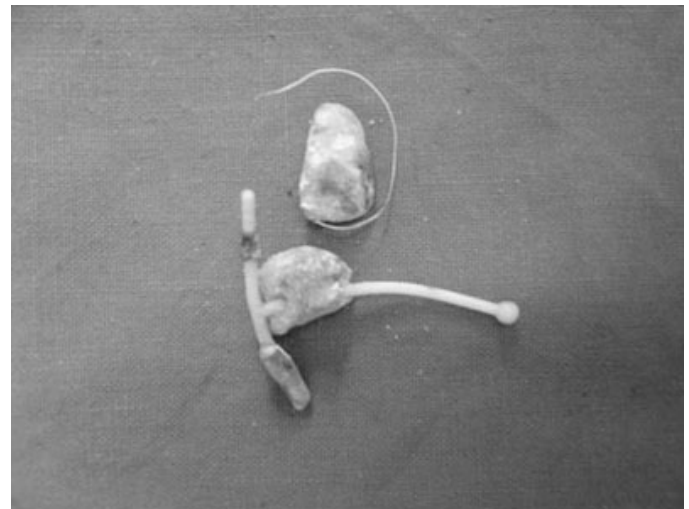
Marmara Medical Journal 2008;21(1);061-063



stone formation protruding from the urethra was observed on inspection. The IUD string was identified on gynecological examination. Physical examination was otherwise unremarkable. Plain abdominal radiograph revealed two IUDs within the pelvic cavity (Figure 1); one of them was surrounded by stone formation. The patient underwent cystoscopy and a free intravesical IUD with stone formation was observed. It was also observed that the protruding string with stone distally belonged to the intravesical IUD. Because of technical problems, a suprapubic cystotomy was performed and the IUD with stone formation was removed (Figure 2). The postoperative period was uneventful and the patient was discharged from the hospital on the fifth postoperative day.



**Figure 1:** A plain radiograph demonstrates two intrauterine devices (IUD) within the pelvic cavity (thin arrow: IUD in normal intrauterine position, thick arrow: intravesical IUD in stone formation, arrow head: protruding urethral stone).



**Figure 2:** A migrated intrauterine device with stone formation and stone attached to a string.

## DISCUSSION

The intrauterine device is the most popular method for reversible conception because it is effective, safe, and cheap. One of the major complications of IUDs is perforation of the uterus and migration of the IUD into the pelvic or abdominal organs<sup>1</sup>. The incidence of perforation is estimated as 1.9-3.6 per 1000 insertion<sup>5</sup>. Perforation is related to the timing and technique of insertion, type of IUD used, skills of the physician, and anatomy of the cervix and uterus<sup>5</sup>. Perforation occurs most frequently at the time of insertion but may also occur spontaneously, later on or during puerperium<sup>2</sup>. The risk of perforation increases especially during puerperium because the uterus wall is thin. Caesarean section and breastfeeding at the time of IUD insertion are other risk factors<sup>5</sup>. When a pregnancy occurs in a patient with an IUD, perforation must be ruled out. In our case, perforation happened probably during IUD insertion and because of its rarity no further examination was performed or was not taken into consideration.

Intravesical migration of IUD is uncommon; it has been reported in about 50 cases in the literature<sup>3</sup>. Migrated IUDs can either be embedded in the bladder wall or can float



freely in the bladder. Fewer than half of these cases have resulted in bladder calculus formation<sup>3</sup>. Although controversy in the management of the migrating IUDs in asymptomatic patients still persists, it appears to be a consensus that all extrauterine copper-laden devices should be removed because of the increased inflammatory reaction they induce. Extrauterine device which does not contain copper and does not cause any symptoms should be left in place because of the risks that may result in abdominal surgery and anesthesia<sup>1,2,4</sup>. No controversy exists about the management of an IUD that has migrated into the bladder. All IUDs in the bladder must be removed because of potential complications. A migrated IUD in the bladder can be removed by cystoscopy or suprapubic cystotomy<sup>3,4</sup>.

In this case report, a patient with double IUDs, one of them located intravesically was presented because of the rarity of the case and a long asymptomatic period. The perforation

itself does not necessarily cause alerting symptoms, so the event may remain unnoticed. Therefore, clinicians should check for correct insertion, either by identifying the string of the device after a period of time or by ultrasound, especially in the presence of pregnancy.

## REFERENCES

1. Nitke S, Rabinerson D, Dekel A, et al Lost levonorgestrel IUD: diagnosis and therapy. *Contraception* 2004; 69:289-293.
2. Markovitch O, Klein Z, Gidoni Y, et al Extrauterine mislocated IUD: is surgical removal mandatory? *Contraception* 2002; 66:105-108.
3. Hick EJ, Hernandez J, Yordan R Bladder calculus resulting from the migration of an intrauterine contraceptive device. *J Urol* 2004; 172:1903.
4. Hoscan MB, Kosar A, Gumustas U, et al Intravesical migration of intrauterine device resulting in pregnancy. *Int J Urol* 2006; 13:301-302.
5. Farmer M, Webb A. Intrauterine device insertion-related complications: can they be predicted? *J Fam Plann Reprod Health Care* 2003; 29:227-231.