

# An Unusual Pediatric Monteggia Equivalent Lesion: A Rare Case Report

Metin Celik<sup>1</sup>, Emre Arıkan<sup>2</sup>, Omer Faruk Yılmaz<sup>3</sup>

<sup>1</sup>Department of Orthopaedics and Traumatology, Malatya Education and Research Hospital, Malatya, Turkey.

<sup>2</sup>Department of Orthopaedics and Traumatology, Cekirge State Hospital, Bursa, Turkey.

<sup>3</sup>Department of Orthopaedics and Traumatology, Bolu Abant İzzet Baysal University, Bolu, Turkey.

## Abstract

Monteggia lesion is a rare fracture in which ulna shaft fracture and radial head dislocation occur together. Monteggia equivalent is the lesion associated with ulna shaft fracture and radius head and/or neck fracture. We offer a case of Monteggia equivalent in a 9-years-old boy. In the surgery of the patient, anatomical plating was performed for ulna shaft fracture and intramedullary nail was applied for radius neck fracture. When we look at the literature, such case reports are very rare. In the 1-year follow-up of the patient, there was no loss in flexion, extension, supination and pronation range of motion.

**Keywords:** Internal fixation, monteggia equivalent, radius neck fracture, ulna shaft fracture

## Introduction

Monteggia is an uncommon lesion where fracture of the ulna is accompanied by dislocation of the radio-humeral joint. It was first expressed by Milanian Giovanni Batista Monteggia in 1814<sup>[1]</sup>. Monteggia fracture dislocation is a lesion that occurs in less than 1% of all pediatric elbow injuries<sup>[2]</sup>. In addition, lesions named as Monteggia equivalent were defined as private forms by Bado. These lesions are even less common in children than a Monteggia fracture<sup>[1]</sup>. In the literature, Monteggia equivalent lesions associated with both ulna shaft or olecranon fracture and radius neck or head fracture have been reported rarely. We present our Monteggia equivalent case associated with 1/3 proximal fracture of the ulna and radius neck fracture.

## Case Report

A 9-years-old boy fell from a height of 3 meters and applied to the emergency room. The patient had an isolated right forearm and right elbow injury. On physical examination, there was deformity and limitation of motion in the elbow and forearm. Neuro-vascular and skin examination were normal. Bidirectional radiograph of the elbow revealed a fracture in the radius neck and 1/3 proximal of the ulna without dislocation. (Figure 1). The patient was operated on the same day. After osteosynthesis with a LCDCP plate with a postero-

medial approach to the ulna, it was observed that the radius neck fracture was not reduced under fluoroscopic control. Considering the patient's age and the shape of the deformity, the radius neck fracture was reduced using the Metaizeau technique (Figure 2). No postoperative complications were observed. Postoperative immobilization was provided on the splint for 4 weeks. The intramedullary nail was removed after 3 months. The clinical and radiological examination was uneventful in the patient's controls. In the 1-year follow-up, the fracture lines were completely fused, the elbow was stable, painless, and the movements were complete (Figure 3) (Figure 4).

In this case report, written informed consent was obtained from the patient and his parents for the publication of all images.

## Discussion

Monteggia lesion, by Giovanni Battista Monteggia in 1814; It is defined as a forearm injury in which ulna fracture and radial head dislocation occur together. Monteggia injury is very rare in children<sup>[3]</sup>. Monteggia lesion occurs in less than 1% of pediatric fractures and can be considered a rare injury with an incidence of 2% to 5% of forearm fractures<sup>[2]</sup>. We thought to share our extremely rare patient with ulna shaft fracture and ipsilateral radius neck fracture in the literature (Figure 1).

**Corresponding Author:** Emre Arıkan

**e-mail:** dremrearikan@gmail.com

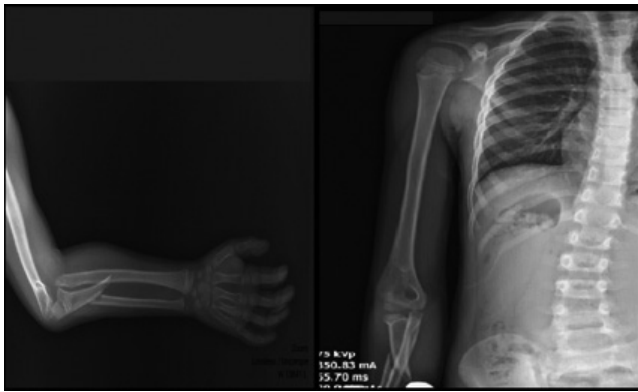
**Received:** 19.06.2022 • **Accepted:** 07.07.2022

**DOI:** 10.33706/jemcr.1132878

©Copyright 2020 by Emergency Physicians Association of Turkey -

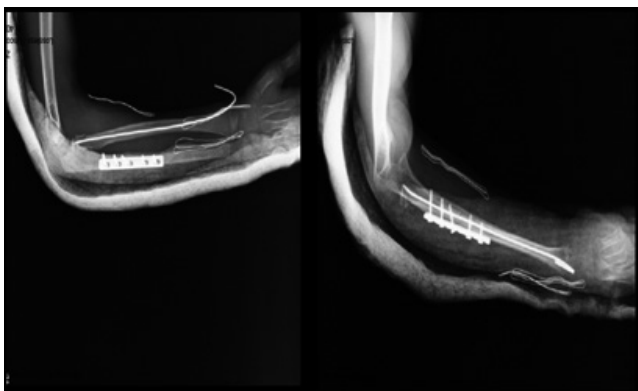
Available online at [www.jemcr.com](http://www.jemcr.com)

**Cite this article as:** Celik M, Arıkan E, Yılmaz OF. An unusual pediatric monteggia equivalent lesion: a rare case report. Journal of Emergency Medicine Case Reports. 2022;13(4): 118-120

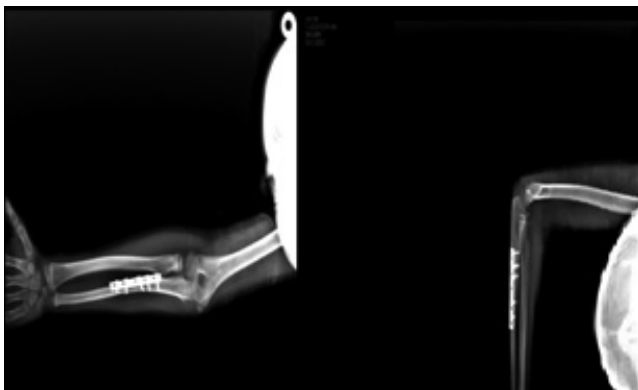

**Figure 1.** Images before surgery

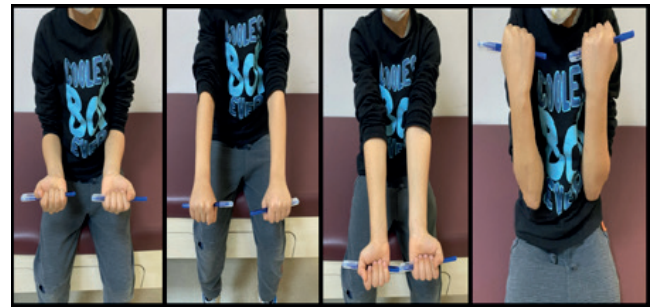Childhood Monteggia fracture-dislocations occur as a result of low-energy trauma, whereas in adults, they occur with high-energy trauma<sup>[4,5]</sup>. Although Monteggia equivalent injuries are mentioned in the literature, associated ipsilateral radial neck fractures are rare. The mechanism of injury for these types of fractures occurring at two different levels has not been fully resolved. As the post-traumatic force acts on the elbow in the axial direction, a varus rotational force is activated, which may be responsible for the Monteggia lesion. The direction of the rotational force causes different Monteggia fractures<sup>[3]</sup>. In children, the looser annular ligament makes the Monteggia-equivalent lesions we have presented extremely rare<sup>[6,7]</sup>



**Figure 2.** Postoperative images



**Figure 3.** Follow-up images



**Figure 4.** Functional results at the 1-year follow-up

Bado suggested that Monteggia type I and equivalent lesions can be treated by closed reduction with a supination maneuver. In a type I equivalent lesion, if the ulna or proximal radius fracture is unstable, intramedullary fixation should be made with a Kirschner wire<sup>[1]</sup>.

Evans et al observed the injury pattern and suggested that the soft tissue component may be responsible<sup>[8]</sup>. He emphasized that when a person falls on his elbow in extension, the sudden and strong contraction of the biceps muscle will cause the radial head to come forward. Also, fracture of the ulna occurs as a result of contraction of both the interosseous membrane and the musculus brachialis<sup>[9]</sup>.

In most cases, the radial head is spontaneously reduced after the ulna is anatomically reduced and fixed. Incorrect and inadequate reduction of the ulna can make reduction difficult and cause permanent dislocation of the radial head. If the radial head is dislocated after ulna reduction and fixation, the ligamentous structures of the radial head should be checked or interposition of the posterior interosseous nerve should be considered. In such cases, it can be intervened with a lateral approach<sup>[10]</sup>. If the fracture structure is short-oblique or transverse, it can be fixed with intramedullary nailing; however, if the fracture structure is long segmented or fragmented, fixation with plate-screw may be required<sup>[11,12]</sup>. The looser annular ligament in children makes Monteggia equivalent lesions less common<sup>[13]</sup>. In the cases presented similarly in the literature, good results were reported in the treatment and follow-up, as in our case.

## Conclusion

There are many variations of Monteggia equivalent lesions. In conclusion, the combination of ulna shaft and displaced radius neck fracture is a rare injury. Early diagnosis of these fractures is made by careful examination of the fracture pattern and identification of the injury mechanism. Prompt diagnosis and treatment is imperative to avoid complications. Anatomical fixation of the ulna fracture and stable reduction of the radius head or neck, dislocation or fracture should be provided for good functional outcome. This rare case is presented as a contribution to the literature.

## References

1. Bado, J.L., 7 The Monteggia Lesion. *Clinical Orthopaedics and Related Research* (1976-2007), 1967. **50**: p. 71-86.
2. Josten, C. and S. Freitag, Monteggia and Monteggia-like-lesions: classification, indication, and techniques in operative treatment. *European Journal of Trauma and Emergency Surgery*, 2009. **35**(3): p. 296-304.
3. Peter, N. and S. Myint, Type I Monteggia lesion and associated fracture of the distal radius and ulna metaphysis in a child. *Canadian Journal of Emergency Medicine*, 2007. **9**(5): p. 383-386.
4. Givon, U., et al., Monteggia and Equivalent Lesions: A Study of 41 Cases. *Clinical Orthopaedics and Related Research* (1976-2007), 1997. **337**: p. 208-215.
5. Letts, M., R. Loch, and J. Wiens, Monteggia fracture-dislocations in children. *The Journal of Bone and Joint Surgery. British volume*, 1985. **67**(5): p. 724-727.
6. Faundez, A., D. Ceroni, and A. Kaelin, An unusual Monteggia type-I equivalent fracture in a child. *JOURNAL OF BONE AND JOINT SURGERY-BRITISH VOLUME-*, 2003. **85**(4): p. 584-587.
7. Soin, B., N. Hunt, and J. Hollingdale, An unusual forearm fracture in a child suggesting a mechanism for the Monteggia injury. *Injury*, 1995. **6**(26): p. 407-408.
8. EM, E., Pronation injuries of the forearm, with special reference to the anterior Monteggia fracture. *The Journal of Bone and Joint surgery. British Volume*, 1949. **31**(4): p. 578-88, illust.
9. Tompkins, D.G., The anterior Monteggia fracture: observations on etiology and treatment. *JBJS*, 1971. **53**(6): p. 1109-1114.
10. Ring, D., Monteggia fractures. *Orthopedic Clinics*, 2013. **44**(1): p. 59-66.
11. Trail, I., *Operative elbow surgery*. 2011: Churchill Livingstone.
12. Bae, D.S. and P.M. Waters, Surgical treatment of acute and chronic Monteggia fracture-dislocations. *Operative Techniques in Orthopaedics*, 2005. **15**(4): p. 308-314.
13. Singh, D., et al., A very rare presentation of type 1 Monteggia equivalent fracture with ipsilateral fracture of distal forearm-approach with outcome: case report. *Journal of Orthopaedic Case Reports*, 2016. **6**(4): p. 57.