

RETROSPECTIVE EVALUATION OF HENOCH SCHONLEIN PURPURA CASES*

**Nurdan Erol, M.D. / Aysu Türkmen, M.D. / Can Erzik, M.D.
Ahmet Özgüner, M.D. / Serpil Yavrucu, M.D.**

Clinic of Pediatrics, Haydarpaşa Government Hospital, Istanbul, Turkey

ABSTRACT

Objective: Henoch Schönlein Purpura (HSP) is the most common benign vasculitis occurring during childhood. Morbidity and mortality rates rise when there is organ system involvement. We aimed to retrospectively evaluate HSP cases in our clinic according to organ involvement, clinical and laboratory findings.

Material and Methods: Twenty-eight HSP cases were followed in our clinic from January 1st 1997 to June 1st 2000. The cases were retrospectively evaluated.

Results: The mean age of the patients was 7.96 years (interval: 3-14 yrs.). 17 of them were males, 11 were females. The mean hospitalization period was 6,36 days (interval: 1-16 days). Two patients had been hospitalized twice due to recurrence and two others had each been hospitalized once before in another clinic due to the same disease. 9 patients (32.1 %) had a history of an upper respiratory tract infection (URTI) of whom 3 (10.7 %) had positive throat cultures for beta hemolytic streptococcus. Skin lesions were seen in all patients. Arthritis/arthralgia developed in 12 (42.9 %) patients. Gastrointestinal system tract (GIT)

involvement developed in 19 patients (67.9 %), 7 (25 %) of them presented with abdominal pain and vomiting, 12 (42.9 %) with occult fetal blood. In 4 patients (14.3 %) with GIT involvement, hematochezia and melena developed later. Abdominal ultrasonography was performed on 17 cases (60.7 %). No surgical intervention was required for any of the patients. 11 patients (39,3 %) had renal involvement. In 8 of the cases (28,6 %) renal disease presented with microscopic hematuria with or without proteinuria and in the other 3 (10,7 %) with macroscopic hematuria. In 1 (3,6 %) case acute renal failure developed and hemodialysis was performed. Central nervous system (CNS) involvement occurred in one patient (3,6 %) who had convulsions. In 2 cases (7,1%) scrotal involvement was observed. 13 patients were given steroids.

Conclusions: In HSP cases, renal and GIT involvement should be searched for meticulously and patients with renal involvement should be followed up regularly.

Key Words: Henoch Schönlein Purpura, HSP nephritis, Vasculitis, Gastrointestinal bleeding.

* This article was presented as a poster at 44th National Pediatrics Congress, September 2000, Bursa, Turkey.

INTRODUCTION

Henoch Schönlein Purpura (HSP) is the most common vasculitis in childhood. It is characterized by non-thrombocytopenic purpura, arthritis/arthralgia, abdominal pain, gastrointestinal bleeding and glomerulonephritis (1,2).

Although it is known as a benign vasculitis, morbidity and mortality increase when there is organ system involvement. It is important to follow a patient with renal, GIT and CNS involvement regularly. This study was performed to evaluate retrospectively the HSP patients hospitalized in our clinic within a certain period.

MATERIALS AND METHODS

Patients diagnosed as and treated for HSP between January 1st 1997 and June 1st 2000 and later followed up in the outpatient clinic were chosen for the study. The number of patients was 28 (17 males, 11 females). Records of their age, sex, medical history, hospitalization period, number of recurrence episodes, clinical findings, laboratory tests, radiological and histopathological findings were taken and analyzed in the light of literature.

RESULTS

The age and sex distribution of the cases are presented in Table-I.

Table I.: The age and sex distribution of the cases

	Male	Female
Number	17	11
Age Range (Yr)	3-13	3-14
Mean Age (Yr)	7.76	8.27

Male / female ratio was 1,5 / 1. The youngest patient was 3, the eldest was 14 years of age. The overall mean age was 7.96.

Distribution of the cases according to months and years is given in Table-II.

Table II.: Distribution of cases according to months and years.

Months/Years	1997	1998	1999	2000
January	1	1	2	-
February	-	1	-	-
March	2	-	-	-
April	1	1	1	3
May	-	-	4	-
June	-	-	-	-
July	-	-	1	-
August	1	-	1	-
September	1	-	-	-
October	4	1	-	-
November	2	-	-	-
December	-	-	-	-
Total	12	4	9	3

The hospitalization period varied between 1 to 16 days (mean: 6,36 days). Two patients were hospitalized twice in our clinic due to recurrence and 2 others were each hospitalized once before in different clinics.

The medical histories revealed upper respiratory infections in 9 patients (32.1 %), of whom 3 (10.7 %) had positive throat cultures for beta hemolytic streptococcus; one had otitis media (3,6 %), one had urinary tract infection (3.6 %), and one had bronchopneumonia (3.6 %). 2 patients had a history of acetyl salicylic acid (80 mg) use, 1 had furosemide intoxication, and 1 patient a recent trauma history.

Non-specific findings were as follows: fever between 38.0-38.5° C in 5 cases (17.9 %). Between 37.5-37.9° C in 7 patients (25.0 %), less than 37.0° C in 16 (57.1 %); hypertension in 4 patients (14,3 %). The findings are given in Table-III.

Table III.: The clinical findings and organ involvements of the cases.

Clinical Findings	Number of Cases	Percentage (%)
Purpura	28	100.0
Arthralgia / Arthritis	12	42.9
Gastrointestinal System Involvement	19	67.9
Renal Involvement	11	39.3
Scrotal Involvement	2	7.1
CNS Involvement	1	3.6

Purpuric skin lesions were seen in all patients (100.0%). In some patients they occurred after arthralgia/arthrititis and in some following abdominal pain and/or vomiting.

Arthralgia/arthrititis was found in 12 cases (42.9 %). The most involved joints were ankles and knees. In 1 patient (3.6 %) elbow pain was recorded.

Data relating to GIT and renal involvement is given in Table-IV:

In 19 cases (67.9 %) there was GIT involvement. In 7 of them (25.0 %) presentation was with abdominal pain and vomiting. 12 patients (42.9 %) had occult fecal blood in addition to abdominal pain. In 4 of them (14.3 %) hematochezia and melena developed.

Renal involvement was evident in 11 cases (39.3 %). 8 of them (28.6 %) also had GIT involvement. 8 of the patients with renal disease (28,6 %) presented with microscopic hematuria with or without proteinuria and the other 3 (10,7 %) with macroscopic hematuria. In 1 (3.6 %) case acute renal failure developed and hemodialysis was performed. CNS involvement occurred in 1 patient (3,6 %) presenting with convulsions. The only finding in cerebro-spinal fluid was xanthochromia. EEG did not reveal any specific findings for epilepsy.

Two patients (7.1 %) had scrotal involvement. One of them was diagnosed as having orchio-epididymitis by ultrasonography. The other, who had had an orchiectomy before due to abdominal orchiopexy, was found to suffer only from testicular pain.

Complete blood count results are given in Table -V:

Table IV.: Gastrointestinal and renal involvement

Gastrointestinal Involvement		Renal Involvement		Gastrointestinal + Renal Involvement				
	Number	%		Number	%	Number	%	
Abdominal Pain and Vomiting	7	25.0	Mic.Hematuria±Proteinuria	8	28.6	Gastrointestinal and Renal Involvement	8	28.6
Occult Fecal Blood	12	42.9	Mac. Hematuria	3	10.7			
Melena+Hematochezia	4	14.3	Acute Renal Failure	1	3.6			

Table V.: Complete blood count results.

	Ranges	Mean and SD
Hemoglobin	5.6-14.5g/dl	11.98g/dl±1.91
Hematocrite	16-43 %	35.94 %±5.93
Erythrocyte	3.7-5.3 million/mm ³	4.62 million/mm ³ ±0.45
Leukocyte	5600-21000/mm ³	12600/mm ³ ±3563
Thrombocyte	219000-572000/mm	389153/mm ³ ±123754
Sedimentation Rate	12-120 mm/h	44.25 mm/h±29.40

C3/C4 were measured in 9 cases. C3 was found to be lowered in 1 patient and increased in 2 patients. C4 was normal in all cases.

Bronchopulmonary infiltration was observed on the chest X-ray of 1 patient.

On 17 patients ultrasonography (USG) was taken. In 11 patients no pathological findings were found. In 1 patient (3.6 %) bowel dilatation and in 2 patients (7.1 %) suspected invagination with fluid collection was observed. In the control USG analyses the findings returned to normal. No patient required surgical intervention.

Two patients (7.1 %) were found to have grade 1-2 increases in renal echogenicity. In 1 patient (3.6 %) minimal fluid collection in the right pleural space was observed.

Seven patients required skin biopsies to ascertain the diagnosis after the consultation with the Dermatology Clinic. All the biopsy results were congenial with leucocytoclastic vasculitis.

Renal biopsies were taken in 2 patients with acute renal failure and massive proteinuria. The findings were typical of HSP nephritis with crescent formation.

Thirteen cases (46.4 %) were treated with steroids. Steroids were given in a dose of 1-2 mg/kg/day for 3-14 days to patients with GIT involvement. Patients having undergone renal biopsy were treated with a dose of 30 mg/kg/day for the first 5 days and then with 1 mg/kg/day for the next month after consultation with the Pediatric Nephrology Department of the Istanbul School of Medicine.

Of the 28 patients only 6 regularly attended follow-up visits in the outpatient clinic. Therefore no reliable data could be obtained for the long term period.

DISCUSSION

HSP is a leukoclastic vasculitis according to the Chapel Hill classification (1993) and is the most common vasculitis of the childhood period (3). Its incidence is about 13.5-18.0 / 100.000 (1-3). Although it can occur at any age after the first 4-6 months of life, 50 % are seen at under 5, and 75 % are seen at under 10 years of age. The youngest of our cases was 3, and the oldest was 14 years of age. The disease is more common in males where the male/female ratio in the literature is reported to be around 1.2/1 - 2.6/1 (1,2,4). The ratio in our series was 1.5 / 1 and was similar to the study of Dicle University Medical School (4).

HSP is a disease which recurs. It recurs mostly within the first 3-4 months of the first attack, or sometimes in a year or rarely in a few years (1,2). Four patients in our study had to be hospitalized twice because of recurrence and complications of HSP.

Although the etiology is unknown, an upper respiratory infection due to streptococci is thought to be the cause. The disease is mostly seen in winter and autumn (2). But in our cases there was no significant tendency of distribution in a specific season. Also adenovirus, mycoplasma and parvovirus infections are seen among the causes of the disease, and the pseudomonas which are accepted as another triggering factor (5). In one of our recurrent cases with GIT and renal involvement the urine culture was positive for pseudomonas aeruginosa. Trauma, some drugs and vaccines are also seen

among the causative factors (2,6). Nine of our patients had URTI, where 3 had positive throat cultures, and three had other infections. One patient had been hospitalized due to furosemide intoxication and two had a history of being treated with 80 milligrams salicylic acid the week before the HSP symptoms occurred. Another patient had a trauma history of an arm fracture.

Among the clinical findings of HSP the purpuric and / or petechial skin lesions involving mostly the buttocks and legs and sometimes the arms and face are almost always seen (7-10). One of the diagnostic criteria by the American College of Rheumatology (1990) is leukoclastic vasculitis with polymorphonuclear leukocytes at small vessel walls (2). All of our patients had these lesions. However, when there is organ system involvement other than skin beforehand, it can be difficult to make a diagnosis. Histologically, changes occur in the arterioles, capillaries and venules due to IgA, C₃ and fibrin deposition. Complement abnormalities (like C₂ deficiency, homozygote null C₄ phenotype, C₄B deficiency) are held to be responsible for IgA deposition (2). In recent studies the abnormal glycosylation of IgA subclass A₁ has been given a main role in pathogenesis (8,11). Skin biopsies were performed on 7 of our cases. In one of them the skin lesions were pruritic. In another patient the lesions started as purpura and then turned to ecchymoses. All of the results were congenial with vasculitis. To differentiate HSP from other vasculitic diseases IgA ANCA can be measured (1,12).

Arthralgia or arthritis is more frequently seen at the knees, ankles and elbows. The rate of occurrence is between 60-84 % (6-8). Arthritis or arthralgia was positive in 12 (42.9 %) of our patients. In some cases arthritis preceded skin lesions.

Gastrointestinal system involvement is about 50-80 % (1-4, 6-9). In half of the cases occult fecal blood is present (1). The clinical findings include abdominal pain, vomiting, hematemesis, melena. (7, 13). Rarely intussusception, bowel perforation, pancreatitis, appendicitis or hydropic gall bladder can occur. The rate of such a major complication is 4,6 % (1.3 - 13.6) (13). GIT involvement occurred in 19 (67,9%) of our patients. 12 (42.9%) patients had occult fecal

blood. In 4 patients (14.3 %) rectal bleeding was apparent. None of the cases required surgical intervention. During the control ultrasonographic analysis, cases with suspected invagination were found to have recovered. Ultrasonography is not always sufficient to show GIT involvement but it is useful in following cases with suspected invagination and bowel dilatation (13).

Renal involvement is reported to occur in between 20 and 100 % of the cases (2). In 89 % of the cases it becomes evident in the first 4 weeks, although in the rest it can take more than 2 months. Renal involvement is more common in patients with GIT involvement (4). 11 of our cases (39.3 %) had renal disease where 8 of them (28.6 %) had it together with GIT disease. The clinical presentation is mostly as microscopic hematuria +/- with or without proteinuria. In 3 patients we observed macroscopic hematuria, with a decrease in glomerular filtration rate. One patient needed to undergo hemodialysis because of acute renal failure.

Since renal involvement can be a serious challenge during hospitalization or in the follow-up period some methods of monitoring have been suggested like measuring the tubular proteins N-acetyl beta-D-glucosaminidase (NAG) and alpha-1-microglobulin (a 1 MG) (14).

Renal findings include primary lesion, and endocapillary proliferative glomerulonephritis involving the endothelial and mesangial cells. Extracapillary cells can cause crescent formation. With immunofluorescence deposits of IgA, IgG, C₃ and fibrin can be noticed (2). Renal biopsies were performed in 2 of our patients revealing findings of HSP nephritis including crescent formation.

Central nervous system involvement presents with convulsions, paresis and coma. It is not common (1,2). One patient of our series had convulsions during the hospitalization period.

Scrotal involvement is reported not to be uncommon, and it sometimes presents as testicular torsion (1,2). A study reported that 15 % of affected boys complained of significant pain. Ultrasonographic findings include dilated and torsioned epididym, scrotal thickening, hydrocele

without involvement of testicles (15). We had scrotal involvement in 2 cases.

The other findings of HSP are due to very rarely seen cholecystitis, myocardial infarction and interstitial lung disease (2, 16). A patient in our clinic had bronchopulmonary infiltration but it has not been possible to ascertain whether it was due to HSP or not.

There are no specific laboratory findings for HSP. Thrombocytosis may be related with the severity of disease increased Von Willebrand factor and serum thrombomodulin levels which show endothelial damage. In severe GIT involvement factor XIII may increase. In 50% of cases serum IgA levels have been reported to be higher than normal. IgA nephropathy and HSP are diseases with similar renal findings. They can be found within the same family. Therefore the ACE gene deletion found in IgA nephropathy patients was searched for also in HSP cases but no significant relation was found (17). Complement levels may be normal or increased. The mechanism for increased complement in renal disease was thought to be associated with lectin levels (18). No specific laboratory findings were present in our cases.

In treatment, steroid use relieves the complaints of GIT involvement rapidly but is not effective in preventing renal disease (19,20). In serious renal involvement pulse steroid treatment alone or with immunosuppressants is suggested (1,21). In our clinic, cases with GIT disease were treated with 1-2 mg/kg/day steroids whereas 2 patients who had renal biopsy were given pulse treatment.

Only a small part of our patients came to regular follow-up visits due to economic and educational problems and because some of them were living in other towns. In the dialysis patient the low GFR rate continued for a while. In the other patient with macroscopic hematuria the purpura recurred once while the GFR returned to normal. The rest had no further problems.

Although it is a benign disease, the morbidity and mortality of HSP increases with multiorgan involvement. Special attention must be paid to complications in cases of gastrointestinal, renal and central nervous system involvement. End stage renal failure has been reported to develop

in 5-15% of cases with renal involvement. It has been reported to occur more frequently especially in cases with glomerular filtration rate below 70 ml/min., 1 gr. of protein excretion in urine and sclerotic crescent formation. In renal transplant patients, HSP nephritis can recur (19). Therefore long term follow up is recommended for all who develop nephritis.

REFERENCES

1. Behrman RE, Robert MK, Waldo EN, Victor CV. *Nelson Textbook of Pediatrics*. 16th Edition. Philadelphia: PW.B. Saunders Co., 2000:628-629.
2. Tizard EJ. Henoch-Schönlein purpura. *Arch Dis Child* 1999;80:380-383.
3. Watts RA, Scott DGI. Vasculitis. *Baillière's Clin Rheumatol* 1995;9:529-545.
4. Ece A, Gürkan F, Haspolat K, Katar S. Henoch-Schönlein purpuralı çocuklarda renal ve gastrointestinal tutulum. *Çocuk Sağ ve Hast Der (Hacettepe)* 2000;43:36-42.
5. Egan CA, Oreilly MA, Meadows KP, Zone JJ. Relapsing Henoch-Schönlein purpura associated with *Pseudomonas aeruginosa* pyelonephritis. *J Am Acad Dermatol* 2000;42:Pt2:381-383.
6. Kraft DM, Mckee D, Scott C. Henoch-Schönlein purpura: a review. *Am Fam Physician* 1998;58:405-411.
7. Mat C, Yurdakul S, Tüzüner N, Tüzün Y. Vasculitis. *Baillière's Clin Rheumatol*, 1997;11:244-246.
8. Saulsbury FT. Henoch-Schonlein purpura in children: report of 100 patient literature. *Medicine (Baltimore)* 1999;78:395-409.
9. Kumar L, Singh S, Goraya JS, et al. Henoch-Schönlein purpura: the Chandigarh experience. *Indian Pediatr* 1998;35:19-25.
10. Blanco R, Martinez TVM, Rodriquez VV, et al. Henoch-Shönlein purpura in adulthood and childhood: two different expressions of the same syndrome. *Arthritis Rheum* 1997;40:859-864.
11. Saulsbury FT. Henoch-Schönlein purpura. *Curr Opin Rheum* 2001;13:35-40.
12. Rovel-Guitera P, Diemert MC, Charuel JL, et al. IgA antineutrophil cytoplasmic antibodies in cutaneous vasculitis. *Br J Dermatol* 2000;143:99-103.
13. Choong CK, Beasley SW. Intraabdominal manifestations of Henoch-Schonlein purpura. *J Paediatr Child Health* 1998;34:405-409.
14. Muller D, Greve D, Eggert P. Early tubular proteinuria and the development of nephritis in Henoch-Schönlein purpura. *Pediatr Nephrol* 2000;15:85-89.
15. Ben-Sira L, Laor T. Severe scrotal pain in boys with Henoch-Schonlein purpura: incidence and sonography. *Pediatr Radiol* 2000;30:125-128.
16. Agraharkar M, Gokhale S, Le L, et al. Cardiopulmonary manifestations of Henoch-Schönlein purpura. *Am J Kidney Dis* 2000;35:319-322.
17. Dudley J, Afifi E, Gardner A, et al. Polymorphism of the ACE gene in Henoch-Schönlein purpura nephritis. *Pediatr Nephrol* 2000;14:218-220.
18. Endo M, Ohi H, Ohsawa I, et al. Complement activation through the lectin pathway in patients with Henoch-Schönlein purpura nephritis. *Am J Kidney Dis* 2000;35:401-407.
19. Goldstein AR, White RHR, Akuse R, Chantler C. Long-term follow-up of childhood Henoch-Schönlein nephritis. *The Lancet* 1992;339:280-282.
20. Reinehr T, Burk G, Berger T, et al. Steroids for prophylaxis of nephropathy in Schnlein Henoch purpura? Follow-up of 171 patients (Abstract). *Klin Pediatr* 2000;212:99-102.
21. Foster BJ, Bernard C, Drummond KN, Sharma AK. Effective therapy for severe Henoch-Schönlein purpura nephritis with prednisolone and azathioprine: a clinical and histopathological study. *J Pediatr* 2000;136:370-375.

XENICAL® orlistat

**KİLO
VERMENİN
ÖTESİNDE...
YENİ BİR
YAŞAM**

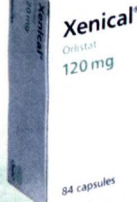**OBEZİTENİN UZUN SÜRELİ
TEDAVİSİNDE ENDİKEDİR**^{3,4}

**KİLO KAYBININ YANINDA OBEZİTEYE
EŞLİK EDEN RİSK FAKTÖRLERİNİ AZALTIR**^{3,4,5}

İLK LİPAZ İNHİBİTÖRÜDÜR^{1,2,3,4,6}

**SİSTEMİK ETKİLİ OLMAYAN
TEK ANTIÖBEZİTE İLACIDIR**^{2,6}

**SPEŞİFİK YAĞ
BLOKERİDİR**^{2,3,4,6}



Beşeri İlaç

Roche Müstahzarları Sanayi A.Ş.
P.K. 16-80622 Levent-İstanbul
www.xenical.com.tr

Referanslar:
1) Hill JO, Heegeman J, Anderson JW, et al. Orlistat, a lipase inhibitor, for weight maintenance after conventional dieting: a 1-y study. Am J Clin Nutr. 1999; 69: 618-624. 2) Garrow JB. Mode of action of orlistat. Int J Obesity. 1997; 21 Suppl 3: S12-23. 3) Davidson MH, Heegeman J, DiGirolamo M, et al. Weight control and risk factor reduction in obese subjects treated for 2 years with orlistat. JAMA. 1999; 281: 235-42. 4) Stenrom L, Rosanen A, Andersson T, et al. Randomised placebo-controlled trial of orlistat for weight loss and prevention of weight regain in obese patients. Lancet. 1998; 352: 167-72. 5) Van Gaal, Brotons JJ, Freni G, et al. Efficacy and tolerability of orlistat in the treatment of obesity: a 6-month dose-ranging study. Eur J Clin Pharmacol. 1998; 54: 123-32. 6) Strayer TL. Medical Hazards of obesity. Ann Intern Med. 1992; 117: 955-60.

XENICAL® Orlistat Kapsül Lokal etkili anti-öbezite ilacıdır.
Endokrinolojiler (Kullanım Yerdeği). Xenical, obez hastaları veya ağır kilo lu hastaların tedavisinde hafif düşük kalori bir diyetle birlikte etkilidir. Kullanım Şekli ve Dozunu: Xenical'in önerilen dozu her ana öğüne birlikte (yemek sırasında veya en fazla bir saat sonrasında) 120 mg'lık bir kapsüldür. Kontrollü-kavayarak (Kullanılmaması Gereken Yerdeği). Xenical kronik malabsorpsiyon sendromu olan hastalarda, kolitiazis oluşturmada, orlistat veya kapsüle bulunan diğer maddelerden herhangi birine ağır duyarlılığı olan kişilerde kontrendikedir. Yan Etkiler/Advers Etkiler (İstemsiz Yan Etkiler): Xenical'in advers reaksiyonları genellikle gastrointestinal sistemle ilgili ve iktid, benzerleri alınan yağın emilimini engelleyen bazı farmakolojik etki ile ilişkilidir. Sık görülen advers etkiler, yağlı dışkı, gaz, bulantı, şişkinlik, anoreksi, mide ağrısı, yağlı dışkı, alkolün emilimini azaltması, diyetle ilgili olarak artıp ve azalmasıdır. Yağ içeriği düşük bir diyet, gastrointestinal advers olayların ortaya çıkma olasılığını azaltacaktır; bu durum hastaların yağ almasını önlemelerine ve diyetle ilgili yan etkilerden kaçınmalarına yardımcı olabilir. Uyarılar/Özellikler: Tip 2 diyabet hastalarında, Xenical ile sağlanan kilo kaybı, metaboliik kontrolde de düzenliye etmiş olsa da, bu durum oral hipoglisemik ilaçları (örn. Sülfonilüreler) dozunun azaltılması olarak sağlayabilir ya da azaltılmaması gerektirebilir. Aşırı güçlü yağ ve tuzlu öğünler bölünmez. Xenical çok fazla yağ içeriği birlikte alındığında, gastrointestinal yan etkiler artırabilir. İlaç Etkileşimleri: Farmakokinetik çalışmalar arasında alkol, digoksin, nifedipin, oral kontraseptifler, feotrin, prazosin veya varfarin ile etkileşim gözlemlenmiştir. Saklama koşulu: Nemi koruyunuz, 25 °C'nin üstünde kesinlikle saklamayınız. Ticari Şekli: Xenical kapsül, 84 adet, blisterde. Ruhsat Sahibi ve Adresi: Roche Müstahzarları Sanayi Anonim Şirketi, Levent, İstanbul. Üretim Yeri: F. Hoffmann-L. Roche Ltd., Basel, İsviçre. Ruhsat Tarihi ve Numarası: 28.7.1999/106/84. Perakende Satış Fiyatı (Çekir. 2001 itibarıyla): KDV dahil, 55.47.000 TL. Daha detaylı bilgi firmamızdan temin edilebilir. Reçete ile satılır.

Sağlıklı bir yaşam için...



Novartis, yaptığı arařtırmalar
ve geliřtirdiđi ürünlerle
sađlıklı bir yaşam için
sizlerle birlikte...

 NOVARTIS

Günde Kere Yalnızca Gram



Alt solunum yolu infeksiyonları

Bakteriyel menenjit

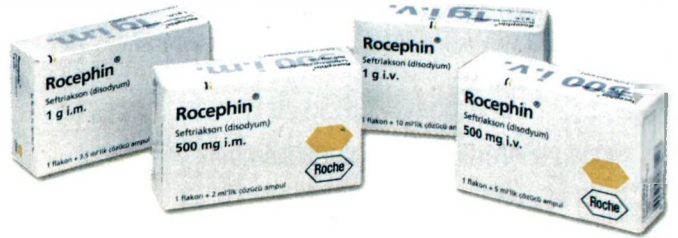Üriner sistem infeksiyonları

Deri ve yumuşak doku infeksiyonları

Kemik ve eklem infeksiyonları

Intraabdominal infeksiyonlar

Cerrahi profilaksi



Orijinal seftriakson
Rocephin®

Seftriakson (disodyum)


Bileşim: Seftriakson. **Özellikleri:** Seftriakson geniş spektrumlu, Gram(-) ve Gram (+) bakterilerin büyük kısmına bakterisid etkili, uzun yarılanma ömrü 3. jenerasyon sefalosporindir. **Endikasyonlar:** Duyarlı patojenlerin neden olduğu abdominal, kemik-eklem-cilt ve yumuşak doku, ürogenital sistem, solunum sistemi infeksiyonları; immün yetmezliklerde gelişen infeksiyonlar, sepsis, menenjit, cerrahi profilaksi. **Doz ve Uygulama:** Genel olarak 24 saatte bir 1-2 g (yeni doğanlar: 20-50 mg/kg/gün) maksimum 4 g/gün, tek dozda parenteral olarak uygulanır. **Kontraindikasyonlar:** Sefalosporin duyarlılığı. **Uyarılar:** Penisilinler ile çapraz alerjik reaksiyon görülebilir. Kesin endikasyon olmadıkça gebelikte kullanılmamalıdır. **Yan Etkiler:** Genellikle iyi tolere edilir. Geçici yan etkilere rastlanabilir. **Ticari Şekiller:** Parenteral uygulama için 0.5 g i.m., 0.5 g i.v., 1 g i.m., 1 g i.v. flakon. Reçete ile satılır. Şubat 2001/KDV Dahil Per. Sat. Fi. 0.5 g i.m.-i.v. 5.374.000 TL., 1 g i.m.-i.v. 9.414.000 TL. Daha detaylı bilgi firmamızdan temin edilebilir. © Tescilli Marka.



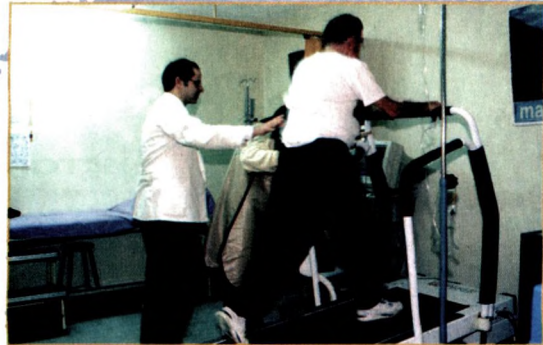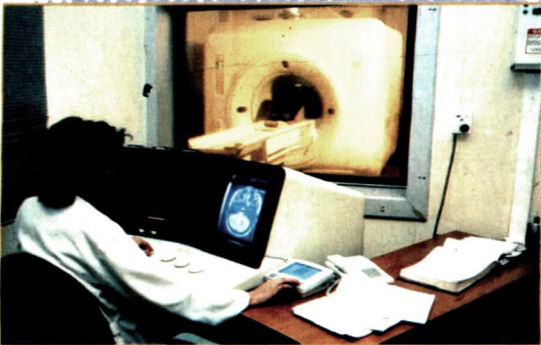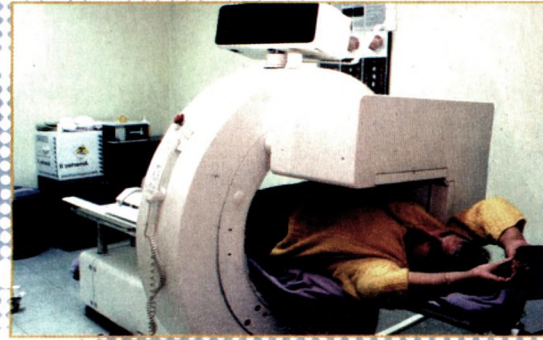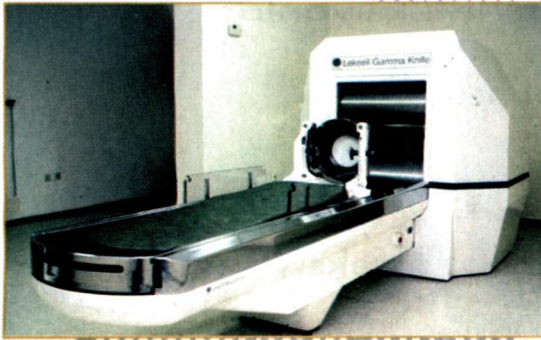Beşeri İlaç

Roche Müstahzarları Sanayi A.Ş.
P.K. 16-80622 Levent-İstanbul.
<http://www.roche.com.tr>

GE Medical Systems - Marmara Üniversitesi İşbirliğiyle



Ülkemizin en kapsamlı ve modern Teşhis/Tedavi Merkezi



GAMMA KNİFE

(Türkiye ve çevre ülkelerde ilk ve tek)
Beyin Patolojilerinde cerrahi
müdahaleye gerek kalmaksızın
tedavi olanağı

Radyasyon Onkolojisi

Satum 42 Lineer Akseleratör
Target Doz Planlama Üniti
Nuclital Simulator

Nükleer Tıp

Camstar X-CT
Camstar X-RT
Optima
Genie Work Stations

Radyodiagnostik

Magnetic Rezonans
Helical Bilgisayarlı
Tomografi
DSA Angiography
Pereferic Angiography
Mammografi
Floroscopy
Konvansiyonel X-Ray
Mobile X-Ray
Ultrasonografi
Doppler Ultrasonografi
Advantage Windows
(Görüntü Değerlendirme Sistemleri)

Bugün de, yarın da,
her ihtiyacım olduğunda...



Solunum yolları infeksiyonlarında

- Tek molekülde güçlü bakterisid etki
- Tek molekülde yüksek beta-laktamaz stabilitesi
- Geniş spektrum
- Pratik tedavi
- Tedaviye uyum kolaylığı
- Orta kulak sıvısına iyi penetrasyon

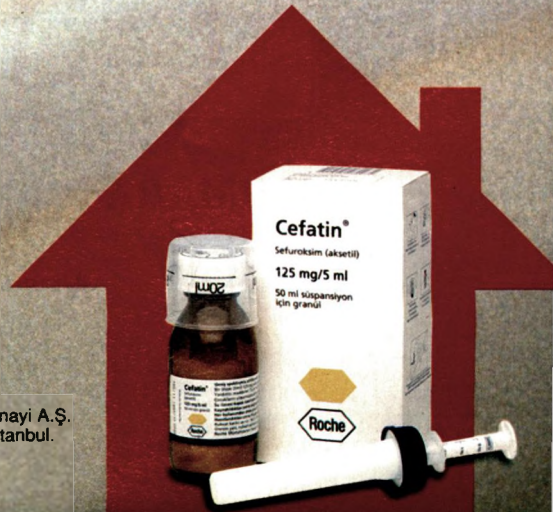 **Cefatin**[®]
Sefuroksim (aksetil)

Bileşimi: Sefuroksim aksetil. **Özellikleri:** Cefatin geniş spektrumlu, bakterisid etkili, beta-laktamazlara dayanıklı oral sefalosporindir. **Endikasyonları:** Duyarlı patojenlerin neden olduğu solunum yolları, ürogenital sistem, cilt ve yumuşak doku infeksiyonları. **Doz ve Uygulama:** Genel olarak günde 2 kez 250 mg uygulanır. Doz 250-1000 mg/gün arasında değişebilir. Çocuklarda genel olarak günde 2 kez 125 mg (2 kez 5 mm'lik 1 ölçek). **Kontraindikasyonları:** Sefalosporin duyarlılığı. **Uyarılar:** Penisilinler ile çapraz alerjik reaksiyon görülebilir. Kesin endikasyon olmadıkça gebelikte kullanılmamalıdır. **Yan Etkileri:** Genellikle iyi tolere edilir. Geçici yan etkilere rastlanabilir. **Ticari Şartları:** 10 adet 125 mg veya 250 mg oral tablet, Süspansiyon 50 ml granül şişede. Reçete ile satılır. Şubat 2001/KDV Dahil Per. Sat. F.: 125 mg tb. 7.680.000 TL, 250 mg tb. 14.109.000 TL, Süspansiyon 10.498.000 TL. Daha detaylı bilgi firmamızdan temin edilebilir. ● Tescilli Marka



Beşeri İlaç

Roche Müstahzarları Sanayi A.Ş.
P.K. 16-80622 Levent-İstanbul.
<http://www.roche.com.tr>





ACADEMIC HOSPITAL

Altunizade Nuhkuyusu Cad. No: 88 Üsküdar Tel.: (0.216) 341 28 41

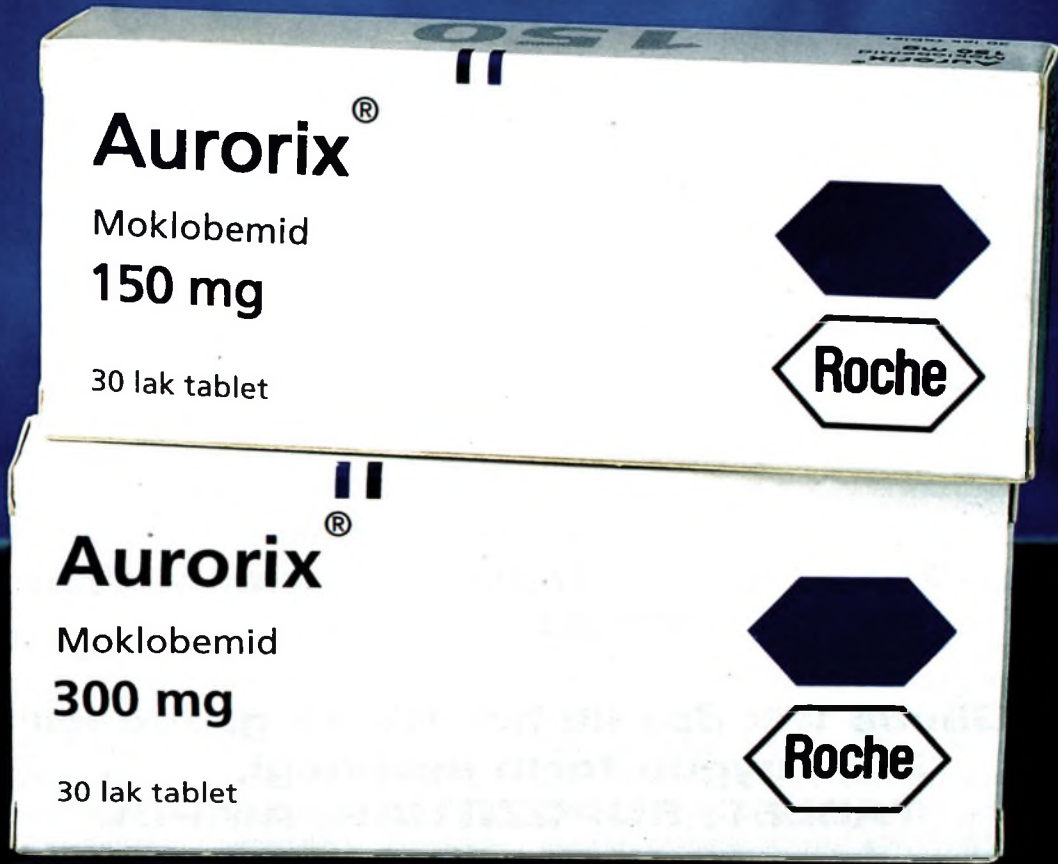


MARMARA ÜNİVERSİTESİ TIP FAKÜLTESİ VAKFI

Academic Hospital

Altunizade Nuhkuyusu Cad. No: 88 Üsküdar
Tel.: (0.216) 492 47 50 Fax: (0.216) 492 47 62

Depresif Sendromlar ve Sosyal Fobi Tedavisinde



AURORIX®
moklobemid

Bileşimi: Moklobemid **Ozellikleri, etkileri:** Moklobemid, A tipi monoaminooksidaz enziminin reversibi inhibitörüdür. Ruhsal durumu düzeltici ve psikomotor aktiviteyi artırıcı etkisinin bir sonucu olarak AURORIX diston, bitkinlik yaşamı isteğinin kaybolması ve dikkati yoğunlaştırma yeteneğinin zayıflaması gibi semptomların giderilmesinde etkili olur. AURORIX sedasyona neden olmaz. AURORIX uyanıklık durumunu bozmay ve iyi tolere edilir. Karaciğer ya da kalbe toksik bir etkisi gözlenmemiştir. **Endikasyonları:** Depresif sendromlar ve sosyal fobi tedavisinde. **Standart Doz:** Depresif sendromlar, Depresyonun şiddetine göre günde 300-600mg iki veya üçe bölünerek verilir. Sosyal fobi: Onarılan doz, iki doza bölünerek verilen 600mg/gündür. **Uyarılar:** AURORIX ilaca karşı aşırı duyarlılığın bildirildiği hallerde ve yeterli klinik deneyim olmamasından dolayı çocuklarda kullanılmamalıdır. Baskın klinik özelliği ajitasyon olan depresif hastalarda AURORIX bir sedatifle birlikte kullanılmalıdır. Yoğun dikkat gerektiren etkinliklerde AURORIX performans bozukluğuna yol açmaz, ancak tedavinin erken dönemindeki tepkilerin sahibin şahısa değişebileceği göz önünde tutulmalıdır. **Gebelikte kullanım:** Genel kural olarak kabul edilen gebeliğin erken döneminde, gerekmedikçe her türlü ilacı kullanmaktan kaçınma ilkesi göz önünde bulundurulmalıdır. **İstisnaysız etkiler:** Plaseboya göre istenmeyen etkilerin sıklığı %5'den fazla değildir. Uykü bozukluğu, sersemlik, bulantı ve baş ağrısı arasına rastlanan etkilerdir. **Etkileşimler:** Simetidin moklobemid'in metabolizmasını uzatır. Moklobemid alkolle etkileşime girmez. **Aşırı doz:** Aşırı doz tedavisi öncelikle vital fonksiyonların sürdürülmesini hedeflemelidir. **Ticari şekli:** 150 mg, 300 mg, 30 adet blisterde. Ocak 2001-KDV Dahil Per Sat Fiy. 150mg 14.310.000 TL, 300mg 22.957.000 TL. Reçete ile satılır. Daha detaylı bilgi firmamızdan sağlanabilir. © "Tescilli Marka" Roche Mustazharları Sanayi A.Ş. P.K. 16-80622 Levent-İstanbul. <http://www.roche.com.tr>

AĞRI VE ENFLAMASYON TEDAVİSİNDE **ÇOK BOYUTLU** YAKLAŞIM



Tilcotil®
Tenoksikam

**70.996 Hastada
7 yıllık çalışmalarda ispatlanmış⁽¹⁾
GÜVENİLİRLİK**

**Günde tek doz ile her hasta grubu için
uygun form seçeneği,
TABLET, SUPOZİTUAR, AMPUL**

Tilcotil®

(1). R.C.A. Heintz, seven years worldwide experience. VII Euler Symposium, Istanbul, Turkey 8-11 June 1994.



Beşeri İlaç

Roche Müstahzarları Sanayi A.Ş.
P.K. 16-80622 Levent-İstanbul
www.roche.com.tr

Bileşimi: Tenoksikam **Özellikleri:** Antiinflamatuvar, analjezik ve antiromatizmal etki gösterir, trombosit agregasyonunu inhibe eder. **Endikasyonları:** İskelet kas sisteminin ağrılı enflamatuvar ve dejeneratif hastalıklarının semptomatik tedavisinde endikedir. **Doz ve uygulama:** Gut artriti dışındaki tüm endikasyonlar için günde tek doz bir tablet, bir flakon veya bir supozituar. **Kontrendikasyonları:** İlaça aşırı hassasiyeti olanlar; NSAID'lerin kullanılmaması gereken durumlar. **Yan etkiler:** Tilcotil önerilen 20 mg'lık günlük dozlarında genelde çok iyi tolere edilmektedir. Yan etkiler daha çok GI sisteminde meydana gelmektedir. **Ticari Şekiller:** Tablet, 20 mg, 10 ve 30 adet, supozituar 20 mg, 10 adet, flakon 20 mg, 1 adet + 2 ml distile su. **Reçete ile satılır.** Ekim 2000/KDV Dahil Per. Sat. F.: 10 tablet 4.863.000.-TL, 30 tablet 12.083.000.-TL, Ağustos 2000/KDV Dahil Per. Sat. F.: Supozituar 4.425.000.-TL, Haziran 2000/KDV Dahil Per. Sat. F.: Flakon 784.000.-TL. Daha detaylı bilgi firmamızdan temin edilebilir. © "Tescilli Marka"