

## LIPOMA AND INCOMPLETE AGENESIS OF THE CORPUS CALLOSUM ASSOCIATED WITH ARACHNOID CYST LOCATED IN THE TEMPORAL POLE: CASE REPORT

İlhan Elmacı, M.D. / Baha Adam, M.D. / Serdar Özgen, M.D.  
Necmettin Pamir, M.D.

Department of Neurosurgery, School of Medicine, Marmara University, Istanbul, Turkey.

### ABSTRACT

This is a rare case of corpus callosum lipoma appearing with an intracranial arachnoid cyst located in the temporal pole. This case has been incidentally diagnosed by cranial computerized tomography and magnetic resonance imaging.

**Key Words:** Arachnoid cyst, Corpus callosum, Intracranial lipoma, Temporal pole.

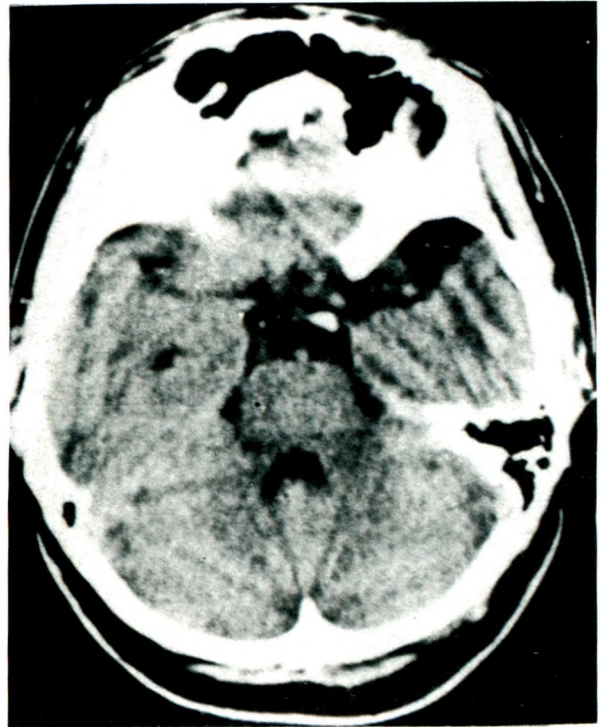
### INTRODUCTION

Lipomas of the corpus callosum are congenital anomalies which frequently appear with midline structural defects such as agenesis of the corpus callosum and spina bifida (1,2). The coexistence of arachnoid cysts with intracranial lipomas is very rare. After a review of the literature only one case was found (3).

### CASE REPORT

A 25-year-old woman admitted to our clinic because of head trauma and complaints of headache and nausea had no neurological

deficit. Computerized tomography (CT) study revealed a hypodense lesion (-17.2 HU) in the region of the left temporal pole (Fig. 1). A

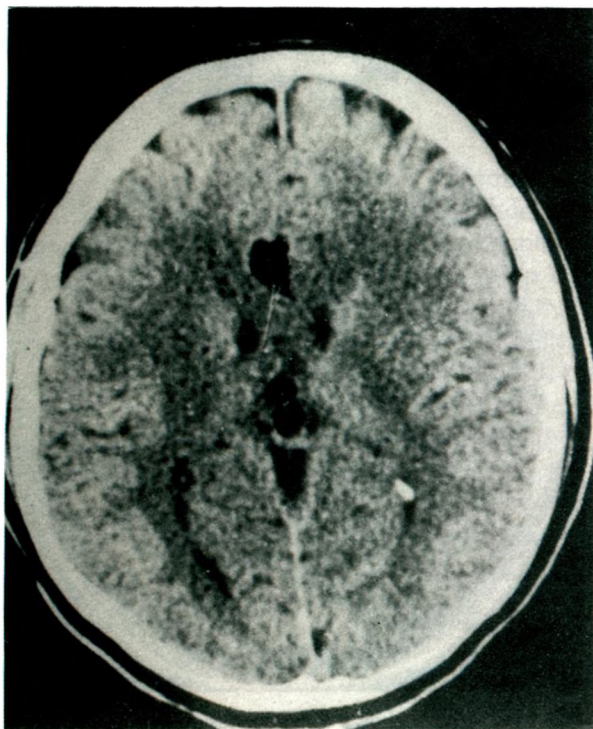


**Fig. 1:** CT scan shows a hypodense region (-17.2 HU) at the left temporal pole.

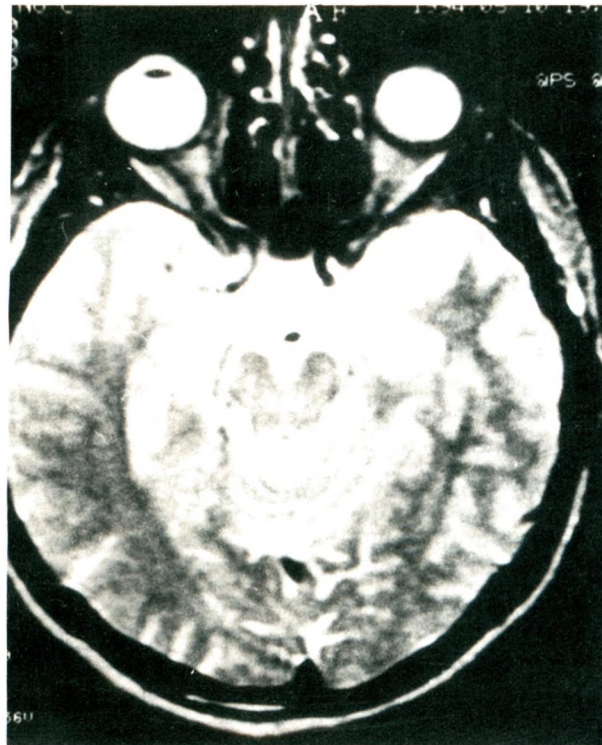
hypodense mass was identified in the genu (-122.1 HU) and in the splenium (-108.6 HU) of the corpus callosum (Fig.2). Magnetic resonance imaging (MRI) was performed on a 0.5 Tesla scanner. The T2-weighted axial images revealed an arachnoid cyst located in the left temporal pole (Fig.3). T1-weighted axial images revealed a right parasagittal pericallosal lipoma at roof level of the lateral ventricle (Fig.4). On T1-weighted coronal images both lesions could be identified simultaneously (Fig.5). The pericallosal lipoma has a curvilinear shape, and an incomplete agenesis of the corpus callosum can be seen on T1-weighted sagittal images (Fig.6). Within 24 hours the patient had no complaints and further treatment was not necessary.

## DISCUSSION

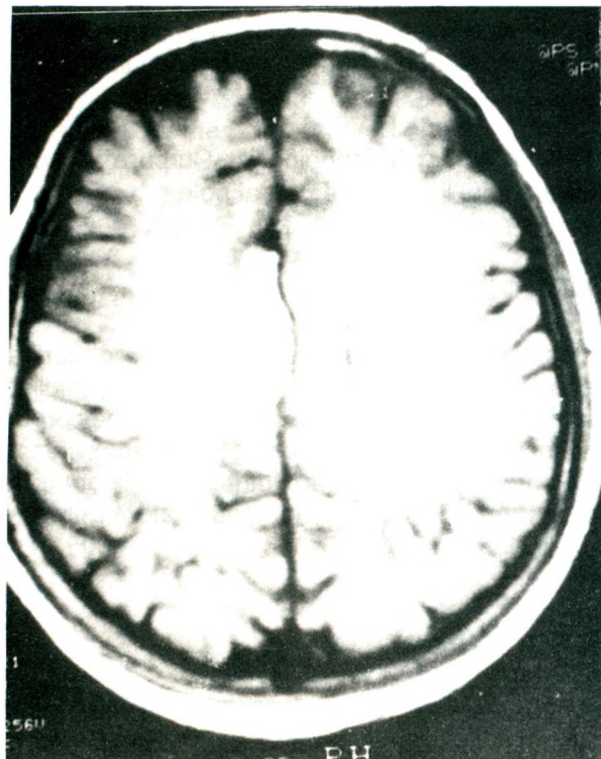
Intracranial lipomas are rare lesions which arise in the midline cerebral cisterns, particularly the callosal cistern and are classified as hamartomatous conditions (4-8). Two main postulated hypotheses concerning intracranial lipoma are an imperfection of the neural tube closure and the faulty differentiation of the



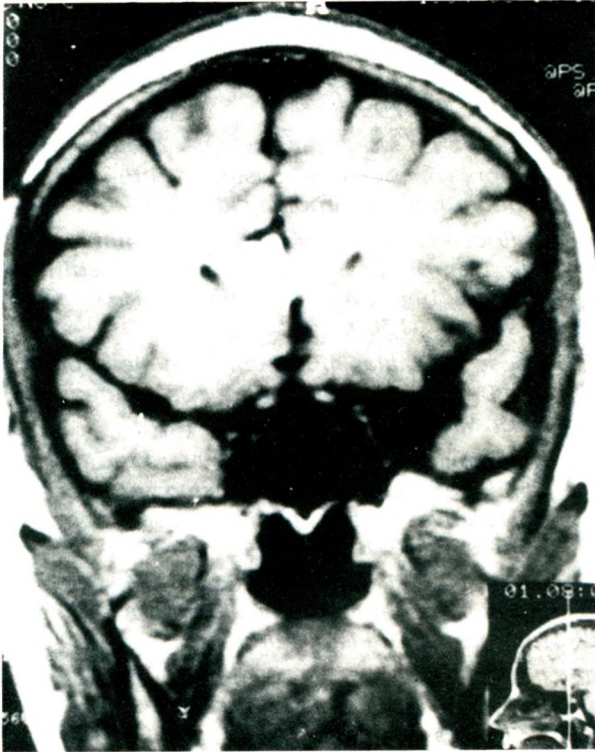**Fig.2:** CT scan demonstrates a hypodense lesion in the genu (-122.1 HU) and splenium (-108.6 HU) of the corpus callosum.



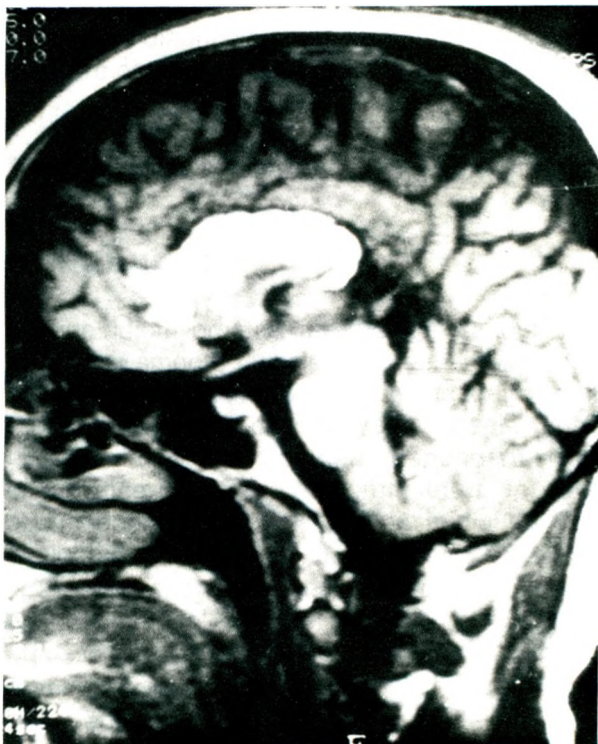
**Fig.3:** T2-weighted MRI shows a lesion of high signal intensity at the left temporal pole.



**Fig.4:** T1-weighted MRI shows a right parasagittal pericallosal lipoma.



**Fig. 5:** T1-weighted MRI shows the arachnoid cyst and the pericallosal lipoma simultaneously.



**Fig. 6:** Midline sagittal MRI shows the curvilinear shape of the lipoma and incomplete agenesis of the corpus callosum.

primitive meninges tissue in the intrahemispheric fissure. Commissuration failure which occurs two weeks after conception can cause agenesis of the corpus callosum and could possibly appear with or without lipoma (7,9,10). Arachnoid cysts are developmental anomalies usually located in the Sylvian fissure. These congenital tumor-like lesions arise during the splitting of the arachnoid membrane (11).

Association of intracranial lipoma with arachnoid cysts was first reported by Rubio et al. The case was a 25-year-old woman who had complained of headaches. MRI showed left temporal arachnoid cyst with a lipoma of corpus callosum. The management of the patient was done conservatively (3).

Both arachnoid cysts and intracranial lipomas can cause symptoms like headache, seizures, and behavioral changes (11-13) and can also cause obstructive hydrocephalus or a mass effect according to their location (13). Sylvian lipomas can also provoke functional psychosis with auditory hallucination (5).

Intracranial lipomas were first noticed in routine postmortem examinations. The premorbid diagnosis of these lesions became possible after the development of CT and MRI and these techniques are now widely used since they provide highly visible images of intracranial lipomas (10,14).

Although CT scan show marginal calcification not seen on MRI, the later technique is the procedure of choice because of the capacity to obtain coronal and sagittal images (1,12). Cranial sonography may be useful for the diagnosis of intracranial lipomas of neonates (15). The reported case of a pericallosal curvilinear lipoma and an incomplete agenesis of corpus callosum appearing with an arachnoid cyst located in the left temporal pole may be of genetic abnormalities which requires further investigation.

## REFERENCES

1. Friedman RB, Segal R, Latchaw RE. Computerized tomography and magnetic resonance imaging of intracranial lipoma. *J Neurosurg* 1986;65:407-410.

2. Atlas SW, Zimmerman RA, Bilanuk LT. Corpus callosum and limbic system: Neuroanatomic MR evaluation of developmental anomalies. *Radiology* 1986;160:355-362.
3. Rubio G, Garcia Guijo C, Mallada JJ. MR and CT diagnosis of intracranial lipoma. *AJR* 1991;157:887-901.
4. Bailey P, Bucy PC. The origin and nature of meningeal tumors. *Am J Cancer* 1931;15:15-54.
5. Dysc P. Sylvian lipoma causing auditory hallucinations: Case report. *Neurosurgery* 1985;16:64-66.
6. Von Rokitansky C. *Lehrbuch der pathologischen Anatomie: Wilhelm Bramüller, Vienna, 1856;2:468-470.*
7. Carmel PW. Brain tumours of disordered embryogenesis. In: Youmans JR, ed. *Neurological Surgery. Third edition. Philadelphia: W.B. Saunders Company, 1990: 3244-3246.*
8. Hatashita S, Skahibara T, Ishii S. Lipoma of the insula. Case report. *J Neurosurg* 1983;58: 300-302.
9. Peterman SB, Steiner RE, Bydder GM. Magnetic resonance imaging of intracranial tumors in children and adolescents. *AJNR* 1984;5:703-709.
10. Russel DS, Rubinstein LJ. *Pathology of Tumors of Nervous System. Fifth edition. London: Edward Arnold, 1989:706-708.*
11. Di Rocco C. Arachnoid cysts. In: Youmans JR ed. *Neurological Surgery. Third edition. Philadelphia: W.B. Saunders Company, 1990;1307-1309.*
12. Bisese J. Cranial MRI: A teaching file approach. In: Day W, Englis MPR, eds. *Singapore: McGraw Hill, 1991:102-166.*
13. Halmagyi GM, Evans WA. Lipoma of quadrigeminal plate causing progressive obstructive hydrocephalus: case report. *J Neurosurg* 1978;49:453-456.
14. Bağdatoğlu H, İldan F, Doğanay M, Göçer I. Lipomas of the corpus callosum: A report of four cases. *Turkish Neurosurg* 1994;4:34-37.
15. Fisher RM, Cremin BJ. Lipoma of the corpus callosum: Diagnosis by ultrasound and magnetic resonance. *Pediatr Radiol* 1988;18: 409-410.