

# CARPAL TUNNEL RELEASE VIA LIMITED PALMAR INCISION USING RHINOPLASTY INSTRUMENTS

**Erdem Tezel, M.D. / Bahadır İmer, M.D.  
Ayhan Numanoğlu, M.D.**

*Department of Plastic and Reconstructive Surgery, School of Medicine,  
Marmara University, Istanbul, Turkey.*

## ABSTRACT

**Objective:** Carpal tunnel release via a limited palmar incision has been shown to combine the simplicity and safety of the traditional open approach with a reduction of tissue trauma and improved postoperative recovery of the endoscopic technique. A modification of this technique is presented.

**Methods:** The operation begins with a 1.5-2 cm palmar incision, dissection is performed using a Killian periosteal elevator, exposure is provided by a Killian speculum and the transverse carpal ligament is severed by angled cartilage scissors.

**Results:** Twenty-eight carpal tunnel cases were operated using this approach without any complication.

**Conclusion:** This technique not only pleased the surgeon by its simplicity and safety but also the patient who made a rapid and full recovery.

**Key Words:** Carpal tunnel, Decompression, Limited incision.

## INTRODUCTION

Carpal tunnel decompression operations have gained new perspectives and techniques in

recent years. Since the first release by Sir James R. Learmonth in 1930 and popularization by Phalen et al. in 1950, carpal tunnel release operations have been one of the most frequent operations in hand surgery. It gives excellent results both for the patients and the surgeon (1-3). The drawbacks of the long incision, such as a painful and unacceptable scar, tendon bowstringing and adherence of flexor tendons, have led to (1-3) the use of endoscopic procedures in carpal tunnel release. Because of this, refinements in the technique of open surgery have focused on the incision length. Recently, limited incision techniques have been popularized by several authors (1,4-7). A modification of this technique is presented.

## METHOD

Surgery is performed under tourniquet, loup magnification X4, and either regional anesthesia or axillary block is used. A 1.5-2 cm incision is located on a line drawn from the radial side of the ring finger to a point ulnar to the palmaris longus tendon, about 0.5 cm proximal to the distal border of the carpal tunnel as described by Campiglio et. al (7). The wrist is brought to full dorsiflexion. The distal edge of the transverse carpal ligament is reached by longitudinal spreading with scissors. The ligament is dissected free from the surrounding structures by blunt dissection using a Killian periosteal elevator.

(Accepted 11 August, 2002)

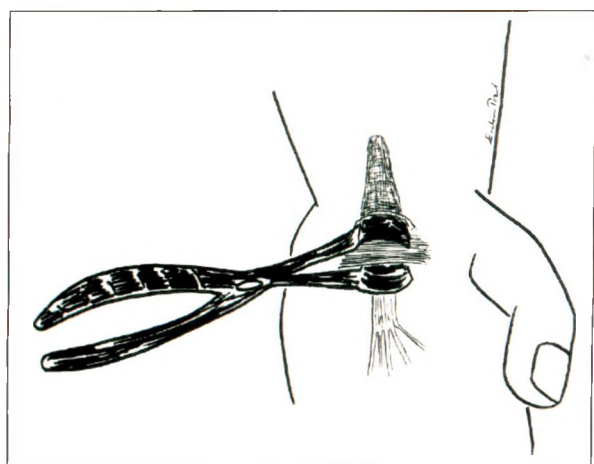
Marmara Medical Journal 2002;15(4):253-255

Correspondence to: Erdem Tezel, M.D. - Department of Plastic and Reconstructive Surgery  
Marmara University Hospital, Altunizade 81190 Istanbul, Turkey.  
e-mail address: erdemtezel@hotmail.com

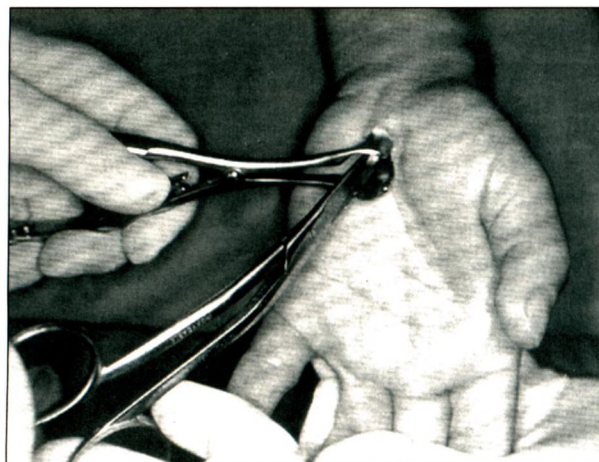
A Killian nasal speculum with a blade length of 40-50 mm is introduced while its blades are placed on the volar and dorsal aspects of the transverse carpal ligament (Fig.1a). Speculum positioning is critical for safety and visibility. The blades of the speculum must be kept in the longitudinal axis of the fourth metacarpal throughout the procedure as emphasized by Abouzahr et. al (4). The lower blade has to be kept in direct contact with the transverse carpal ligament to prevent median nerve injury. Opening the speculum creates a rectangular prism-shaped space and the ligament lies between the blades. Through the opening between the blades of the speculum, the ligament is divided from distal to proximal with angled cartilage scissors (Fig.1b). This step is performed with great care to avoid damage to the palmar cutaneous branch of the median nerve. The incision is closed with 2 or 3 stitches after complete release of carpal tunnel has been achieved under direct vision (Fig.2). A soft dressing is applied and the tourniquet is deflated. Patients are encouraged to move their digits in the early postoperative period and they return to daily work within 4-5 days.

## RESULTS

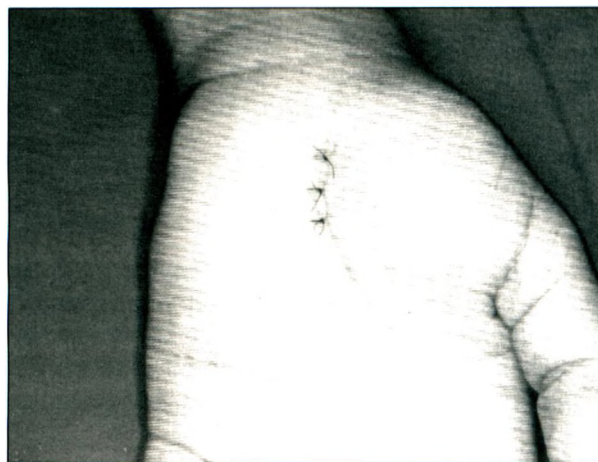This limited incision technique for carpal tunnel release was used in 28 cases, in July 1998. The



**Fig.1 (a) :** A Killian nasal speculum with a blade length of 40-50 mm is introduced with its blades positioned above and below the transverse carpal ligament. Speculum positioning is critical for safety and visibility. The blades of the speculum must be kept in the longitudinal axis of the fourth metacarpal throughout the procedure.



**Fig.1 (b) :** The transverse carpal ligament is severed from distal to proximal using angled cartilage scissors placed through the opening between the blades of the speculum.



**Fig.2 :** Immediate postoperative view of the incision.

average operation time was 25 minutes. The patients were followed for an average of 2 years and all had full recovery with no complications.

## DISCUSSION

The objective of the carpal tunnel operation is to relieve median nerve compression by complete division of the transverse carpal ligament. This is achieved in most patients, but, rarely, space-occupying lesions may be found which need to be excised, tenolysis or neurolysis may be necessary. These procedures can be performed easily by an open approach. The major drawbacks of the open technique are scarring,

tenderness, bowstringing and adhesion of tendons. The endoscopic approach overcomes these drawbacks but it is difficult to operate on the cases mentioned previously in which tenolysis, neurolysis or the removal of a space occupying lesion is required. Endoscopic surgery also has some drawbacks such as neurovascular injury, the need for special and expensive equipment, additional surgical training and a prolonged operative setup time. The advantages, simplicity and safety of the limited incision technique have been reported in detail by Abouzahr et al. (4). The advantages of the endoscopic procedures can be achieved by open surgery using short incisions, without having the complications of endoscopic surgery (5). The position of the incision as described has certain advantages over those in distal wrist crease (4). The superficial palmar arch is detected immediately and the dissection is diverted away from this vascular structure using a blunt instrument, the Killian periosteal elevator, under direct vision. This prevents injury to the superficial palmar arch, palmar cutaneous and thenar motor branches of the median nerve and the ulnar nerve and artery.

Limited incisions give limited exposure. Various retractors have been used by various authors to obtain better exposure (6,7). Abouzahr et al. used a speculum as a retractor, but they place the blades through a wrist incision and position them palmar to the carpal ligament, which could lead to superficial palmar arch injury, as was also emphasized by the authors (4). This drawback has been solved by changing the localization of the incision from the wrist to the palmar position as reported by Campiglio(7) and Serra(6) et al. We have combined Campiglio's approach(7) with Abouzahr's instrument, the nasal speculum, employing the advantages of both techniques.

The angled cartilage scissors are used to sever the ligament, thus it does not block the surgeon's vision, making the procedure easier and safer. All the instruments used are available in every plastic surgery department, this obviates the need for a special instrument such as a carpal tunnel tome (5), and lighted retractors or a light source are not required. Carpal tunnel release using a limited palmar incision is a safe and simple procedure and the approach presented here is a reliable modification of this technique.

## REFERENCES

1. Hayes C W. *Carpal tunnel syndrome*; In: Aston J, Beasley R W, Thorne C H M, eds. *Grabb & Smith's Plastic Surgery*. Philadelphia: Lippincott - Raven 1997: 917-927.
2. Van Beek A L. *Management of nerve compression syndromes and painful neuromas*. In: Mc Carthy JG, May J W, Littler J W, eds. *McCarthy Plastic Surgery*. Philadelphia: W.B.Saunders Company, 1990: 4823-4831.
3. Eversmann W W. *Entrapment & compression neuropathies*; In: Green J L, ed. *Operative Hand Surgery*. New York: Churchill Livingstone, 1993: 1342-1344.
4. Abouzahr M K, Patsis M C, Chiu T W. *Carpal tunnel release using limited direct vision*. *Plast Reconstr Surg* 1995, 95:534-539.
5. Andrew Lee W P, Strickland J W. *Safe Carpal tunnel release via a limited palmar incision*. *Plast Reconstr Surg* 1998; 101:418-421.
6. Serra J M R, Benito J R, Monner J. *Carpal tunnel release with short incision*. *Plast Reconstr Surg* 1997; 99:129-131.
7. Campiglio G L, Pajardi G. *Carpal tunnel release with short incision*. *Plast Reconstr Surg* 1998;101:1151-1153.



## Case Report

# AN UNUSUAL CAUSE OF URINARY RETENTION: A NINETEEN-YEAR-OLD SURGICAL GAUZE IN THE BLADDER

**Selçuk Yücel, M.D., / Kamil Çam, M.D., / Atıf Akdaş, M.D.,  
Levent Türkeri, M.D.,**

*Department of Urology, School of Medicine, Marmara University, Istanbul, Turkey.*

### ABSTRACT

Intravesical foreign body is a significant consideration in the assessment of lower urinary tract problems. We present a case of foreign body in the urinary bladder with the longest interval in the literature for clinical presentation, about 19 years following a transvesical prostatectomy. It provides an unusual indolent cause of urinary retention and stresses the consideration of intravesical foreign bodies as a reason for lower urinary tract symptoms.

**Key Words:** Bladder, Foreign body, Case report

### INTRODUCTION

Intravesical foreign body is an important concept in the assessment of lower urinary tract symptoms and a challenge to the urologist in both diagnosis and management. Two main causes of intravesical foreign bodies are self-introduction and iatrogenic. Reports of transvesical migration of surgical materials and transurethral insertion of foreign bodies for masturbative purposes and curiosity or due to mental disorders are common (1). In the literature, the longest time for clinical presentation of a foreign body in the urinary

bladder was reported as 9 years (1). In our case, the interval for clinical presentation was about 19 years following a transvesical prostatectomy. The commonest symptoms are chronic irritative complaints and hematuria (2, 3). However, the current case presented a much more indolent course with urinary retention at the nineteenth year of transvesical prostatectomy.

The current case provides an unusual cause of urinary retention and suggests the consideration of intravesical foreign bodies as a reason for lower urinary tract symptoms.

### CASE REPORT

An 83-year-old gentleman presented with a history of urinary retention associated with multiple urethral catheterizations for a year. His past medical history revealed transvesical prostatectomy at the age of 64. His physical examination revealed a moderately enlarged prostate with a hard nodule. PSA level was 4.97 ng/ml. Ultrasonography demonstrated a 6x4x4 cm mass outside the right bladder wall and pelvic computerised tomography (CT) confirmed this mass. CT guided biopsy of the mass revealed necrotizing inflammation. Bone scintigraphy was performed for right hip pain and increased radioisotope uptake was observed at the right acetabulum and lumbar vertebrae. Abdominal

ultrasonographic examination revealed a 5-cm hypoechoic mass in the liver and ultrasound guided biopsy of this mass exhibited a malignant epithelial tumor. PSA staining of the pathological specimens was negative. Transrectal ultrasound (TRUS) guided prostate biopsy disclosed benign prostatic hyperplasia. Repeat TRUS guided biopsy of the pelvic mass showed foreign body reaction with multinuclear giant cells. Further systemic investigation for the origin of the malignancy was unrevealing. Consequently, he was diagnosed as having metastatic anaplastic carcinoma of unknown origin. A cystoscopy was performed due to lower urinary tract symptoms. Endoscopy showed normal findings except a 4x2x2cm surgical gauze which was easily freed and taken out by an alligator forceps protruding through the right bladder wall. However, residual threads of the gauze were still emerging through the bladder wall. The appearance of the surgical gauze was surprisingly very fresh. Transurethral deep resection of the right bladder wall and deep biopsies around this location were performed. The patient recovered from surgery well and pathological evaluation revealed chronic cystitis with no findings of malignancy. After removal of the urinary catheter, he voided effectively. Palliative radiotherapy to the right acetabulum was applied.

## DISCUSSION

Intravesical foreign body is an important concern in the evaluation of lower urinary tract problems. Two main causes of intravesical foreign bodies are self-introduction and iatrogenic. Reports of transvesical migration of surgical materials and

transurethral insertion of foreign bodies for masturbative purposes and curiosity or due to mental disorders are not uncommon (1). In the literature, the longest time for clinical presentation of a foreign body in the urinary bladder was reported as 9 years (1). In our case, the interval for clinical presentation was about 19 years, following a transvesical prostatectomy. Also, it was interesting to see the surgical gauze had no degeneration or calcification in the acidic environment of the urinary bladder. Although the commonest symptoms were chronic irritative complaints and hematuria, acute urinary retention was reported similarly due to surgical gauze left during the inguinal hernia repair performed two weeks before (2). Our case was unique as having a much more indolent course with urinary retention at the nineteenth year of transvesical prostatectomy.

The present case postulates an exceptional cause of infravesical obstruction and emphasises the importance of intravesical foreign bodies related to the previous surgery as a reason for lower urinary tract symptoms even after two decades of the operation.

## REFERENCES

1. Eckford SD, Persad RA, Brewster SF, Gingell JC. Intravesical foreign bodies: five-year review. *Br J Urol* 1992; 69: 41-45.
2. Leppaniemi AK. Intravesical foreign body after inguinal herniorrhaphy. *Scand J Urol Nephrol* 1991; 25: 87-88.
3. Schwartz BF, Stoller ML. The vesical calculus. *Urol Clin North Am* 2000; 27: 333-346.