

## A RARE LESION OF GLANS PENIS: LYMPHANGIOMA

**Tayfun Oktar, M.D. / Ahmet Tefekli, M.D. / Öner Şanlı, M.D.  
Bülent Erol, M.D. / Ateş Kadioğlu, M.D.**

*Department of Urology, School of Medicine, Istanbul University, Istanbul, Turkey.*

### ABSTRACT

Lymphangiomas of the urinary tract are rare lesions and those of the penis are even rarer. Herein we report a case of cutaneous lymphangioma of glans penis in a 35-year-old man and its surgical treatment. Preoperative MRI imaging defined the mass on the glans as hemangioma but the histopathologic examination revealed cutaneous lymphangioma of glans penis. The lesion was successfully treated surgically.

**Key Words:** Penis, Lymphangioma, Neodymium: Yag laser

### INTRODUCTION

Tumors of glans penis are very rare lesions. Their diagnosis is usually based on clinical examination as well as radiological evaluation and their treatment consists of surgical excision. Herein we describe a rare case of cutaneous lymphangioma of glans penis diagnosed by histopathological examination although preoperative radiological diagnosis was hemangioma. The lesion was excised and successfully treated with no recurrence.

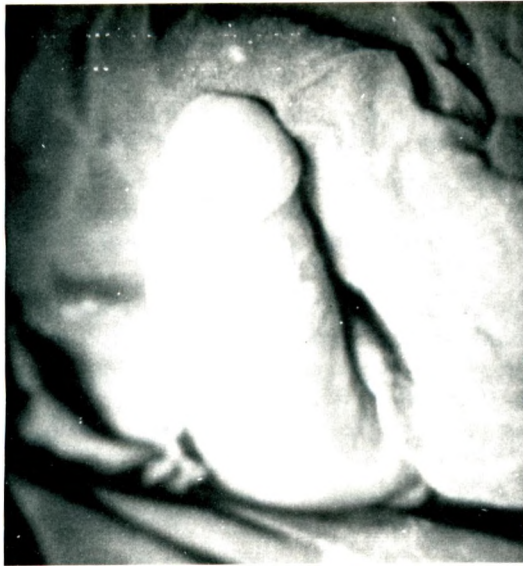
### CASE REPORT

A 35-year-old man presented with a painless swelling on glans penis which expanded with erection. On physical examination, a pink nodular lesion of 1 cm in diameter, soft on palpation, located on the dorsum glans penis (Fig.1a) was noted, looking like a hemangioma. His medical history revealed nothing special except that this nodular lesion was present since his birth. MRI imaging of the penis (Fig.2) was performed in order to determine the extension of the lesion and it showed a solid lesion on the dorsum of glans penis (10x10x8 mm.) that was hypointense on TW1 and hyperintense on TW2 scans. It seemed to be highly vascularized, thus the radiological diagnosis was hemangioma.

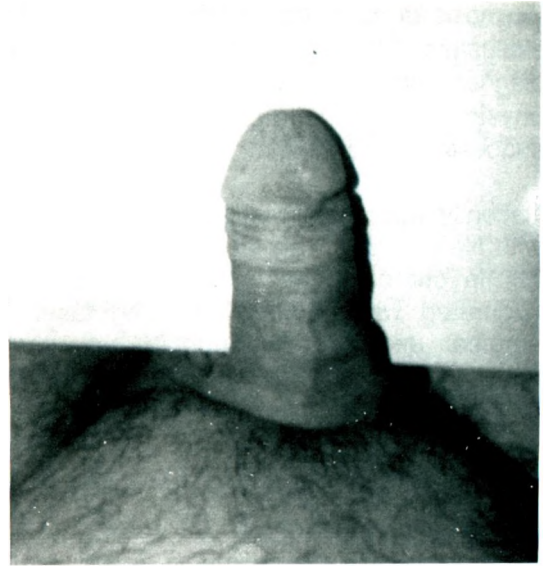The patient was concerned about rupture of this lesion during sexual intercourse and the lesion was excised under general anesthesia. Its base was fulgurated with Neodymium: Yag laser. The defect was primarily closed with 4/0 chromic catgut.

Histopathological examination revealed cutaneous lymphangioma of glans penis with dilated lymph vessels in the superficial dermis lined by a single layer of endothelial cells.

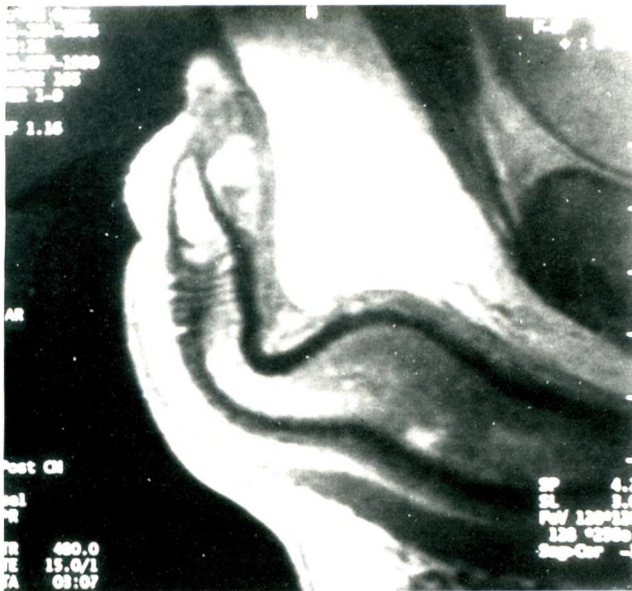
On his follow up of 12 months, the patient did well with no recurrence (Fig. 1b).



**Fig. 1 a:** A pink, nodular lesion located on the dorsum of glans penis,



**1 b:** Appearance 12 months after surgery.



**Fig. 2:** MRI imaging of penis; a hypointense lesion TW1 scan.

## DISCUSSION

Tumors of the penis are uncommon. The most frequent neoplasms are carcinoma and condyloma accuminata. Fibroma, hemangioma, lymphangioma circumscriptum must also be considered in the differential diagnosis of cutaneous lesions of glans penis. Pearly penile papules, hirsute papillomas and coronal papillae are normal and commonly encountered lesions of glans penis (1).

Cutaneous lymphangioma, also called lymphangioma circumscriptum, are very rare pathologies of the penis and only a few anecdotal cases have been reported up to date (2). The lesion is characterized as a benign saccular dilatation of thin-walled lymph vessels, presenting as a local eruption of persistent, grouped translucent vesicles and not known to involve malignant degeneration (3, 4). It is more common in females and any cutaneous site may be effected. They can be due to a developmental abnormality of the lymphatics or to their obstruction secondary to surgical operation, Crohn's disease, tuberculosis, and other inflammatory diseases (5). It may appear during childhood but may suddenly enlarge later in life. A collection of large, muscular coated lymphatic cysts, that represent a closed system in which there is no real lymph circulation, in the deep subcutaneous tissue is suggested to be responsible for this pathology (3).

In our case, the medical history revealed that the lesion was present since his birth so it was considered to be a developmental abnormality.

Hemangiomas of the penis are also rare clinical entities that are usually located on the glans (6). In most cases preoperative

diagnosis of such lesions are based on clinical evaluation. However, in our case the exclusive diagnosis was based on histopathology although physical examination and MRI findings suggested hemangioma.

Recently, successful results have been reported with Neodymium: Yag laser treatment of penile (6). In our case the base of the lesion was fulgurated with Neodymium: Yag laser after surgical excision. Although a high rate of recurrence is accepted in such lesions, our patient did well during his follow up.

## REFERENCES

1. Walsh PC, Retik AB, Vaughan ED, Wein AJ. *Campbell's Urology. Seventh Ed. W.B. Saunders Comp, 1998: 2454*
2. Drago F. *Lymphangioma circumscriptum of the penis. Acta Derm Venereol 1997; 77: 252*
3. Whimster I W. *The pathology of lymphangioma circumscriptum. Br J Dermatol 1976; 94: 473-486*
4. Sadıkođlu B, Kuran İ, Özcan H, Gözü A. *Cutaneous lymphatic malformation of the penis and scrotum. J Urol 1999; 162: 1445-1446*
5. Cecchi R, Bartoli L, Brunetti L, Pavesi M, Giomi A. *Lymphangioma circumscriptum of the vulva of late onset. Acta Derm Venereol (Stockh) 1995; 75: 79-80*
6. Jimenez-Cruz J F, Osca J M. *Laser treatment of glans penis hemangioma. Eur Urol 1993; 24: 81-83*