

CASE REPORT

Prosthodontic treatment of an adolescent patient with hypohidrotic ectodermal dysplasia: Case report

Erhan Dilber¹, Tuba Yılmaz Savaş², Filiz Aykent²

Selçuk Dental Journal, 2015; 2: 76-80

Başvuru Tarihi: 16 Mart 2015
Yayına Kabul Tarihi: 22 Nisan 2015

Hipohidrotik ektodermal displazili bir hastanın protetik tedavisi: Bir olgu sunumu

Üst çenesinde oligodonti ve alt çenesinde anodonti görülen hipohidrotik ektodermal displazili (HED) 13 yaşındaki erkek hastanın konvansiyonel protetik yaklaşımı rapor edilmiştir.

Fonksiyonel, psikolojik, ekonomik ve estetik faktörler tedavi planlamasında dikkate alınmıştır. Üst çenede kanal tedavili sürekli santral kesicilerden ve sürekli 2. molar dişlerin kroşelerinden destek alınarak hareketli bölümlü protez alt çenede de hareketli tam protez klinik olarak planlanmıştır. 5 sene sonraki takibinde, hasta çenesini kapatırken protrüzyona alışmış ve ön bölgede retansiyon kaybı yaşamış fakat protezlerinden memnun olduğunu ve konuşmasının düzeldiğini söylemiştir.

Bu vaka HED görülen büyümekte olan hastalarda konvansiyonel protetik tedavi yaklaşımını rapor etmektedir. İmplant destekli protez yaptıramayan ya da uygun olmayan çocuk hastalarda bu tedavinin faydalı psikolojik etkileri vardır ve bu tedavi stomagnatik fonksiyon, estetik ve fonasyonu arttırmaktadır.

ANAHTAR KELİMELER

Ektodermal displazi, habitüel mandibular protrüzyon, hareketli protez

Hypohidrotic ectodermal dysplasia (HED) is a rare genetic condition affecting structures of ectodermal origin (Bergendal 2010, Singer et al 2012). It typically occurs in men and shows an X-linked pattern. Common symptoms include hypotrichosis, hypohidrosis, anodontia, and oligodontia (Acikgoz et al 2007, Park et al 1999). Affected individuals have dry, scaly, and thin skin and absent or sparse eyebrows, eyelashes, and scalp

hair (Acikgoz et al 2007, Ohno and Ohmori 2000). Oligodontia results in alveolar bone loss, underdeveloped alveolar ridges, and reduced sulcular depth (Bergendal 2010, Singer et al 2010). Frontal bossing, saddle nose, prominent supraorbital ridges, unguis malformation, palmar and plantar hyperkeratosis, abnormal pigmentation, periorbital wrinkles, and chronic rhinitis and pharyngitis are additional anomalies in some cases (Itthagarun and King 1997, Oliver et al 1975). Conical roots of posterior teeth, peg-shaped anterior teeth, delayed eruption, impacted teeth, enlarged pulp chambers, and taurodontism may be observed in the primary and permanent dentitions (Kupietzky and Houpt 1995, Vierucci et al 1994).

Oral rehabilitation of pediatric patients with HED usually involves removable dental prostheses. The esthetic, psychological, and functional problems of actively growing affected children can also be resolved with implant-supported dental prostheses (Alcan et al 2006, Singer et al 2012).

Here, we report the conventional prosthodontic treatment of maxillary oligodontia and mandibular anodontia in a 13-year-old boy with HED.

OUTLINE OF THE CASE

The patient was referred to the Prosthodontics Department of Selçuk University for treatment of oligodontia. He had never worn dental prostheses. Intraoral examination revealed maxillary oligodontia characterized by the presence of the primary second molars and permanent central incisors (Figure 1).

¹ Şifa University, Faculty of Dentistry, Department of Prosthodontics, İzmir, Turkey

² Selçuk University, Faculty of Dentistry, Department of Prosthodontics, Konya, Turkey

Mandibular teeth were absent. Thinned and shortened alveolar ridges and decreased sulcular depth were observed posteriorly. The palate had no mucosal defects. The tongue was enlarged and extended. Extraoral examination revealed dry and rough skin, increased pigmentation, perioral wrinkles, and swollen and dry lips (Figure 2). Panoramic radiography indicated that the roots of the permanent central incisors were suitable for treatment, and unerupted teeth were absent in both the jaws.

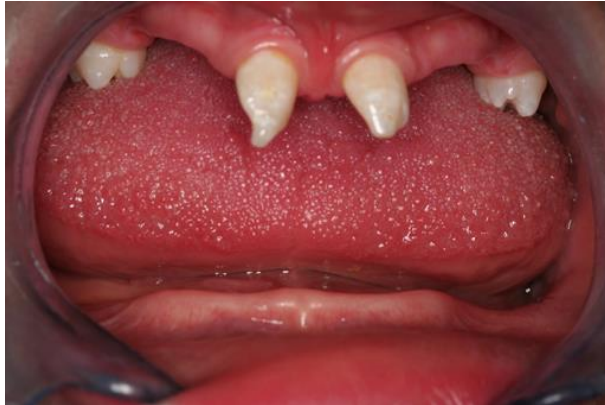

Figure 1.

Initial intraoral view

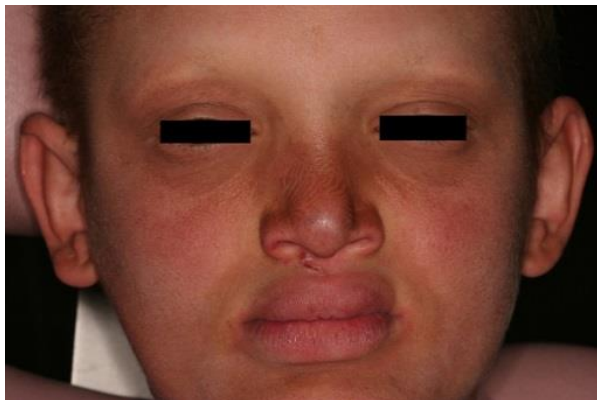


Figure 2

Initial frontal view

The treatment plan was to provide a partial removable dental prosthesis in the maxillary arch and complete removable dental prosthesis in the mandibular arch. First, the permanent central incisors were endodontically treated and prepared for metal copings. Impressions of the teeth were made with polyvinyl siloxane elastomeric impression material (Elite HD, Zhermack, Badia Polesine, Italy), and metal copings were cemented with chemically polymerizing adhesive resin (Panavia 21, Kuraray Co., Ltd., Osaka, Japan)

(Figure 3). Preliminary impressions were made with irreversible hydrocolloid (Hydrogum Thixotropic, Zhermack), and custom trays were fabricated for final impressions. The obtained dental casts were covered with acrylic resin baseplates and wax occlusion rims, the maxillomandibular relationship record was obtained by the standard method, and the record was mounted on a semi-adjustable articulator. Age-appropriate artificial teeth were selected and arranged. Finally, a chromium-cobalt partial removable dental prosthesis was placed in the maxillary arch and complete removable dental prosthesis was placed in the mandibular arch (Figure 4). Occlusion was equilibrated after placement, and instructions regarding maintenance were provided.

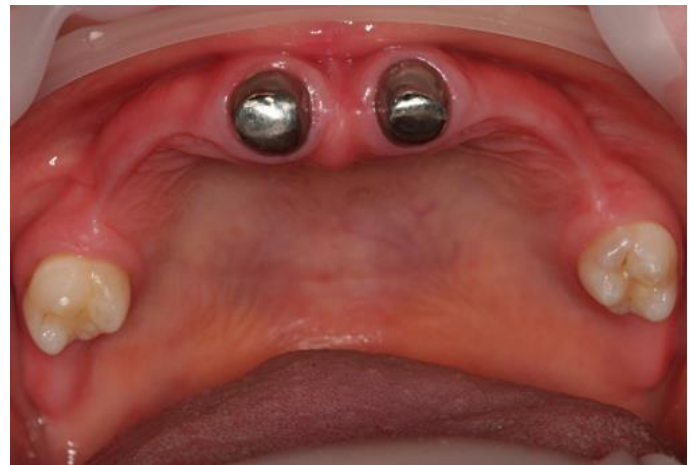

Figure 3.

Intraoral view showing metal copings on the endodontically treated maxillary central incisors

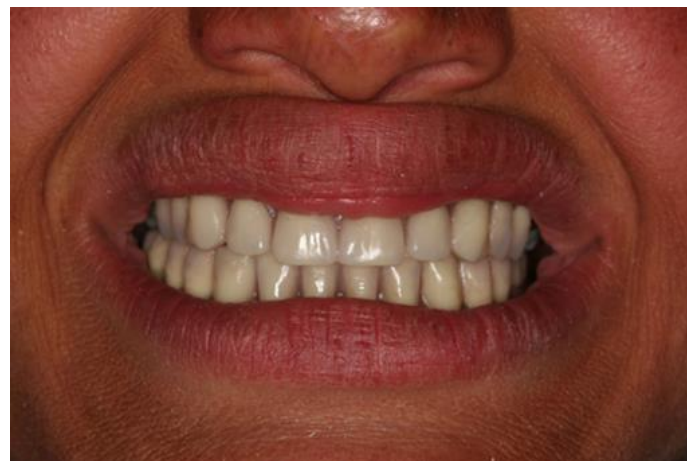

Figure 4.

Intraoral view showing the maxillary and mandibular dental prostheses

Although the patient was recalled every six months, he did not visit the clinic regularly. He was a villager and his home was too far to clinic. With phone calls, his mother reported significant improvements in speech and

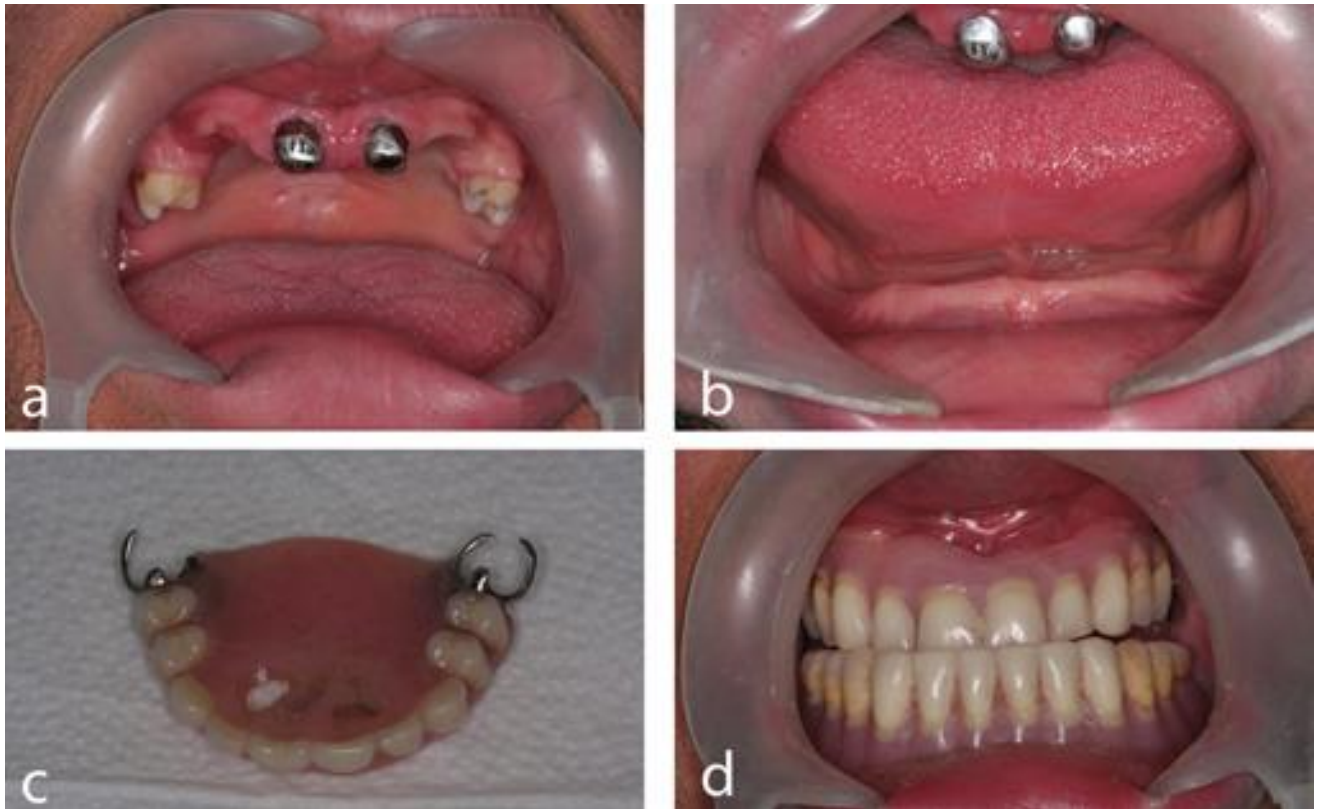


Figure 5.

Five-year follow-up findings.

a) Maxillary and b) Mandibular views c) Maxillary partial removable dental prosthesis d) Maxillary and mandibular dental prostheses

mastication. Five years later, he visited the clinic (Figure 5a) for dental implant placement. A small hole has developed around the metal copings and a circumferential (lingual) clasp has fractured (Figure 5c). Further, the patient protrudes the mandible while

closing his mouth (Figure 5d). His appearance has changed (Figure 6), and the artificial teeth are abraded. Dental implant treatment or replacing older prostheses have been delayed because of economic and transportation reasons.

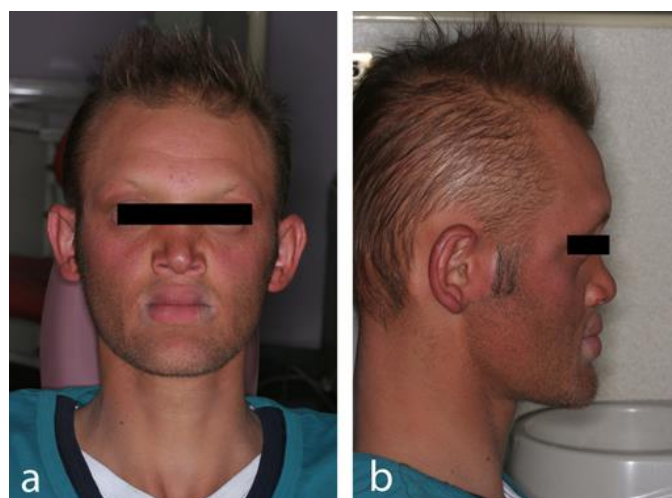

Figure 6.

Final facial appearance

a) Frontal and b) Profile views

DISCUSSION

Early rehabilitation is an important outcome of dental treatment in patients with HED. A dental prosthesis can enhance the tonus of masticatory muscles and prevent alveolar bone resorption due to the absence of teeth. Removable dental prostheses could provide the optimum vertical dimension and prevent angular cheilitis. There is no recommended age at which treatment should commence (Acikgoz et al 2007). However, prosthetic restoration should be completed before school age for functional, phonational, psychological, and esthetic reasons (Bergendal 2002, Ohno and Ohmori 2000). In the present case, removable dental prostheses were fabricated for the adolescent patient, who did not attend school because of his economic status.

Oligodontia or anodontia associated with HED is usually characterized by severely resorbed or underdeveloped alveolar bone with reduced alveolar ridge height (Tarjan et al 2005). The bone volume available for supporting dental prostheses and implants may be not enough in some cases (Guckes et al 2002). The patient's age, dental and skeletal maturity, and bone volume could affect the quality of surgical and prosthetic rehabilitation (Imirzalioglu et al 2002). Early placement of dental implants has been recommended in children with severe hypodontia or anodontia (Alcan et al 2006, Kramer et al 2007, Singer et al 2012). Guckes et al (2002) analyzed the survival rate of 264 dental implants in 51 subjects with HED: they reported 91% and 76% survival rates for mandibular and maxillary dental implants, respectively.

Periodic recall presents opportunities to modify or replace prostheses to accommodate growth and development of the jaws. A 6- to 12-month recall schedule is recommended until skeletal growth is completed (Vieira et al 2007). When we observed the alveolar ridges after 5 years, we found vertical bone loss especially in the anterior region. The patient, however, is satisfied with his prostheses. Habitual mandibular protrusion caused loss of retention. Furthermore, clinical and radiographic examinations revealed no skeletal growth.

CONCLUSION

Removable dental prostheses are a practical, acceptable, and economical solution for oral rehabilitation of patients with HED. They improve the patient's quality of life and stimulate the alveolar ridges for later treatment with implant-supported dental prostheses, a more stable and esthetic solution. Clinicians must consider the patient's age and presence of underdeveloped and thinned alveolar ridges before dental implant placement in children with HED.

Prosthetic treatment of an adolescent patient with hypohidrotic ectodermal dysplasia: Case report

The conventional prosthetic treatment of maxillary oligodontia and mandibular anodontia in a 13-year-old boy with hypohidrotic ectodermal dysplasia (HED) was reported in this case.

Functional, psychological, economic, and esthetic factors were considered for treatment planning. Clinical management involved placement of a partial removable dental prosthesis, retained by endodontically treated permanent central incisors and clasps on the primary second molars, in the maxillary arch and a complete removable dental prosthesis in the mandibular arch. The patient developed habitual mandibular protrusion during mouth closure and loss of retention in the anterior region during the following 5 years, but he was satisfied with the prostheses and his speech and mastication improved.

The report highlights the outcomes of conventional prosthetic treatment in an actively growing child with HED. Such treatment would have beneficial psychological effects and improve stomatognathic functioning, esthetics, and phonation in pediatric patients who are not candidates for implant-supported dental prostheses.

KEY WORDS

Ectodermal dysplasia, habitual mandibular protrusion, removable dental prosthesis

KAYNAKLAR

- Acikgoz A, Kademoglu O, Elekdag-Turk S, Karagoz F, 2007. Hypohidrotic ectodermal dysplasia with true anodontia of the primary dentition. *Quintessence Int*, 38, 853-858.
- Alcan T, Basa S, Kargul B, 2006. Growth analysis of a patient with ectodermal dysplasia treated with endosseous implants: 6-year follow-up. *J Oral Rehabil*, 33, 175-182.
- Bergendal B, 2002. Children with ectodermal dysplasia need early treatment. *Spec Care Dentist*, 22, 212-213.
- Bergendal B, 2010. Oligodontia ectodermal dysplasia--on signs, symptoms, genetics, and outcomes of dental treatment. *Swed Dent J Suppl*, 13-78, 17-18.
- Guckes AD, Scurria MS, King TS, McCarthy GR, Brahim JS, 2002. Prospective clinical trial of dental implants in persons with ectodermal dysplasia. *J Prosthet Dent*, 88, 21-25.
- Imirzalioglu P, Uckan S, Haydar SG, 2002. Surgical and prosthodontic treatment alternatives for children and adolescents with ectodermal dysplasia: a clinical report. *J Prosthet Dent*, 88, 569-572.
- Itthagarun A, King NM, 1997. Ectodermal dysplasia: a review and case report. *Quintessence Int*, 28, 595-602.
- Kramer FJ, Baethge C, Tschernitschek H, 2007. Implants in children with ectodermal dysplasia: a case report and literature review. *Clin Oral Implants Res*, 18, 140-146.
- Kupietzky A, Haupt M, 1995. Hypohidrotic ectodermal dysplasia: characteristics and treatment. *Quintessence Int*, 26, 285-291.
- Ohno K, Ohmori I, 2000. Anodontia with hypohidrotic ectodermal dysplasia in a young female: a case report. *Pediatr Dent*, 22, 49-52.
- Oliver DR, Fye WN, Hahn JA, Steiner JF, 1975. Prosthetic management in anhydrotic ectodermal dysplasia: report of case. *ASDC J Dent Child*, 42, 375-378.
- Park JW, Hwang JY, Lee SY, Lee JS, Go MK, Whang KU, 1999. A case of hypohidrotic ectodermal dysplasia. *J Dermatol*, 26, 44-47.
- Singer SL, Henry PJ, Lander ID, 2010. A treatment planning classification for oligodontia. *Int J Prosthodont*, 23, 99-106.
- Singer SL, Henry PJ, Liddel G, Rosenberg I, 2012. Long-term follow-up of implant treatment for oligodontia in an actively growing individual: a clinical report. *J Prosthet Dent*, 108, 279-285.
- Tarjan I, Gabris K, Rozsa N, 2005. Early prosthetic treatment of patients with ectodermal dysplasia: a clinical report. *J Prosthet Dent*, 93, 419-424.
- Vieira KA, Teixeira MS, Guirado CG, Gavião MB, 2007. Prosthodontic treatment of hypohidrotic ectodermal dysplasia with complete anodontia: case report. *Quintessence Int*, 38, 75-80.
- Vierucci S, Baccetti T, Tollaro I, 1994. Dental and craniofacial findings in hypohidrotic ectodermal dysplasia during the primary dentition phase. *J Clin Pediatr Dent*, 18, 291-297.

Correspondence:

Dr. Erhan Dilber
 Şifa University, Faculty of Dentistry
 Department of Prosthodontics
 Mansuroğlu Mah. 293/1 Sk.35100
 Bayraklı/İzmir, Turkey
 Fax: +90 (232) 486 41 47
 E-mail: dilberhan@gmail.com