

Diagnosis and Treatment of Massive Pulmonary Thromboembolism in A Patient With Metastatic Colon Adenocarcinoma

**Süreyya YILMAZ¹, Yaşar YILDIRIM², Zülfükar YILMAZ², Emre AYDIN³,
Recai AKDOĞAN³, Barış ÇİL¹, Ali Kemal KADİROĞLU², Füsun TOPÇU¹, M.Emin YILMAZ²**

¹Department of Pulmonary Diseases, Faculty of Medicine, University of Dicle, 21280, Diyarbakir, Turkey

²Department of Internal Medicine and Nephrology Intensive Care Unit, Faculty of Medicine, University of Dicle, 21280, Diyarbakir, Turkey

³Department of Internal Medicine, Faculty of Medicine, University of Dicle, 21280, Diyarbakir, Turkey

Abstract

Aim: Massive pulmonary thromboembolism (PTE) is one of the cause of unexpected deaths in hospitalized patients. Our aim is to present diagnosis and treatment of massive pulmonary thromboembolism in a patient with pneumonia and cancer.

Case: A 52 years old male with a metastatic colon adenocarcinoma, admitted to the emergency department with shortness of breath, one month after the right hemicolectomy and chemotherapy. The physical examination of the patient: general condition was bad and he had tachypnea, tachycardia, and rals in the left lung bases and leukocyte: 21.000 K/ml, CRP: 28mg/dl, Ph:7.46, PaO₂:56.6, PaCO₂:23.2, SO₂:%82, HCO₃:19.8. Tachypnea, tachycardia, hypoxia, hypocapnia, and respiratory alkalosis was observed, PTE was considered and diagnosed by CT pulmonary angiography. 50 mg Alteplase was applied to the patient. After administration of alteplase, general condition was improved (pH:7.37, PaO₂:85.1, PaCO₂: 38.9,SO₂:98.5%, HCO₃:20.3).

Conclusion:Pneumonia, may mask the diagnosis of PTE and should be considered in patients with dyspnea, hypocapnia, hypoxia, and hypotension.

Key words: Colonic Neoplasms; Pneumonia; Pulmonary Embolism; Thrombolytic Therapy

* Corresponding author: E-mail: : sureyyayilm@gmail.com
Phone: +90 412 2488001/4157
GSM: +90 533 3051084
Fax :+90 412 2488171

Introduction

Massive pulmonary thromboembolism (PTE) is one of the main causes of unexpected deaths in hospitalized patients. Especially the patients with cancer are at risk of high venous thromboembolism (VTE)¹. The three-month mortality rate is on average of 17% in PTE². On the other hand, the patients who have shock and / or persistent hypotension in massive PTE; the mortality rate increase to 25-30% when they treated medically and when they underwent cardiac resuscitation it can be increased up to 67%^{3,4}. Death usually occurs within the first one to two hours in fatal cases of PTE. In postmortem studies; very few cases of fatal PTE have symptoms of deep vein thrombosis (DVT) and a very small proportion of these patients who have symptoms of DVT were investigated before death⁵. In the study of autopsy which was made on patients who died in Intensive Care Unit (ICU); despite 17 of 66 patients (26%) were found to have PTE and only half of these patients were diagnosed before death⁶.

Cancer is a major risk factor of venous thrombosis. The incidence of VTE in patients with cancer is unclear. However, autopsy studies show approximately 50% of patients have VTE findings. 15-20 % of all thromboembolic events appears among cancer patients⁷. Cancer increases risk of VTE for 4-6 times. Early or advanced cancer is determined in one or two years among almost 10% of the patients diagnosed with idiopathic thrombosis. It has been observed that an increased risk of PTE event in patients with cancer diagnosed within a few months and this risk is associated with distant metastases⁸. It shows higher rate of risk of thrombosis in brain, ovary, pancreas, lung, prostate and kidney tumors. Our aim is to present this phenomenon, to discuss massive pulmonary thromboembolism that is developed, to investigate a major cause of mortality in patients admitted to the general internal medicine intensive care unit with pneumonia and metastatic carcinoma of the colon adenoma in the light of current knowledge.

Case Report

A 52 years old male patient who did not have any complaints before, had colonoscopy at Gastroenterology clinic due to abdominal distension, and loss of weight which had started 6 months ago and biopsy taken from the proximal colon.

Patology result had been reported as mucinous adenocarcinoma of the colon. He had been treated with right hemicolectomy after one month of diagnosis with adenocarcinoma of the colon and has been externed to the oncology polyclinic where had been suggested to apply. Because of the diagnosis of liver metastasis, IV colon adenocarcinoma was accepted in oncology clinic, and irinotecan 360 mg (1 day), folinikascite 400 mg (1 day), 5FU 5000 mg (2 days), Cetuximab 800 mg (once a week) protocol is which consists folfiri + cetuximab applied with palliative intent. After 20 days of chemotherapy because of the worsening of general condition and shortness of breath developed, he was applied to the emergency department, admitted to a gastroenterology clinic with the diagnosis of pneumonia (Figure 1 and 2).

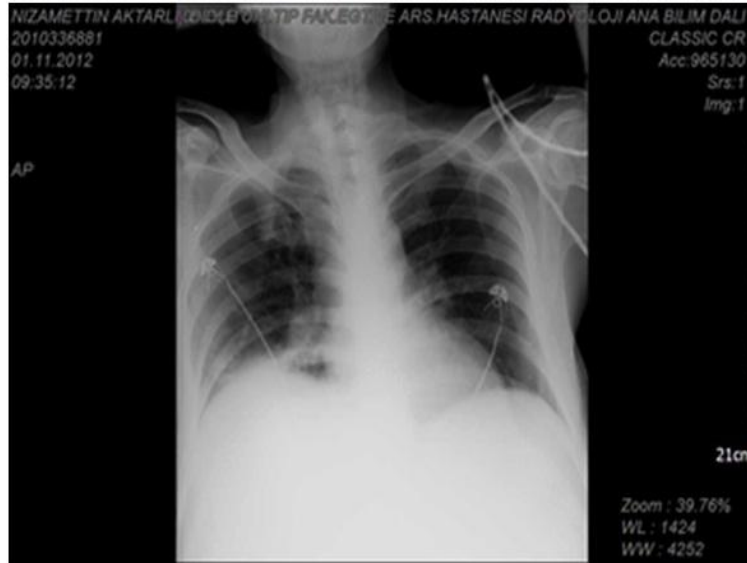


Figure 1: Chest X-ray image obtained from the patient.

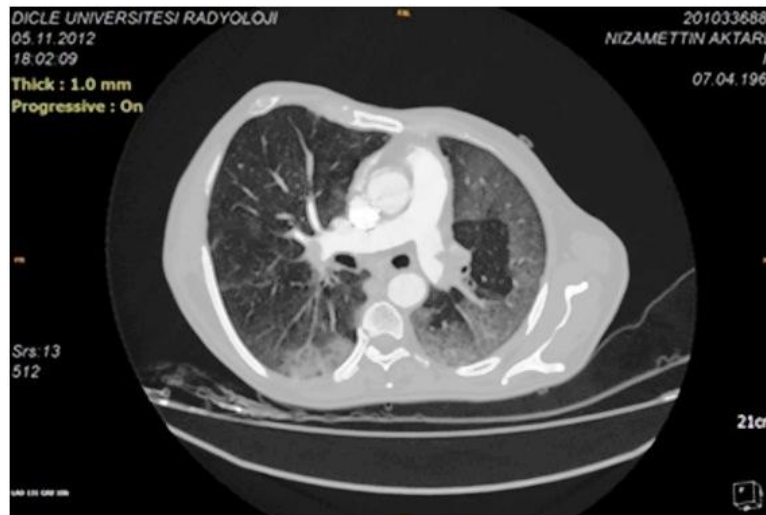


Figure 2: Computerized (CT) tomography image obtained from the patient.

In clinical follow-up, the patient has been transferred to the general internal medicine intensive care unit because of increasing dyspnea. The patient's general condition was bad, but mind was clear, blood pressure: 90/52 mmHg, heart rate: 110/min., fever: 37° C, respiratory rate: 24/min, light reflex(LR): + / +, kranial reflex (KR):+ / +, Babinski reflex: - / -, Glaskow coma scale scor(GCS): 15, Sequential Organ Failure Assessment Score (SOFA) score: 8, input: 2500 cc , output: 1800 cc, defecation: (-), Respiratory System: tachypnea, crepitant rals in the left lung bases, Cardiovascular system: sinus tachycardia, Gastrointestinal System: Abdomen distended, sensitivity (+), massif palpation (+). Laboratory: leukocyte 21.000K/ml, haemoglobin: 8.75 g / dl, platelet: 798 000 K / ml, INR: 1.24, APTT: 36.4, PT: 14.8, fibrinogen: 520, D-Dimer: 0.39, glucose: 114 mg/dl, urea:93 mg/dl, creatinine:1.18 mg/dl, Na:136 mg/dl, K: 4.1 mg/dl, Ca: 8.0 mg/dl, total bilirubin: 0.9 mg/dl, direct bilirubin: 0.6 mg/dl, AST: 25 mg/dl, ALT: 17 mg/dl, ALP: 680 mg/dl, LDH: 527 mg/dl, Total Protein: 6.1, albumin: 1.7g/l, globulin: 4.4, CRP: 28 mg/dl, urine analysis: leukocyte: 100, Blood: 250, in the culture of urine: Enterococcus Faecalis, tumor markers: CEA: 286.3, CA-15-3:N,

CA-72-4: 300,CA-125: 210.3,CA-19-9: N,PSA: N Cardiac: Troponin I: 0.06, arterial blood gas: Ph:7.46,PaO₂:56.6, PaCO₂: 23.2, SO₂:%82, HCO₃: 19.8.

In the colored doppler ultrasonography of bilateral lower extremity deep vein system; based on the vein thrombosis examination in supine position: VCI; in both sides, main and external iliac; main, deep and superficial femoral; significant structural or hemodynamic pathology was not found in popliteal and deep cranial segments of crurale vein. In the examined segments, acute phase deep vein thrombosis was not found.

Echocardiography: During the examination, patient was dysrhythmic. Heart rate: 110/min. Expansion in the right cardiac cavity. Tricuspid insufficiency (2nd degree) and PABS: 50-55 mmHg.

CT(Computerized Tomograph) angiography, one anatomic section (contrast): Torax CT and 3D CT examination: Some sections obtained through CT having 64 detectors, and Torax CT & 3D CT examination done at the station with re-constructing sections of 1 mm thickness. Filming done by PTE Protocol.

Clinic Information: PTE pulmonary thromboendarterectomy.

Findings: There are hypodense filling defects in both pulmonary artery and its branches. Common mosaic perfusion appearance in both lungs and together with prominence in the interlobular septas in these areas(secondary to PTE?). Abdominal sections within the study area has increased liver size, hypodense lesion is largely followed involving the right lobe (metastasis?). As far as it can be measured anterior to the left lobe of the liver, hypodense appearance of about 176 x 67 mm in size are available (Figure 3).

Meroponem was applied at a dose of 3 × 1 g/day for pneumonia to the patient. After diagnosis of tachypnea, tachycardia, hypoxia, hypocapnia, respiratory alkalosis; PTE was considered, deep vein thrombosis was not detected at the lower extremity Doppler ultrasound. Echocardiography revealed an expansion in right heart chambers and for definite diagnosis. The patient's CT pulmonary angiography (CTPA) was filmed and massive pulmonary embolism detected. 50 mg Alteplase (IV) was started to the patient. At the second administration of alteplase, nasal bleeding was occurred due to thrombolytic therapy, so it was stopped. Patient was observed for a day in general internal medicine intensive care unit, shortness of breath decreased, tachypnea and tachycardia improved and in the control of arterial blood gases pH:7.37, PaO₂:85.1, PaCO₂: 38.9, SO₂: 98.5 %, HCO₃: 20.3 was found. The patient was transferred to gastroenterology clinic.

Discussion

The patient admitted to emergency department of Medicine Faculty Hospital in Dicle University due to shortness of breath; antibiotics started after white blood cell count, fever, dyspnea and chest X-ray are controlled and detection of suspected infiltration area admitted with the diagnosis of pneumonia. The patient was transferred to the general internal medicine intensive care unit when deepening of dyspnea, hypoxia, tachycardia, tachypnea had expanded. Generally the patients over 40 years old which can be mobilized limited and in addition have at least one risk factor is considered to be at high risk for the development of VTE⁹. Our 52 years old patient was immobile and as a risk factor had a diagnosis of metastatic colon CA. Based on this information in the literature and as our patient has got pneumonia, it was thought to be PTE.

In lightning and arc studies, GIS cancers, with 27.2% portion were identified as the most common type of cancer in PTE ¹. Although mucin-producing adeno carcinomas are the most common cancers that make thrombosis, the most frequent cancers in patients with thrombosis are the same as generally seen cancers in the society ¹⁰. The patient that we introduced with PTE, was noted as a mucin-producing adenocarcinoma cancer type in the pathology report. Also bevacizumab, 5-fluorouracil, thalidomide, tamoxifen and some medicines contain high dose of estrogen which are used for cancer chemotherapy, has been reported to be a risk for VTE ¹¹. Our patient was treated with chemotherapy of 5-fluorouracil for the aim of palliative.

In lightning and arc study, 45.7% of the patients with a diagnosis of PTE detected VTE in the lower extremities and nothing were found at 54.3% of them. While thromboemboli were found in both lungs of pulmonary arteries with the rate of 70.7%, unilaterally emboli was localized in the right lung with the rate of 65.5%. Massive embolism is 16.5 % in the patients who got diagnosis of PTE. In our case, VTE were not detected in bilateral lower extremity doppler ultrasonography. PTE can not be ruled out in the patients who had no cases of VTE. On the other hand when we did imaging with CTPA, we found PTE in both lungs and massive pulmonary embolism was detected in the pulmonary artery of left lung (Figure 3).

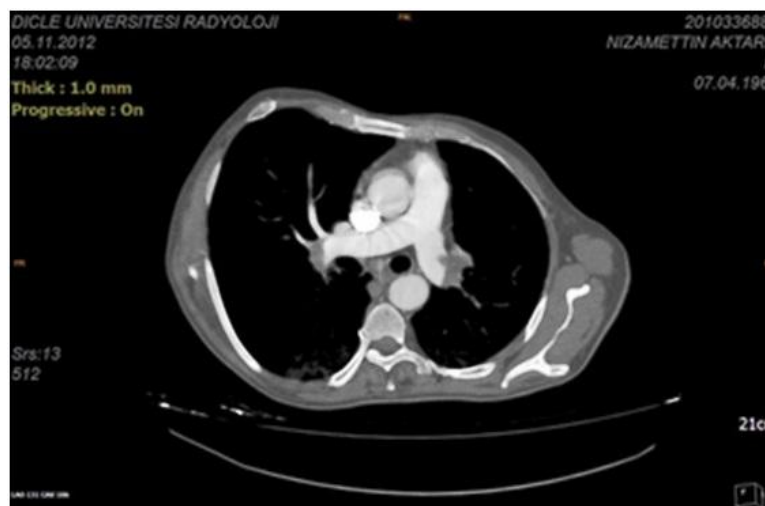


Figure 3 : Thorax CT of the case with increased liver size and hypodense lesion.

In literature review, patients with a diagnosis of PTE; the most common symptom is dyspnea and tachycardia with 38.4% ratio ^{12,13}, hypotension ratio is 16.5%, in arterial blood gas analysis the hypoxia ratio is 84.8% and in 63.6% of patients hypocapnia is available ^{10,12,13}. Symptoms and clinical findings in pulmonary thromboembolism can be also found in pneumonia table and may also cause skip of PTE. In our case, we did imaging with CTPA ¹⁴ thinking that the patient is PTE other than pneumonia, because we found the patient with deepening of breathlessness, the expansion of hypocapnia and existance of hypotension and risk factors for malignancy and imbolization, also high risk for Wells scoring and moderate risk for Genova scoring. The result was reported in accordance with massive pulmonary thromboembolism. In our view, pneumonia can overlap the diagnosis of PTE, can reduce the incidence of PTE and may result in fewer diagnoses.

In the findings of ICOPER study, the mortality ratio of first two weeks of pulmonary thromboembolism was 11.4% and mortality ratio of three months period was 17.4%. The mortality ratio goes up to 30-35% if the PTE is not cured ¹⁵. This ratio decreases when the patient is treated.

When we look at treatment options of massive PTE, the common idea is to give thrombolytic therapy. Studies on the comparison of thrombolytic agents, at the end of two hours infusion, recombinant tissue plasminogen activator of 100 mg led a significant improvement compared to other agents. But it was witnessed that the long-term risks were similar¹⁶⁻¹⁹. In recent studies the feedback on half dosage (50 mg) of recombinant tissue plasminogen activator provides full treatment. Also in our case, after giving half dosage of thrombolytic agent, bleeding was occurred, the most common complication of thrombolytic therapy, but the clinic condition of patient improved, and then transferred to the gastroenterology department again. We suggest half-dose treatment regime will be a treatment modality in the future.

In conclusion, pneumonia can overlap with the diagnosis of PTE. In clinical follow-up, pulmonary thromboembolism should be considered in the patients who have expansion of dyspnea, hypocapnia, hypoxia and hypotension. The early diagnosis and treatment is life saving in PTE. Immediately applied thrombolytic therapy is the most distinguished treatment in massive pulmonary thromboembolism.

References

1. Davidson BL (2000). Risk assessment and prophylaxis of venous thromboembolism in acutely and/or critically ill patients. *Haemostasis*, 30 (2): 77-81.
2. Goldhaber SZ, Visani L, De Rosa M (1999). Acute pulmonary embolism: Clinical outcomes in the International Cooperative Pulmonary Embolism Registry (ICOPER). *Lancet*, 353 (9162): 1386-1389.
3. Kasper W, Konstantinides S, Geibel A, Tiede N, Krause T, Just H (1997). Prognostic significance of right ventricular afterload stress detected by echocardiography in patients with clinically suspected pulmonary embolism. *Heart*, 77(4): 346-349.
4. Alpert JS, Smith R, Carlson J, Ockene IS, Dexter L, Dalen JE (1976). Mortality in patients treated for pulmonary embolism. *JAMA*, 236(13): 1477-1480.
5. Sandler DA, Martin JF (1989). Autopsy proven pulmonary embolism in hospital patients: Are we detecting enough deep vein thrombosis? *J R Soc Med*, 82(4): 203-205.
6. Neuhaus A, Bentz RR, Weg JG (1978). Pulmonary embolism in respiratory failure. *Chest*, 73(4): 460-465.
7. Khorana AA, Francis CW, Culakova E, Kuderer NM, Lyman GH (2007). Frequency, risk factors and trends for venous thromboembolism among hospitalized cancer patients. *Cancer*, 110(10): 2339-2346.
8. Blom JW, Doggen CJ, Osanto S, Rosendaal FR (2005). Malignancies, prothrombotic mutations, and the risk of venous thrombosis. *JAMA*, 293(6): 715-722.
9. Geerts W, Pineo G, Heit JA, Bergqvist D, Lassen MR, Colwell CW, et al (2004). Prevention of venous thromboembolism, the seventh ACCP conference on antithrombotic and thrombolytic therapy. *Chest*, 126(3): 338 - 400.
10. Şimşek A, Türkkän Ö, Melek K, Eyüboğlu FÖ (2010). Assessment of Patients with Pulmonary Thromboembolism (PTE) Diagnosed in Our Clinic: 5 Years Experience. *Tur Toraks Der*, 11: 149-154.
11. Casiato DA (2004). Hematologic complications. In: Casiato DA, Territo MA (eds). *Manual of Clinical Oncology*. 5th ed. Philadelphia: Lippincott Williams & Wilkins, 651-653.
12. Torbichi A, Perrier A, Konstantinides S, Agnelli G, Galiè N, Pruszczyk P, et al (2008). ESC Committee for Practice Guidelines (CPG). Guidelines on diagnosis and management of acute pulmonary embolism. Task Force on Pulmonary Embolism, European Society of Cardiology. *Eur Heart J*, 29(18): 2276 -2315.
13. PIOPED Investigators (1990). Value of the ventilation-perfusion lung scan in acute pulmonary embolism. *JAMA*, 263(20): 2753-2759.
14. Hasan Yiğit, Elif Ergün (2012). Pulmonary CT Angiography. *Türkiye Klinikleri J Radiol-Special Topics*, 5(3): 53-63.

15. Cushman M, Tsai A, Heckbert SR (2001). Incidence rates, case fatality, and recurrence rates of deep vein thrombosis and pulmonary embolus: the Longitudinal Investigation of Thromboembolism Etiology (LITE). *Thromb Haemost*, 86: 2349.
16. Meyer G, Sors H, Charbonnier B, Kasper W, Bassand JP, Kerr IH et al (1992). Effects of intravenous urokinase versus alteplase on total pulmonary resistance in acute massive pulmonary embolism: a European multicenter double-blind trial. The European Cooperative Study Group for Pulmonary Embolism. *J Am Coll Cardiol*, 19(2): 239–245.
17. Goldhaber SZ, Kessler CM, Heit J, Markis J, Sharma GV, Dawley D et al (1988). Randomised controlled trial of recombinant tissue plasminogen activator versus urokinase in the treatment of acute pulmonary embolism. *Lancet*, 2(8606): 293–298.
18. Meneveau N, Schiele F, Metz D, Valette B, Attali P, Vuilleminot A et al (1998). Comparative efficacy of a two-hour regimen of streptokinase versus alteplase in acute massive pulmonary embolism: immediate clinical and hemodynamic outcome and one-year follow-up. *J Am Coll Cardiol*, 31(5): 1057–1063.
19. Meneveau N, Schiele F, Vuilleminot A, Valette B, Grollier G, Bernard Y et al (1997). Streptokinase vs alteplase in massive pulmonary embolism. A randomized trial assessing right heart haemodynamics and pulmonary vascular obstruction. *Eur Heart J*, 18(7): 1141–1148.