



## CASE REPORT

### RADIONUCLIDE IMAGING IN DIFFERENTIAL DIAGNOSIS OF TORSION AND INFECTIONS OF TESTIS AND EPIDIDYMIS REVISITED

Yasemin Şanlı<sup>1</sup>, Işık Adalet<sup>1</sup>, Handan Tokmak<sup>1</sup>, Öner Şanlı<sup>2</sup>, Orhan Ziylan<sup>2</sup>, Sema Cantez<sup>1</sup>  
<sup>1</sup>Departments of Nuclear Medicine Medical Faculty of Istanbul, University of Istanbul <sup>2</sup>Departments of Urology, Medical Faculty of Istanbul, University of Istanbul

#### ABSTRACT

Differential diagnosis of acute scrotum especially with acute epididymis and testicular torsion should be made promptly, as testicular torsion is a true surgical emergency of the highest order. In this manuscript, two demonstrative cases introducing with acute scrotum and diagnosed with scintigraphy and color Doppler ultrasonography were presented to recall the knowledge.

**Keywords:** Testicular torsion, radionuclide imaging, color Doppler ultrasonography

### RADYONUKLİD GÖRÜNTÜLEME METODU İLE TESTİS TORSİYONU TEŞHİSİ VE TESTİS VE EPİDİDİMİS ENFEKSİYONLARI

#### ÖZET

Akut skrotumun ayırıcı tanısı özellikle akut epididimit ve testis torsiyonu için hızla yapılmalıdır. Çünkü testiküler torsiyon gerçek bir cerrahi acildir. Bu makalede akut skrotal ağrısı olan ve tanısında testis sintigrafisi ve Doppler Ultrasonografisi kullanılan iki vakayı sunmayı ve bu konudaki bilgileri gözden geçirmeyi amaçladık.

**Anahtar Kelimeler:** Testis torsiyonu, radyonüklid görüntüleme, renkli Doppler Ultrasonografi

## INTRODUCTION

Scrotal pain is an urgent condition that Urologists, Pediatricians and Pediatric surgeons frequently encounter and may have various etiologies. However, the most common two causes of this acute symptom are torsion of testicles and acute epididymitis. Differentiation of torsion from infections of testis and epididymis has a great importance because of the major differences in treatment modalities<sup>1</sup> Mostly, physical examination combined with color Doppler ultrasonography or testicular scintigraphy is used in differential diagnosis<sup>2,3</sup>. In this manuscript, we aimed to recall the utility of testicular scintigraphy in these two acute conditions using two cases.

## CASE REPORT

### Case 1

Twenty two years old white male presenting with right scrotal pain extending to the right inguinal region for 36 hours administered to our outpatient Urology clinic. Physical examination revealed right testicular tenderness and hyperemia in scrotal skin. Assessment with color Doppler

ultrasonography (CDU) demonstrated an heterogenous right testis with hypoechoic paranchyma. And vascularity was diminished in the body of testis but increased in the peritesticular area. Left testis was completely normal in physical examination and CDU. An immediate testicular scintigraphy was performed due to the insignificant evidence of the testicular torsion on CDU. While patient was in the supine position in the gamma camera, 10 mCi Tc-99 m O4 was injected intravenously and 60 frames for 2 seconds were taken as a dynamic study. After that, static images were recorded for 10 minutes. Testicular scintigraphy demonstrated an increased activity (perfusion) in the dynamical phase and a hypoactive center with a hyperactive hologram in the late static phase (Figure 1). Prompt scrotal exploration revealed the torsion of right testis with 540°, both testis and epididymis were purple (necrotic) in color and showed no bleeding or significant change in the color after detorsion. Cord was clamped and orchiectomy was performed (Figure 2).

#### İletişim Bilgileri:

Yasemin Şanlı

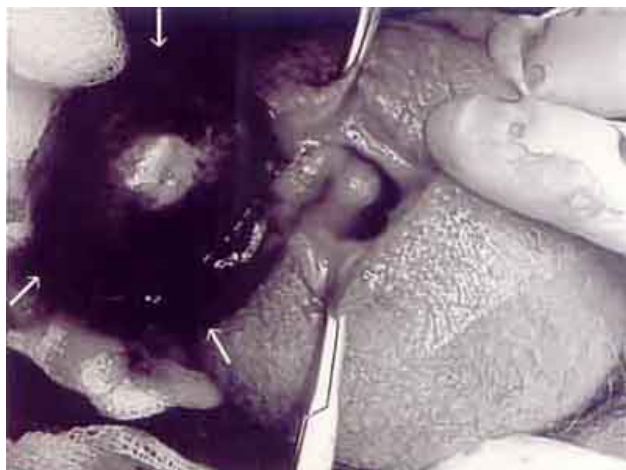
e-mail: [yaseminsanli75@yahoo.com](mailto:yaseminsanli75@yahoo.com)

Istanbul Tıp Fakültesi, Nükleer Tıp AD, Çapa, İstanbul

Marmara Medical Journal 2006;19(3);132-134



**Figure 1:** Testicular scintigraphy demonstrated an increased activity in the dynamical phase and a hypoactive center with a hyperactive hologram in the late static phase on the right testis.



**Figure 2:** Scrotal exploration revealed torsion of the testis with 540°, all testis and epididymis were purple in color (arrows).



**Figure 3:** In dynamic phase, the reactivity was increased in the area of the left testis compared with the other side. In the static phase, the activity was diffusely on the left testis (arrows)

## Case 2

An eight year old boy presenting with pain and tenderness in the left testicle administered to the outpatient clinic of department of Pediatric Surgery. His CDU revealed an expanded and heterogenous left testis and epididymis with a slightly increased vascularity. These findings were demonstrating an acute epididymo-orchitis. In order to confirm the diagnosis, testicular scintigraphy was performed. In dynamic phase, the activity was increased in the area of the left testis compared with the other side. In the static phase, the activity was diffusely increased on the left testis (Figure 3). This image was interpreted as epididymo-orchitis. He had received an antibiotic regimen for 10 days and his symptoms improved within a few days.

## DISCUSSION

Torsion is the twisting of the testis on the spermatic cord, resulting in strangulation of the blood supply and infarction of the testis. The patient usually presents with the sudden onset of pain and swelling of the involved testis. The pain may radiate through groin and abdomen. On physical examination, it is difficult to distinguish testis from epididymis because of localized swelling. For this reason the condition is frequently misdiagnosed as epididymitis. Therefore, imaging of the scrotum is very important for the diagnosis of the specific etiology of the patients presenting with acute scrotum. Prompt differential diagnosis should be made between acute testicular torsion and acute infections of testis and epididymitis, since torsion of the testicle is a true surgical emergency of the highest order. An immediate surgical exploration (and detorsion if needed) should be performed to the patients diagnosed with acute testicular torsion. Irreversible ischemic injury to the testicular parenchyma may begin as soon as 4 hours after occlusion of the cord<sup>4</sup>.

Color duplex ultrasonography has proved to be a valuable tool in the differential diagnosis of epididymis and torsion. This method uses visual color coding of flow velocities in blood vessels superimposed on the grey scale ultrasound to determine increases and decreases. Wilbert and colleagues found that CDU had a sensitivity of 82% and specificity of 100% for torsion<sup>5</sup>. In addition, the sensitivity and specificity for epididymis were found to be 70% and 88% respectively. False-negative CDU imaging in torsion was generally due to partial torsion with some residual blood flow in the testicle and



epididymitis. Thus, in this imaging modality, operator should be highly experienced. In our first case, diminished blood flow (not complete loss) was detected. However, specific etiology of the acute scrotum couldn't be diagnosed as testicular torsion, while the second case was diagnosed accurately as epididymo-orchitis.

Radionuclide scintigraphy of the scrotum is the most accurate method of differential diagnosis. Levy and colleagues found the study to have a positive predictive value of 75%, a sensitivity of 90% and specificity of 89%<sup>6</sup>. In the early phase of torsion (<5 to 7 hours after onset of symptoms) in which there is only a minimal edema or congestion and minimal or no reactive hyperemia in dartos, the angiographic phase of the scintigraphy demonstrates normal or diminished blood flow to the affected side. Static images taken for 5-10 minutes demonstrate a central photopenic defect in the involved hemiscrotum<sup>7</sup>. Inflammation has not yet occurred in the dartos, therefore no rim of activity is identified in the hemiscrotum. In missed torsion, the angiographic phase of the radionuclide scintigraphy may show normal or increased blood flow to the affected scrotum. Occasionally a nubbin sign may be present. This represents increased blood flow secondary to hyperemia in the dartos. Static images demonstrate a central photopenic defect with a variable degree of reactive hyperemia appearing as a rim of activity surrounding the testicle. The scan is interpreted as missed torsion because testicular viability has been jeopardised. On the other hand, in acute epididymitis, the radionuclide angiogram shows increased perfusion to the affected hemiscrotum. If the inflammation involves only the epididymis, radionuclide activity is seen principally at the superolateral pole of the testis and if inflammation

has progressed to involve the entire scrotum (epididymo-orchitis), the entire hemiscrotum will have increased activity when compared with the contralateral side<sup>7</sup>. Likewise in the second case, diagnosis of left epididymo-orchitis was supported by scintigraphic findings.

In conclusion, evidence from literature reveals that sonography and scintigraphy show similar sensitivity for diagnosing testicular torsion. One should keep in mind that, false negatives of sonography which is inherently operator dependent, may be compensated with scintigraphy.

## REFERENCES

1. Schneck FX, Bellinger MF, Abnormalities of the testes and scrotum and their surgical management. In: Retik AB, Vaughan ED Jr, Wein AJ (eds). Campbell's Urology. Philadelphia: Saunders 2002: 2353-2394.
2. Nussbaum Blask AR, Bulas D, Shalaby-Rana E, Rushton G, Shao C, Majd M. Color Doppler sonography and scintigraphy of the testis: a prospective, comparative analysis in children with acute scrotal pain. *Pediatr Emerg Care* 2002;18: 67-71.
3. Wu H, Sun SS, Kao A et al, Comparison of radionuclide imaging and ultrasonography in the differentiation of acute testicular torsion and inflammatory testicular disease. *Clin Nuc Med* 2002; 27: 490-493.
4. Bartsch G, Frank S, Marberger H, Mikuz G. Testicular torsion: late results with special regard to fertility and endocrine function. *J Urol* 1980; 124: 375-378.
5. Wilbert DM, Schaerfe CW, Stern WD, Strohmaier WL, Bichler KH Evaluation of the acute scrotum by color-coded Doppler ultrasonography. *J Urol* 1993; 149: 1475-1477.
6. Levy OM, Gittelman MC, Strashun AM, Cohen EL, Fine EJ. Diagnosis of acute testicular torsion using radionuclide scanning. *J Urol* 1983; 129: 975-977.
7. Beltran MR, Testicular Imaging. In: Henkin RE, Boles MA, Dillehay CL (eds). *Nuclear Medicine Vol II*. Mosby-Year book, Inc. 1996: 1110-1121.