

# Diagnosis and Treatment of Giant Inguinoscrotal Bladder Hernia

Dev İnguinoskrotal Mesane Fıtığı Tanı ve Tedavisi  
Hasan TURGUT<sup>1,2</sup>, Serkan TAYAR<sup>3</sup>, Güner Kemal ÖZGÜR<sup>2</sup>

<sup>1</sup> Avrasya University, Faculty of Health Science, Trabzon, Turkey

<sup>2</sup> Medicalpark Karadeniz Hospital, Department of Urology, Trabzon, Turkey

<sup>3</sup> Medicalpark Karadeniz Hospital, Department of General Surgery, Trabzon, Turkey


Yazışma Adresi / Correspondence


**Serkan TAYAR**

Medicalpark Karadeniz Hospital, Department of General Surgery, Trabzon, Turkey

Geliş Tarihi / Received : 18.8.2022 Kabul Tarihi / Accepted: 27.9.2022



 Hasan TURGUT <https://orcid.org/0000-0001-9793-6734> [dr.hasanturgut@hotmail.com](mailto:dr.hasanturgut@hotmail.com)

 Serkan TAYAR <https://orcid.org/0000-0001-5174-2416> [tayarserkan61@hotmail.com](mailto:tayarserkan61@hotmail.com)

 Güner Kemal ÖZGÜR <https://orcid.org/0000-0002-4018-3812> [gkozgur@gmail.com](mailto:gkozgur@gmail.com)

*Hippocrates Medical Journal / Hippocrates Med J 2023, 3(2):90-94 DOI: <https://doi.org/10.58961/hmj.1158603>*

## Abstract

Inguinoscrotal bladder hernia is rarely seen, and diagnosis is often made intraoperatively as urological symptoms are uncommon. In this case report, the diagnosis and treatment of a patient with an inguinoscrotal bladder hernia is presented. A 67-year-old male patient presented with complaints of right inguinal pain and incomplete urine voiding for about two years. Physical examination revealed a giant incarcerated bladder hernia descending into the right inguinal canal and scrotum. Computed tomography showed a right inguinal hernia, including the bladder, accompanied by hydrocele. Open surgery was performed on the patient. The urinary bladder was sent to the intra-abdominal cavity, then the hernia and hydrocele were repaired. The patient was discharged on postoperative day three without complications. In the postoperative follow-up of the patient, his wound had a normal appearance, and he had no urinary symptoms.

**Keywords** Hernia, Operative therapy, Urinary bladder.

## Özet

İnguinoskrotal mesane fıtığı nadiren görülür ve ürolojik semptomlar nadir olduğundan tanı sıklıkla intraoperatif olarak konur. Bu olgu sunumunda inguinoskrotal mesane fıtığı olan bir hastanın tanı ve tedavisi sunulmaktadır. 67 yaşında erkek hasta yaklaşık iki yıldır sağ kasık ağrısı ve kesik idrar yapma şikayetleri ile başvurdu. Fizik muayenede sağ inguinal kanala ve skrotuma inen, dev bir inkansere mesane fıtığı saptandı. Bilgisayarlı tomografide hidroselin eşlik ettiği mesaneyi içeren sağ kasık fıtığı görüldü. Hastaya açık cerrahi uygulandı. Mesane karın içi boşluğa gönderildi, ardından fıtık ve hidrosel onarıldı. Hasta postoperatif 3. günde komplikasyonsuz taburcu edildi. Hastanın postoperatif takibinde yarası normal görünümdeydi ve üriner semptomu yoktu.

**Anahtar Kelimeler** Fıtık, Operatif tedavi, Mesane.

## INTRODUCTION

In surgery clinics, inguinal hernia repair is one of the most common operations in adults. Based on location, inguinal hernias can mainly be categorized as indirect, direct, and femoral (1). The inguinal hernia frequently contains the omentum and small intestine. The unusual hernia contents were the appendix, ovary, fallopian tubes, urinary bladder, Meckel's diverticulum, and sigmoid colon (2-4). Although anatomically close to the inguinal canal, hernia of the urinary bladder to the inguinal canal is extremely rare. Levine first described urinary bladder hernia (UBH) in 1951 as scrotal cystocele (5). UBH is usually seen in obese males aged over 50 years (2). Risk factors include male gender, advanced age, chronic urinary obstruction, pelvic muscle weakness, and obesity (6).

The diagnosis of UBH is challenging because most patients are asymptomatic. Preoperative diagnosis is made in only 7% of UBHs; most cases are diagnosed perioperatively. Due to unexpected surgery diagnoses, bladder injury and urinary leakage are present in approximately 16% of the patients (7). The standard treatment is hernia repair following bladder reduction; less often, hernia repair can be applied after bladder resection (8).

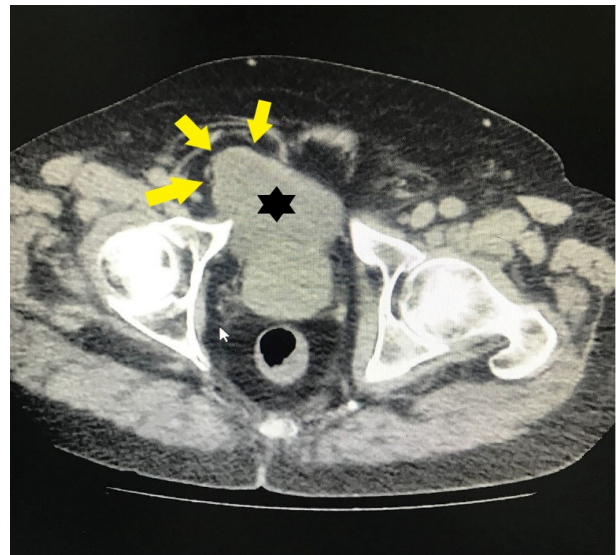In this case report, the diagnosis and treatment of a patient with an inguinoscrotal bladder hernia is presented.

## CASE REPORT

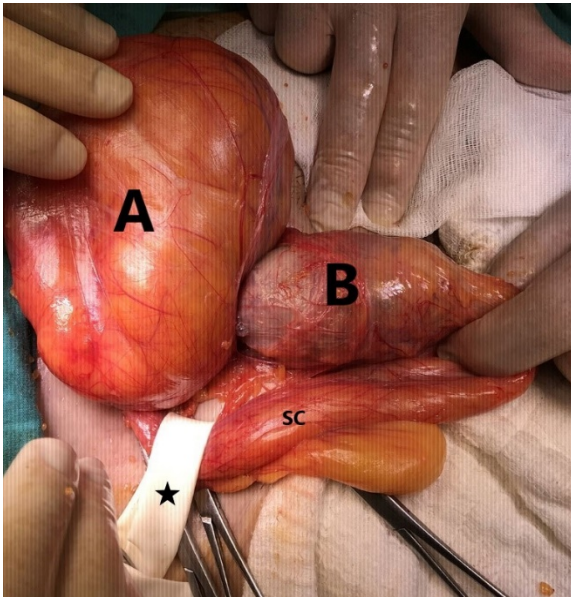
A 67-year-old male was admitted to the urology outpatient clinic of a tertiary health center with right inguinal pain and incomplete urine voiding for approximately two years. He used manually squeezing the scrotum to void the urinary bladder. The patient with a body mass index of 23 kg/m<sup>2</sup> had only hypertension controlled by anti-hypertensive drugs. In addition, he had no history of smoking or previous surgery. In the abdominal physical examination, swelling descending towards the right inguinal canal and scrotum was detected, which was evaluated as a giant incarcerated UBH. The abdomen examination was comfortable on palpation.

The patient's hematological, biochemical, renal function tests and urinary analysis were unremarkable in the laboratory. The total serum prostate-specific antigen level was 1.54 µg/L (normal range=0-4 µg/L). On ultrasonography, it was observed that the bladder was displaced towards the right inguinal canal. In addition,

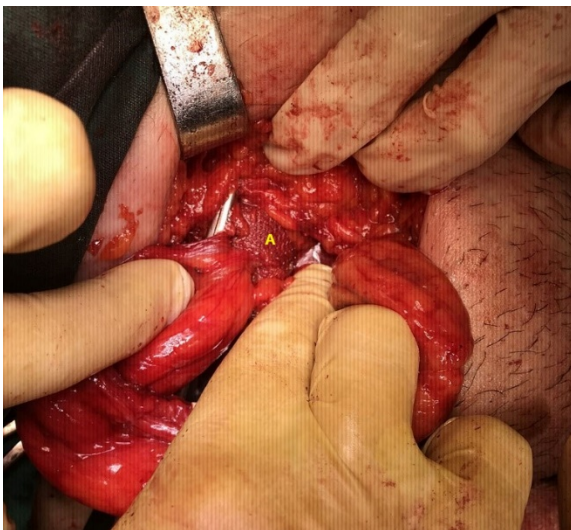hydrocele and giant inguinal hernia were present, and prostate volume was 50 cc. Uroflow was planned for the patient, but the patient did not accept it. Computed tomography (CT) was scheduled for the patient to investigate the presence of additional abdominal pathology. CT revealed a right-side inguinal hernia containing a portion of the bladder, and fluid consistent with hydrocele was observed in the right scrotum (Figure 1).



**Figure 1.** Axial CT scan shows the urinary bladder (black asterisk) intraperitoneally and a part of the bladder herniating through the right inguinal groin (yellow arrows). The urinary bladder is stretched into the right inguinal hernia.



**Figure 2.** Operatively, the bladder was filled with sterile saline (A), the Penrose drain (asterisk) passed under the spermatic cord (SC), and the testis with hydrocele is shown by 'B'.



**Figure 3.** After placement of the bladder in the abdomen, hernia repair was applied with a polypropylene mesh (A).

The patient was followed-up in the service during the postoperative period. On postoperative day 1, there was

minimal pain in the wound site. As the wound site was dry and clean and there was no discharge from the drain, it was removed on postoperative day 1. On postoperative day 2, the urinary catheter was removed. The patient was discharged on postoperative day three without complications. At the follow-up examination on postoperative day 10, his wound was normal in appearance, and he had no urinary symptoms.

## DISCUSSION

Urinary bladder hernias (UBHs) constitute up to 1-4% of all inguinal hernias, are more often seen on the right side, and are seen in males 10-fold more than in females (9, 10). Bladder outlet obstruction, reduced bladder tone, chronic distended bladder, weak pelvic wall muscles, and obesity may be responsible for the pathophysiology (11). Generally, there is bladder distension associated with bladder outlet obstruction, the bladder expands because of weakness in the bladder and abdominal walls, and a hernia develops from the inguinal canal (12). In the current male patient with right-side UBH, other than weakness in the abdominal wall, no other pathology could be determined from the risk factors.

Small UBHs are usually asymptomatic, whereas, in large inguinoscrotal UBHs, there may be groin pain or lower urinary tract symptoms (LUTS). Symptomatic patients may show different clinical signs. These symptoms in the inguinal region associated with UBH include pain, swelling, and LUTS. LUTS is usually related to bladder obstruction and infection and may also present with dual voiding (9). Together with contraction of the bladder in first urination, there is normal urination and second urination is with manual contraction of the scrotum (11). This type of dual voiding was the complaint of the present patient.

Although there are different diagnostic methods, USG is the first and most often used method. A hypogenic mass from the bladder towards the inguinal canal may be seen on USG. Voiding cystourethrography is the best diagnostic method, and the bladder appearance may be in the form of a dog ear in the scrotum (9). Patients who are obese, >50 years of age, have inguinal swelling, and LUTS are indicated for CT (11). The standard treatment for UBH is hernia



repair, including bladder reduction and occasionally hernia repair requiring bladder resection and midline laparotomy.

This procedure can be applied as an open surgery or laparoscopically (13). However, there is no consensus about which approach is the best. Patient's conditions, comorbidities, surgeon's experience, and hernia defect are important factors to choose surgery method (11). It should be keep in mind that larges hernias with large rings are susceptible for incarceration (14). In the present patient, USG was used as the first diagnostic tool. USG showed that the bladder was displaced towards the right inguinal canal with a giant inguinal hernia. Uroflow was planned for the patient, but the patient did not accept it. CT revealed a right-side inguinal hernia containing a portion of the bladder, and fluid consistent with hydrocele was observed in the right scrotum. Open surgery was preferred because the patient had a large hernia and accompanying hydrocele.

### CONCLUSION

UBH is an extremely rarely seen pathology, and it should be considered in patients aged > 50 with inguinal pain and swelling. Most patients had asymptomatic clinics and were detected during surgery. USG is the first and most often used method, but patients who are obese, >50 years of age, have inguinal swelling, and LUTS are indicated for CT. The standard treatment for UBH is hernia repair, including bladder reduction and occasionally hernia repair requiring bladder resection.

Funding: No funding declared. Patient oral permission granted.

Conflicts of interest/Competing interests: All authors no conflict of interest/competing interests.

## References

1. Kalayci T, İliklerden Ü, Kotan M. Factors Affecting Morbidity, Mortality, and Recurrence in Incarcerated Femoral Hernia. *J Coll Physicians Surg Pak.* 2022;32(2):213-9.
2. Taskovska M, Janež J. Inguinal hernia containing urinary bladder-a case report. *Int J Surg Case Rep.* 2017;40:36-8.
3. Goyal S, Shrivastva M, Verma R, Goyal S. Uncommon contents of inguinal hernial sac: a surgical dilemma. *Indian J Surg.* 2015;77(2):305-9.
4. Kalayci T, İliklerden ÜH. Management of incidental Amyand hernia with a case report. *East J Med.* 2019;24(4):551-3.
5. Levine B. Scrotal cystocele. *J Am Med Assoc.* 1951;147(15):1439-41.
6. Habib A. A rare case of inguinal hernia with complete bladder herniation. *Case Rep Surg.* 2017; Article ID 4658169.
7. Khan K, Chaudhry A, Feinman MB. Inguinoscrotal hernia containing the urinary bladder. *Case Rep.* 2016;2016:bcr2016217408.
8. Ugur M, Atci N, Oruc C, Akkucuk S, Aydogan A. Case report: Left inguinal bladder hernia that causes dilatation in the ureter. *Arch Iran Med.* 2016;19(5):376-8.
9. Madani AH, Nikouei HM, Aval HB, Enshaei A, Asadollahzade A, Esmaeili S. Scrotal herniation of bladder: a case report. *Iran J Med Sci.* 2013;38(1):62-4.
10. Kartal M. Isolated Herniation of the Bladder into the Inguinal Canal: A Rare Case Report. *J Res Clin Med.* 2021;9(1):23-5.
11. Moufid K, Touiti D, Mohamed L. Inguinal bladder hernia: four case analyses. *Rev Urol.* 2013;15(1):32-6.
12. Yong GL, Siaw MY, Yeoh AJL, Lee GEG. Inguinal bladder hernia: case report. *Open J Urol.* 2013;3(5):217-8.
13. François J, Defoort B, Muysoms F. Complicated inguinoscrotal bladder hernia: a case of two-step repair. *Acta Chirurgica Belgica.* 2017;117(2):122-4.
14. Bisharat M, O'Donnell M, Thompson T, MacKenzie N, Kirkpatrick D, Spence R, et al. Complications of inguinoscrotal bladder hernias: a case series. *Hernia.* 2009;13(1):81-4.