



CASE REPORT

ENDOSCOPIC REMOVAL OF FRONTOETHMOID OSTEOMA: A CASE REPORT

Murat Sarı, Tekin Bağlam, Zahide Mine Yazıcı, Cüneyd Üneri

Department of Otorhinolaryngology, School of Medicine, Marmara University, Istanbul, Turkey

ABSTRACT

Osteoma is the most common benign tumor of the nose and paranasal sinuses. Most commonly seen in the frontal sinus, it is less common in the ethmoid and maxillary sinuses. This tumor may be discovered incidentally on radiographs, or may grow enough to produce symptoms. Rarely, complications occur at its location near the orbit and anterior skull base. We present a case of frontoethmoid osteoma treated by endoscopic resection, and we emphasise the advantages of this minimally invasive method compared with traditional methods.

Keywords: Osteoma, Frontoethmoid region, Endoscopic approach

FRONTOETHMOID OSTEOMANIN ENDOSKOPİK YAKLAŞIMLA ÇIKARILMASI

ÖZET

Osteoma burun ve paranasal sinüslerin sık görülen benign tümördür. Sıklıkla frontal sinüste, daha nadir olarak etmoid ve maksiler sinüslerde görülür. Bu tümör radyografilerde rastlantısal olarak tespit edilebildiği gibi semptom oluşturacak kadar büyüyebilir ve nadiren orbita ve ön kafa kaidesine yakınlığı nedeniyle komplikasyonlara neden olabilir. Endoskopik rezeksiyon yöntemi ile tedavi edilen bir frontoethmoid osteoma olgusunu sunduk ve bu minimal invazif tekniğin geleneksel yöntemlere göre belirgin avantajlarını vurguladık.

Anahtar Kelimeler: Osteoma, Frontoethmoid bölge, Endoskopik yaklaşım

INTRODUCTION

Paranasal sinus osteoma is a slow-growing, benign, encapsulated bony tumor that may be commonly asymptomatic, being detected incidentally in 1 % of plain sinus radiographs or in 3 % of sinus computerized tomographic scans¹⁻³. The true incidence of these tumors is unclear, since they are frequently asymptomatic and diagnosed incidentally⁴. Osteomas usually present between the fifth and sixth decades of life. There is a slight male predominance, with ratios varying from 1.3:1 to 3:1⁵. The greater preponderance of sinus osteomas in men is attributed to men's greater exposure to trauma and the large size of their sinuses⁶. Paranasal sinus osteomas may sometimes be a component of Gardner's syndrome, an autosomal dominant disease, characterized by intestinal poliposis and bone and skin lesions⁷.

There are several theories regarding the origin of osteomas. The embryological theory postulates that osteomas arise at the junction of the embryonic cartilagenous ethmoid and membranous frontal bones. But we know that

many osteomas arise at sites distant from this junction⁸. Sinusitis has been suspected in the etiology of osteoma formation, but the incidence of osteoma and infection do not correlate^{5,9}. Trauma is another factor blamed in the formation of osteomas. However, many patients lack a history of trauma⁸.

Two different histopathologic types of osteoma have been described. Firstly, the ivory osteoma, composed of dense bone with only a minimal amount of fibrous tissue and secondly, the osteoma spongiosum, containing mature cancellous bone. Occasionally, a third variety called "mixed" osteoma contains features of both two^{4,8,10}.

Although plain films play a role in the diagnosis of paranasal sinus osteomas, they do not give sufficient information. Computed tomography (CT) scan is the suggested method for determining the regional anatomy and the extent of the lesion. One should consider other fibroosseous lesions of the paranasal sinuses in the differential diagnosis. These lesions include fibrous osteoma, fibrous displasia, and ossifying fibroma¹¹.

Corresponding author: Murat Sarı
Department of Otorhinolaryngology,
School of Medicine, Marmara University Hospital,
Tophanelioğlu Caddesi, No/13/15, Altunizade 81190, İstanbul, Turkey.
E-mail: muratsari@hotmail.com Tel: +90 216 327 8294 Fax: +90 216 326 9637

Marmara Medical Journal 2005;18(1);39-42



CASE REPORT

A 28-year-old female patient presented with a 1-year history of left-sided facial and frontal pain. There was no history of trauma, nasal surgery, or major paranasal sinus infection. Nasal endoscopy revealed nothing abnormal. The remainder of the head and neck examination was unremarkable. Subsequent computed tomography (CT) scan of the paranasal sinuses revealed an extremely dense lesion located in the left frontoethmoid region (Fig.1). Both anterior and posterior ethmoid cells were affected by the lesion. There was no significant secondary sinusitis. The lesion extended to orbita and skull base without invading them. These findings strongly suggested an osteoma. The patient consented to endoscopic removal of the mass. The possibility of intraoperative need for an open approach was also discussed with the patient.

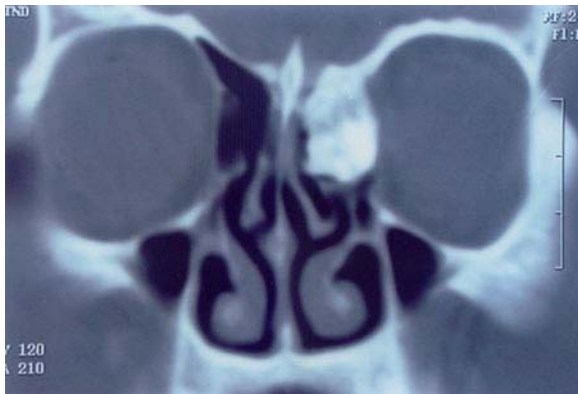

Fig. 1: Preoperatif coronal computed tomography scan showing an osseous mass in the left frontoethmoid region

The operation was performed under general anesthesia using endotracheal intubation. The patient is placed in the supine position with the head slightly elevated and turned towards the surgeon. The face was disinfected properly. Pledgets soaked with 1:1000 epinephrine were applied to the middle meatal area. Ten minutes after application, the pledgets were removed. The middle turbinate was subluxed medially to allow adequate visualization of the middle meatus. After uncinectomy, ethmoid bulla was opened and the whitish osteoma appeared. The osteoma was completely mobilized using a freer elevator. The middle turbinate was partially resected and then the mass was removed with a forceps. A gross specimen is shown in Fig 2. After control of minor hemorrhage, the area was inspected and there was no CSF leakage. Merocel packing was applied.

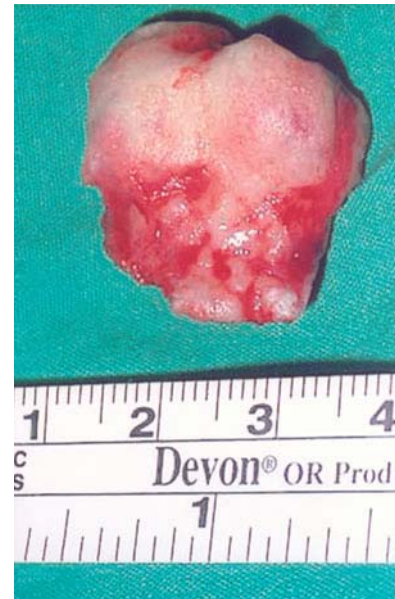

Fig. 2: Macroscopic appearance of the frontoethmoid osteoma after resection (2,5x2x2 cm)

The patient's postoperative course was uneventful. She was discharged on the first postoperative day. The nasal packing was removed on the third postoperative day. The patient subsequently made a complete and uneventful recovery. Histologic examination after decalcification showed typical benign osteoma. Postoperatively, control CT scanning showed no residual disease. (Fig.3).

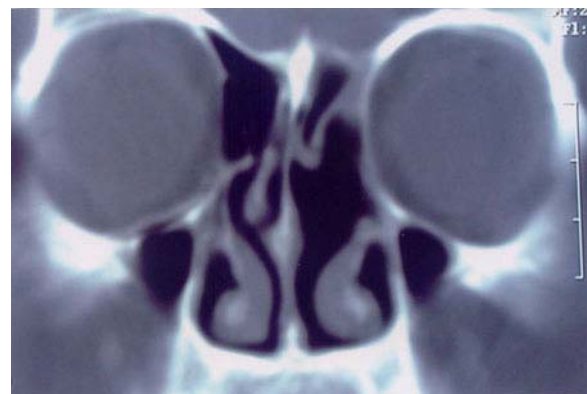


Fig. 3: Postoperatif coronal computed tomography 6 months after surgery revealed no residual tumor

DISCUSSION

The clinical presentation of paranasal osteomas covers a broad spectrum. Most of the paranasal sinus osteomas are asymptomatic due to their slow growth rate. When they produce symptoms, headache or facial pain localized over the area of osteoma is the most common one¹². Other symptoms include facial deformity, anosmia,



rhinorrhea or secondary sinusitis². They may also produce orbital or intracranial complications when they extend beyond the confines of the sinuses. Orbital symptoms include diplopia, proptosis, exophthalmus, and vision changes^{7,12,13}. Neurologic complications such as subdural abscess, meningitis, and intracranial pneumocele are also reported^{10,14-17}. Symptoms are generally related to the location, size and growth rate of the osteoma.

It is generally agreed that asymptomatic osteomas without intracranial, or orbital extension, or cosmetic deformity require no treatment^{6,10}. These should be followed up with serial radiographs to determine any change in size. Surgical removal for osteomas enlarging rapidly, extending beyond the confines of the sinus, filling more than 50 % of the volume of frontal sinus is suggested by Savic and Djeric in 1990¹. They also recommend removal of osteomas associated with unexplained headache, recurrent sinusitis, ocular symptoms, central nervous system symptoms, and those that are located near the frontal sinus ostium or those causing cosmetic deformity¹. Unlike others, sphenoid osteomas should be removed immediately, as their slow progressive growth can cause loss of vision due to compression of visual pathways⁶.

External surgical procedures have been the method of choice in the treatment of paranasal sinus osteomas¹⁸. Various surgical approaches for osteomas have been described, including osteoplastic flap technique, lateral rhinotomy, and direct anterior surgical approach. Although all these techniques are effective in certain conditions, they bear some disadvantages like permanent scar formation, blood loss, mucocele formation, and paresthesias^{8,19}.

Recently, endonasal endoscopic sinus surgery offers a minimally invasive alternative in the treatment of paranasal sinus osteomas. Lesions limited to sinuses without evidence of orbital or intracranial extension, are suitable for this treatment. The endoscopic approach offers marked advantages over the traditional open techniques. These are, excellent cosmetic results without any external incision, shorter duration of operative time, and early discharge from hospital. It also allows closer and more direct visualization during operation². Normal sinonasal functioning can be expected after the initial period of healing. In this case, our patient was appropriately treated by endonasal endoscopic technique without any complication, and was spared more aggressive open procedures. The cosmetic result was also

more appealing, with no external incision present. The hospital stay was shorter, and the postoperative care was similar to that of any other patient undergoing endoscopic sinus surgery.

We present a case of frontoethmoid osteoma successfully managed by endoscopic sinus techniques, and describe the marked advantages of this technique compared with traditional methods in selected cases. We believe that endoscopic approach in the treatment of paranasal sinus osteoma is a viable technique in the absence of significant orbital extension or skull base invasion. Although it is a safe technique, meticulous care and patience is necessary to prevent potential complications such as cerebrospinal fluid leakage and loss of vision.

REFERENCES

1. Savic DL, Djeric DR. Indications for surgical treatment of osteomas of the frontal and ethmoid sinuses. *Clin Otolaryngol* 1990;15:397-404.
2. Huang HM, Liu CH, Lin KN, Chen HAT. Giant ethmoid osteoma with orbital extension, a nasoendoscopic approach using an intranasal drill. *Laryngoscope* 2001;111:430-432.
3. Brunori A, Bruni P, Delitala A, Greco R, Chiappetta F. Frontoethmoid osteoma complicated by intracranial mucocele and hypertensive pneumocephalus: case report. *Neurosurgery* 1995;36:1237-1238.
4. Ataman M, Ayas K, Gürsel B. Giant osteoma of the frontal sinus. *Rhinology* 1993;31:185-187.
5. Menezes CO, Davidson TM. Endoscopic resection of a sphenoid osteoma. *Ear Nose Throat J* 1994;73: 598-600.
6. Mansour AM, Salti H, Uwaydat S, Dakroub R, Bashshour Z. Ethmoid sinus osteoma presenting as epiphora and orbital cellulitis: case report and literature review. *Surv Ophthalmol* 1999;43:413-426.
7. Hehar SS, Jones NS. Fronto-ethmoid osteoma: the place of surgery. *J Laryngol Otol* 1997;111: 372-375.
8. Seiden AM, El Hefny YI. Endoscopic trephination for the removal of frontal sinus osteoma. *Otolaryngol Head Neck Surg* 1995;112:607-611.
9. Smith ME, Calcaterra TC. Frontal sinus osteoma. *Ann Otol Rhinol Laryngol* 1989;98:896-900.
10. Al-Sebei K, Desrosiers M. Bifrontal endoscopic resection of frontal sinus osteoma. *Laryngoscope* 1998;108:295-298.
11. Margo CE, Weiss A, Habal MB. Psammomatoid ossifying fibroma. *Arch Ophthalmol* 1986;104:1347-1351.
12. Atallah N, Jay MM. Osteomas of the paranasal sinuses. *J Laryngol Otol* 1981;95:291-304.
13. Koivunen P, Lopponen H, Fros AP, Jokinen K. The growth rate of osteomas of the paranasal sinuses. *Clin Otolaryngol* 1997;22:111-114.
14. Shady JA, Bland LI, Kazee AM, Pilcher WH. Osteoma of the frontoethmoidal sinus with secondary brain abscess and intracranial mucocele: case report. *Neurosurgery* 1994;34: 920-923.
15. Koyuncu M, Belet U, Sesen T, Tanyeri Y, Simsek M. Huge osteoma of the frontoethmoidal sinus with secondary brain abscess. *Auris Nasus Larynx* 2000; 27: 285-287.



16. Shick B, Steigerwald C, el Rahman el Tahan A, Draf W. The role of endonasal surgery in the management of frontoethmoidal osteomas. *Rhinology* 2001; 39: 66-70.
17. Schwartz MS, Crockett DM. Management of a large frontoethmoid osteoma with sinus cranialization and cranial bone graft reconstruction. *Int J Pediatr Otorhinolaryngol* 1990; 20:63-72.
18. Önerci M, Hosal S, Korkmaz H. Nasal osteoma: a case report. *J Oral Maxillofac Surg* 1993;51:423-425.
19. Akmansu H, Eryilmaz A, Dagli M, Korkmaz H. Endoscopic removal of paranasal sinus osteoma: A case report. *J Oral Maxillofac Surg* 2002;60:230-232.