



CASE REPORT

A SCLERAL MELTING AFTER INTRAOCULAR SURGERY

Özlem Yenice, Haluk Kazokoğlu, Ebru Toker

Department of Ophthalmology, School of Medicine, Marmara University, Istanbul, Turkey

ABSTRACT

A 51-year-old male with a diagnosis of idiopathic uveitis underwent cataract surgery. After cataract surgery, cystoid macular edema developed which did not resolve with medical therapy. Vitrectomy was performed due to persistence of cystoid macular edema and severe condensation of the anterior vitreous. At postoperative 1 month, scleral melting was detected at sclerotomy side which was repaired with heterolog scleral grafting.

Keywords: Uveitis, Vitrectomy, Scleral melting

GÖZ İÇİ CERRAHİ SONRASI BİR SKLERAL ERİME

ÖZET

İdiopatik üveit tanısı olan 51 yaşındaki erkek hastanın, sol gözüne katarakt cerrahisi uygulandı. Katarakt cerrahisi sonrası, medikal tedavi ile gerilemeyen kistoid maküla ödemi gelişti. Kontrollerde, ödemin sebat etmesi ve ön vitreusta yoğun kondensasyon gelişmesi nedeni ile vitrektomi uygulandı. Vitrektomi sonrası 1 ayda, alt temporal bölgedeki sklerotomi bölgesinde skleral erime tespit edildi ve o bölge heterolog sklera greftiyle onarıldı.

Anahtar Kelimeler: Üveit, Vitrektomi, Sklera erimesi

INTRODUCTION

The most common postoperative findings for visual acuity limitation in uveitic eyes that undergo cataract surgery are macular disorders¹⁻⁵. Vitrectomy is usually recommended if there is vitreous opacities with cystoid macular edema (CME) unresponsive to medical therapy, vitreous cells or debris sufficient to prevent 0.5 vision postoperatively or hypotony with a cyclitic membrane⁵⁻⁸. Although several complications have been reported after vitrectomy in patients with uveitis, scleral melting is very rare⁹. Scleral melting is usually reported in the eye after pterygium operations with bare sclera technique and anti-metabolite use due to infectious causes¹⁰⁻¹³.

Here we report, non-infectious scleral melting of an unknown cause in a case with uveitis after vitrectomy who had been operated for refractive cystoid macular edema and vitreous condensation.

CASE REPORT

A 52-year-old man who was being followed in our uvea department with a diagnosis of idiopathic uveitis, had undergone cataract surgery. Before

the operation his left eye was quiescent for a period of two months. His visual acuity improved from 0.1 to 0.5 after cataract surgery. Later he had a gradual decrease in visual acuity and his clinical evaluation with fundus fluorescein angiography showed cystoid macular edema in his left eye. He was first put on medical therapy (prednisolone acetate 1% every hour for a month then four times a day for 3 months and subtenon triamcinolone acetonide injection 40 mg and oral prednisone 40 mg/day for 1 month) for up to 16 weeks. His visual acuity improved to 0.2 but the control angiography revealed persistence of CME. Meanwhile patient developed moderate to severe anterior vitreous condensation which limited us to see details of posterior fundus. The patient then underwent pars plana vitrectomy due to persistence of CME and vitreous opacities. Control examinations at first week showed improvement of visual acuity (0.6). In the first control after vitrectomy the visual acuity was still 0.6. but conjunctiva was extensively hyperemic and sclera was severely thinned inferotemporally (5x4 mm) where gray to brown choroid reflex could be seen (Fig.1). After taking specimen for microbiological culture, intensive topical

Corresponding author: Özlem Yenice, M.D.
Department of Ophthalmology School of Medicine,
Marmara University Hospital, Altunizade, Istanbul, Turkey.
E-mail: yeniceozlem@yahoo.com

Marmara Medical Journal 2005;18(2);84-86



antibiotic treatment was initiated. Direct cultures (Gram and Giemsa) were negative. His clinical (negative history for arthralgia, sacroiliac pain or oral ulcer) and laboratory evaluations (RF, P-ANCA, HLA B5, HLA B27, ppd) were all non contributory. The patient was then immediately reoperated and thinned and melted sclera was grafted with heterolog sclera patch (Fig.2). Peroperatively, excisional biopsy was performed which revealed focal superficial ulceration with infiltration of polymorphonuclear leukocytes.

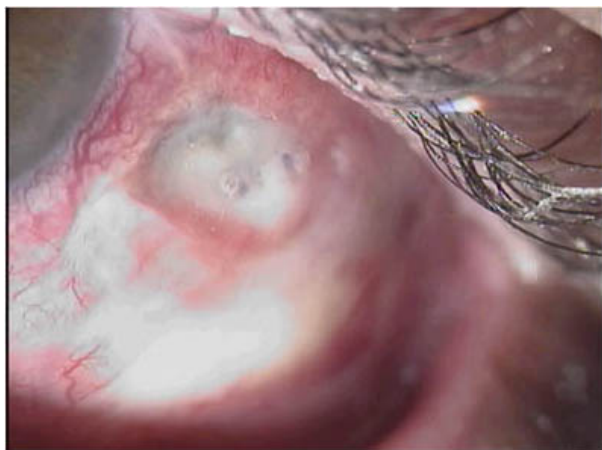


Fig. 1: Sclera is excessively thinned at inferotemporal region (arrow).

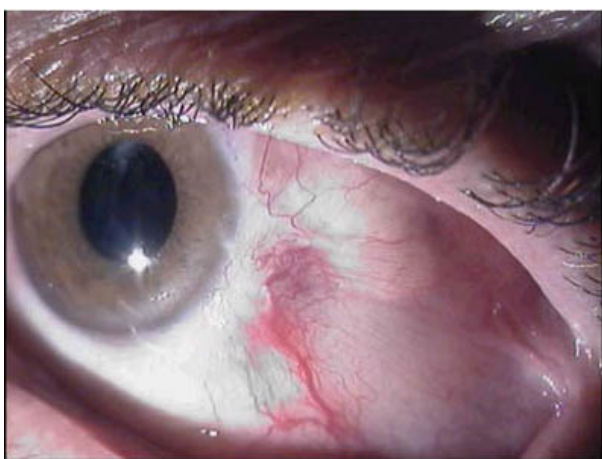

Fig. 2: Thinned scleral area six months after repairing with graft. Conjunctiva is epithelised over the grafted area.

DISCUSSION

Cataracts are common complications of uveitis. Their removal is often indicated for visual rehabilitation and to allow assessment and management of posterior segment pathology. But the incidence of some cataract surgery related complications including CME, prolonged inflammation, glaucoma, posterior capsular opacification, capsular contraction and

perilenticular membrane formation increase in patients with uveitis. Among these CME is the most common reason for decreased vision⁴. Rare cases with CME require surgical treatment when medical treatment is inadequate. It has been reported previously that pars plana vitrectomy is effective in the treatment of prolonged CME due to complicated or uncomplicated cataract surgery⁶⁻⁸. In the treatment of CME developing after intraocular surgery in patient with chronic uveitis, vitrectomy should be considered in those with prominent morphological changes and chronic inflammation together with vitreous condensation or presence of inflammatory cells within the vitreous.

The most common reported complications, developing after vitrectomy in cases with uveitis are tractional or rhegmatogenous retinal detachment, glaucoma and epiretinal membrane formation^{6,7}. Among these complications there are also some few those related with sclerotomy sites during standard pars plana vitrectomy. These are although very uncommon in hands of well experienced surgeons, include synechiae of the fibrovascular tissue to the sclerotomy site due to inadequate cleaning of the sclerotomy area, vitreous incarceration or exposure of the sutures at the sclerotomy sites^{14,15}. In our case, we present scleral melting corresponding to the area of sclerotomy region with an unidentifiable cause.

Scleral melting and perforation may develop secondary to various ocular surgeries but it is reported mostly after pterygium surgery with bare sclere technique^{11-13,16,17}. Lin et al had shown that in half of the cases with scleral melting after pterygium surgery, the causative agent was a gram negative pathogen (*Pseudomonas aeruginosa*)¹⁷. In our case we could not isolate any microorganism in culture. Maza and Foster 1991 reported 10 cases of necrotising scleritis which led to scleral melting after intraocular surgeries. Necrotising scleritis had been observed usually after one year (1 day- 4 years) of an intraocular surgery in his series. They had reevaluated their patients and in all of them they found an underlying connective tissue disorder. They then suggested as a pathogenesis that, inappropriate immune mechanisms with resultant vasculitis underlie the possible mechanism for necrotising vasculitis¹⁶. Some reports hypothesize that circulating immune complexes may become trapped in episcleral vessels and perforating scleral vessels at the sites subjected trauma. In our case we could not find any specific connective tissue disorder but the patient had idiopathic



uveitis which shows that his eye is immunogenic. Although the pathogenesis of the necrotizing scleritis after surgery is not clear it is thought to be mostly immunological because of its high coincidence (62%) with systemic diseases and assessment of numerous activated T-helper cells in the pathological examinations¹⁶. In our case, pathological examination of the excised specimen revealed no immunological cells and also culture revealed no microorganism growth. Another hypothesis regarding necrotizing scleritis after surgery is, local ischemia caused by peroperative damage to episcleral circulation which will prevent healing and cause tissue damage¹³. In our case, the region of the scleral melting corresponded the sclerotomy area of vitrectomy thus surgical trauma might have contributed the development of ulceration by inducing local ischemia.

Additionally, the long term usage of corticosteroids in this case might have contributed the formation of scleral melting. As in this case, the patient used corticosteroids both preoperatively and postoperatively for a very long (4 months) time with changing regimens. Interaction of the corticosteroids with their specific receptors in the cytoplasm, results in the entrance of the receptor-molecule complex in to the nucleus, where it effects DNA transcription and provides changes in RNA synthesis. These changes effect the protein synthesis and consequently change the function of the cell. By these effects, during wound healing, steroids are known to prevent new collagen synthesis. In conclusion, in our case the reason of scleral melting most probably resulted from combination of several factors including long term administration of steroid treatment, local trauma induced by ocular surgery and systemic immune reaction in uveitic patient. It is important to recognise this devastating but rare complication after an intraocular surgery which needs immediate repair to improve ocular prognosis.

REFERENCES

1. Rao AN, Cousins S, Forster D, Meisler D, Opremcak EM. Clinical approach to uveitis. Intraocular

- inflammation and uveitis. The Foundation of the American Academy of Ophthalmology. Philadelphia: WB Saunders, 2000:99.119.
2. Nussenblatt RB, Whitcup SM, Palestine AG. Medical Therapy and Surgical Intervention. Physiology, Goals and Approaches to Medical Therapy .2nd ed. St Louis: Missouri, 1996.97.134.
 3. Akbatur HH, Şengün A, Akduman L. Üveitli hastalarda cerrahi yaklaşımlar. Behçet hastalığı Endoftalmiler ve Üveitler'de. 1st ed. Ankara: AtlasKitapçılık, 2002.464-481.
 4. Foster CS, Fong LP, Singh G. Cataract surgery and intraocular lens implantation in patients with uveitis. Ophthalmol 1989;96:281-288.
 5. Akbatur HH, Şengün A, Akduman L. Üveit maskeli sendromlar. Behçet hastalığı, Endoftalmiler ve Üveitler'de. 1st ed. Ankara: AtlasKitapçılık, 2002.393.415.
 6. Kiryu J, Kita M, Tanabe T, Yamashiro K, Miyamoto N, Ieki Y. Pars Plana vitrectomy for cystoid macular edema, secondary to sarcoid uveitis. Ophthalmol 2001;108:1150-1154.
 7. Pravin UD, Narsing AR, Ozler S, Peter EL, Ronald ES. Pars plana vitrectomy for intarocular inflammation-related cystoid macular edema unresponsive to corticosteroids. Ophthalmol 1992;99:1535-1541.
 8. Harbour JW, Smiddy WE, Rubsamen PE, Murray TG, Davis V JL. Pars plana vitrectomy for chronic pseudophakic cystoid macular edema. Am J Ophthalmol 1995;120:302-307.
 9. Mieler WF, Aaberg TM. Vitreous surgery in the management of peripheral uveitis. Dev Ophthalmol 1992;23:239-250.
 10. Eckardt C, Bacskulin A. Vitrectomy in intermediate uveitis. Dev Ophtahlmol 1992;23:232-238.
 11. Lyne AJ, Lloyd-Jones D. Necrotizing scleritis after ocular surgery. Trans Ophthalmol Soc UK 1979;99:146-149.
 12. Reynolds MG, Alfonso E. Infectious scleritis and keratoscleritis: management and outcome. Am J Ophthalmol 1991;112:543-547.
 13. O'Donoghue E, Lightman S, Watson S. Surgically induced necrotising sclerokeratitis; precipitating factors and respose to treatment. Br J Ophthalmol 1992;76:17-21.
 14. Bahçecioğlu H. Vitrektomide postoperatif geç takip ve komplikasyonlar. Ret-Vit 1994; 2:25-28.
 15. Karagül S. Vitrektomi ameliyatları sonrası sorun ve komplikasyonlarımız. TOD XXIV. Ulusal Kongre Bültenin'de. Ed. Günalp İ, Hasanreisioğlu B, Duman S. Cilt 1. Ankara; Yıldırım Ofset Basımevi 1990.107.
 16. Maza SM, Foster CS. Necrotizing scleritis after ocular surgery. A clinicopathologic study. Ophthalmol 1991;98:1720-1726.
 17. Lin CP, Shih MH, Tsai MC. Clinical experiences of infectious scleral ulceration: A complication of pterygium operation. Br J Ophthalmol 1997;81:980-983.