

Anatomic Variations and Lesions in Mandibular First Molar Region Detected with Cone Beam Computerized Tomography

Faruk Öztekin^{1*}, Tuba Talo Yildirim², Osman Atas³, Melek Didem Tözüm⁴

1. Department of Endodontic, Faculty of Dentistry, Firat University, Elazig, Turkey.
2. Department of Periodontology, Faculty of Dentistry, Firat University, Elazig, Turkey.
3. Department of Pediatric Dentistry, Faculty of Dentistry, Firat University, Elazig, Turkey.
4. Pre-Doctoral Clinics, College of Dentistry, University of Illinois at Chicago, Chicago, IL, U.S.A.

*Corresponding author: Öztekin F, Ass. Prof. Department of Endodontics faculty of Dentistry, Firat University, Elazig- Turkey.
E-mail: foztekin@firat.edu.tr

Abstract

Background: The aim of the present study was to evaluate the submandibular fossa (SF) depth, periodontal bone loss (PBL), furcation defects (FD) and periapical (PA) status in mandibular first molar region with cone beam computerized tomography.

Materials and Methods: The retrospective study consisted of CBCT images of 402 mandibular posterior regions from 201 patients. The CBCT scans were assessed to detect the prevalence of SF depth, PBL, FD and periapical status. X2-test was used to detect whether there were significant differences in the prevalence of PBL, PA status, FD, and SF by gender and by age, by occlusion. Pearson's coefficient was applied to evaluate the correlation between variables.

Result: 90 females, 111 males, mean age of 30.52±13.08) were examined. There were significant associations between age and SF depth, PBL, FD, PA status at both right and left sides (p<0.05). There were statistically significant difference among the FD and PBL with regard to occlusal contact at right side (p<0.05). Also, age was correlated with SF depth, PBL, FD, PA and gender was correlated with PBL, FD.

Conclusion: CBCT should be preferred after a detailed and careful clinical evaluation, especially in complex cases where invasive treatment approaches such as regenerative and dental implant surgery are considered as conventional 2D radiography is not sufficient.

Research Article (HRU Int J Dent Oral Res 2022; 2(2): 87-94)

Keywords: Anatomy, radiology, CBCT, dental implants, furcation defect.

Introduction

The role of radiology in dental treatment planning is increasing with the development of imaging methods (1). Normal anatomical structures, pathologies, traumas, impacted teeth, paranasal sinus neighborhoods, cysts and tumors can be easily evaluated with cone beam computerized tomography (CBCT) technique (2).

In dentistry, CBCT is mostly used for the evaluation of teeth and surrounding anatomic structures during the treatment planning. One of the most significantly used treatment is dental implants where the size of the bone and the localization of the anatomical structures must be known (3). Submandibular fossa (SF) is a significant anatomic structure in the posterior mandibular region that should be evaluated before implant treatment (4).

CBCT also provides convenience in the

identification of periodontal diseases characterized by periodontal bone defects especially with three dimensional (3D) images (5, 6). Defects formed as a result of the pathologic resorption of the bone between the roots of multi-rooted teeth are defined as furcation defects (FD). FD is a complex periodontal disorder due to its anatomic and morphologic features, and difficult to diagnose and treatment (7).

CBCT plays an important role in the diagnosis and treatment of periapical lesions. Detection of the apical lesions of the teeth and the choice of the treatment method to be applied afterwards, provides a great benefit to the practitioner compared to conventional two-dimensional radiographs. Early diagnosis of periapical bone lesions affects treatment success and prognosis positively (8-10).

Therefore the purpose of this study was to evaluate the diagnostic value of CBCT in examining the 3D topography of SF depth, periodontal bone loss (PBL), FD

defects and periapical status in mandibular first molar region.

Material and Methods

The Institutional Review Board approved this retrospective clinical study (approval number: 05.10.2017-13/31). The CBCT images of 423 patients were evaluated, and 222 patients were excluded for any of the following reasons: unilateral or bilateral 1st molar teeth, loss of having had previous surgical procedures, bone grafting in the posterior mandible, jaw fracture, presence of metallic artifacts and non-diagnostic, low-resolution quality of CBCT images. Therefore, this study consisted images of 402 mandibular posterior regions from 201 patients (90 female and 111 male patients; mean age 30.52 ± 13.08 years; range 10-67 years).

All images were obtained at the Department of Dento-Maxillofacial Radiology between 2017 and 2019. Patients who were seeking dental and/or oral treatments (i.e., dental implants, endodontic procedures, oral/periodontal surgery, orthodontics, and treatment of oral diseases) were included.

1. CBCT Image Analysis

CBCT images of all patients were obtained with the Planmeca Promax 3D Mid (Planmeca Oy, Helsinki, Finland, 2012) CBCT device. The operating parameters of the device are 90 kV, 10 mA and 36 sec. The voxel size of the obtained images was 0.4 mm and cross-sectional thickness was 0.40 mm. The images of mandible obtained by successive irradiation of FOV size 16x9 cm were combined with Romexis 2.92 software program (Planmeca Oy, Helsinki, Finland). All images were reviewed and all the measurements were performed by one calibrated examiner (F.O.).

2. Assessment of Submandibular Fossa Depth

Cross-sectional view were used to determined the depth of the SF. A line was placed on the most prominent superior and inferior points of the lingual concavity, and a second line was drawn from the deepest point of the concavity perpendicular to the first line Figure 1.

SF groups were classified as:(11)

Group I: a flat impression < 2 mm deep,

Group II: a 2 to 3 mm concavity,

Group III: a concavity > 3 mm.

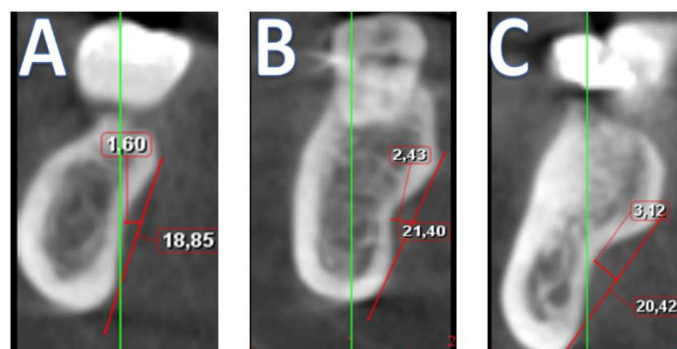


Figure 1: Crosssectional CBCT section identifying the submandibular fossa depth. (A) a flat impression < 2 mm deep, (B) a 2 to 3 mm concavity, (C) a concavity > 3 mm.

3. Assessment of Periodontal Bone Loss

Panoramic view was used to evaluate PBL in CBCT images. The percentage of normal periodontal bone height was calculated at mesial and distal sides of each tooth. To assess the level of PBL, the distance between the point 2 mm under the cemento enamel junction and the upper point of the alveolar bone was measured. The extent of PBL was classified as described before: (12)

Group 1: normal to mild, < 25% bone loss

Group 2: moderate, 25% to 50% bone loss

Group 3: severe, > 50% bone loss

4. Assessment of Furcation Defect

Sagittal and axial views were used to assess furcation defect (13) (Figure 2).

Group I: There is no bone loss in furcation region

Group II: There is vertical bone loss in furcation region but not horizontal bone loss.

Group III: There is a horizontal bone loss in furcation region but the destruction of furcation region does not include all.

Group IV: Complete loss of interradicular bone at furcation site bone destruction is such that the transition from one to the other.

5. Assessment of PA status

The PA index scoring system was used to assess PA status as described previously: (14)

Group I: Normal periapical structure

Group II: Minor changes in bone structure

Group III: Changes in bone structure with mineral loss

Group IV: Periodontitis with prominent radiolucent area

Group V: Severe periodontitis characterized by exacerbation

The study patients were also classified by gender by occlusion (Group I: No teeth opposite arch, Group II: Teeth at opposite arch) and by age in years as under Group I: 25 years, Group II: 25 to 50 years, and Group III: over 50 years

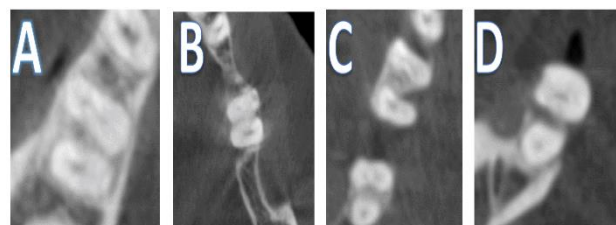


Figure 2: Axial CBCT section identifying the furcation defect . (A) no bone loss in furcation region. (B) There is vertical bone loss in furcation region but not horizontal bone loss. (C) There is a horizontal bone loss in furcation region but the destruction of furcation region does not include all. (D) Complete loss of interradicular bone at furcation site bone destruction is such that the transition from one to the other

Statistical analysis

X2-test was used to detect whether there were significant differences in the prevalence of PBL, PAstatus, FD, and SF by gender and by age, by occlusion pattern in both the left and right sites P values less than 0.05 were considered statistically significant. Pearson's coefficient was applied to evaluate the correlation between variables. All computations

were performed by using SPSS version 23.0 (SPSS Inc., Chicago, IL, U.S.A).

Results

The CBCT images of 402 mandibular posterior regions from 201 patients (90 females, 111 males, mean age of 30.52±13.08) were examined. At right sides, 91.1% of mandibular first molar teeth were in occlusal contact and in left side 93.6% were in occlusal contact.

SF depth ranged from 0.3mm to 7.2 mm. The mean SF was 2.30±0.97 mm. SF depth of less than 2 mm, 2 to 3 mm, and more than 3 mm were observed 39.7%, 38.8%, and 21.3% of the images, respectively. The average SF depth of males, and females were 2.34±1.04 mm, and 2.26±0.88 mm, respectively. There were no significant associations between gender and SF at both right and left sides (p=0.842, p=0.310). When SF depth evaluated according to age groups, there were significant associations between age and SF depth at both right and left sides (p=0.012, p=0.001). Occlusion had no significant effect on SF depth (p=0.491, p=0.122) (Table 1).

Group I PBL was observed in 48.8% of males and 43.3% of females, and group II PDL was observed in 6.5% of males 1.5% of females. PBL was significantly associated with gender at right side (p=0.004) and occlusal contact at right side (p=0.028). Table 2 shows the association between gender, age and occlusal contact and the degree of PBL.

Table 1. Differences related to age, gender, side and occlusion of depth of SF

	Right			p	Left			p
	Submandibular fossa depth				Submandibular fossa depth			
	I	II	III		I	II	III	
Gender								
Male	49(24.3%)	39(19.4%)	23(11.4%)	0.841	42(20.9%)	42(20.9%)	27(13.4%)	0.310
Female	36(17.9%)	33(16.4%)	21(10.4%)		33(16.4%)	42(20.9%)	15(7.5%)	
Age								
Group I	54(26.8%)	32(15.9%)	20(9.9%)	0.012*	56(27.9%)	39(19.4%)	15(7.5%)	0.001*
Group II	22(10.9%)	32(15.9%)	15(7.4%)		13(6.5%)	37(18.4%)	22(10.9%)	
Group III	7(3.4%)	4(1.9%)	15(7.4%)		6(3%)	8(4%)	5(2.5%)	
Occlusion								
I	76(37.8%)	65(32.3%)	42(20.8%)	0.491	70(34.8%)	76(37.8%)	42(20.9%)	0.122
II	8(3.9%)	6(2.9%)	4(1.9%)		5(2.5%)	8(4%)	0(0%)	

*p<0.05 statistically significant

Table 2. Association between periodontal bone loss and gender, age, occlusion

	Right			Left		
	Periodontal Bone Loss <25%	25-50%	p	Periodontal Bone Loss <25%	25-50%	p
Gender						
Male	96 (47.8%)	15(7.5%)	0.004*	100 (49.8%)	11(5.5%)	0.115
Female	88(43.8%)	2(1%)		86(42.8%)	4(2%)	
Age						
Group I	106 (52.7%)	4(2%)	0.013*	106 (52.7%)	4(2%)	0.019*
Group II	63 (31.3%)	9(4.5%)		65 (32.3%)	7(3.5%)	
Group III	15 (7.5%)	4(2%)		15 (7.5%)	4(2%)	
Occlusion						
I	170 (84.6%)	13(6.5%)	0.028*	173 (86.1%)	15(7.5%)	0.290
II	14(7%)	4(2%)		13(6.5%)	0 (0%)	

*p<0.05 statistically significant

FD was observed in 77.3% of the arches, in which 40.55% were group I, 30.55% were group II, and 6.25% were group III. FD was significantly associated with age at both right (p=0.001) and left sides (p=0.01). There was no significant association between gender and FD at both right and left side (p=0.093, p=0.063). There was a statistically significant difference among the FD with regard to occlusal contact at right side (p=0.01) (Table 3).

PA lesions were found in 41.8% of the alveolar crests in which 23.7% of males and, 18.2% of female patients. No significant association between PA lesions and gender (p=0.817) and lateralizations (p=0.650) were detected. Age is an important factor affecting PA status at both right and left sides (p=0.003, p=0.006) (Table 4).

Table 5 show that age was correlated with SF depth, PBL, FD, PA and gender was correlated with PBL, FD.

Table 3. Differences related to age, gender, side and occlusion of furcation classification

	Right				p	Left				p
	Furcation classification					Furcation classification				
	0	I	II	III		0	I	II	III	
Gender										
Male	26(12.9%)	39(19.4%)	35(17.4%)	11(5.5%)	0.093	27(13.4%)	36(17.9%)	40(19.9%)	8(4%)	0.063
Female	21(10.4%)	42(20.9%)	25(12.4%)	2(1%)		17(8.5%)	46(22.9%)	23(11.4%)	4(2%)	
Age										
Group I	35(17.4%)	47(23.4%)	26(12.9%)	2(1%)	0.001*	33(16.4%)	45(22.4%)	29(14.4%)	3(1.5%)	0.01*
Group II	10(5%)	28(13.9%)	27(13.4%)	7(3.5%)		9(4.5%)	32(15.9%)	25(12.4%)	6(3%)	
Group III	2(1%)	6(3%)	7(3.5%)	4(2%)		2(1%)	5(2.5%)	9(4.5%)	3(1.5%)	
Occlusion										
I	43(21.4%)	80(39.8%)	52(25.9%)	8(4%)	0.001*	38(18.9%)	81(40.3%)	58(28.9%)	11(5.5%)	0.051
II	4(2%)	1(0.5%)	8(4%)	5(2.5%)		6(3%)	1(0.5%)	5(2.5%)	1(0.5%)	

*p<0.05 statistically significant

Table 4. Association between periapical status and gender, age, occlusion

	Right					p	Left					p
	Periapical status						Periapical status					
	I	II	III	IV	V		I	II	III	IV	V	
Gender												
Male	61(30.3%)	28(13.9%)	11(5.5%)	8(4%)	3(1.5%)	0.810	66(32.8%)	20(10%)	16(8%)	6(3%)	3(1.5%)	0.850
Female	56(27.9)	20(10.0)	7(3.5)	4(2)	3(1.5%)		51(25.4%)	22(10.9%)	11(5.5%)	4(2%)	2(1%)	
Age												
Group I	77(38.3%)	24(11.9%)	5(2.5%)	3(1.5%)	1(0.5%)	0.003*	75(37.3%)	23(11.4%)	8(4%)	4(2%)	0(0%)	0.006*
Group II	33(16.4%)	18(9%)	10(5%)	6(3%)	5(2.5%)		35(17.4%)	16(8%)	13(6.5%)	4(2%)	4(2%)	
Group III	7(3.5%)	6(3%)	3(1.5%)	3(1.5%)	0(0%)		7(3.5%)	3(1.5%)	6(3%)	2(1%)	1(0.5%)	
Occlusion												
I	111(55.2%)	43(21.4%)	12(6%)	12(6%)	5(2.5%)	0.002*	109(54.2%)	40(19.9%)	26(12.9%)	8(4%)	5(2.5%)	0.414
II	6(3%)	5(2.5%)	6(3%)	0(0%)	1(0.5%)		8(4%)	2(1%)	1(0.5%)	2(1%)	0(0%)	

*p<0.05 statistically significant

Table 5. Correlations regarding to age, gender and occlusion with SF depth, periodontal bone loss, furcation classification and periapical status

	Submandibular fossa depth		Periodontal bone loss		Furcation classification		Periapical status	
	r	p	r	p	r	p	r	p
Gender	0.042	0.405	0.158	0.001*	0.106	0.033*	0.048	0.336
Age	0.269	0.001*	0.187	0.001*	0.312	0.001*	0.304	0.001*
Occlusion	0.077	0.124	0.053	0.291	0.094	0.059	0.077	0.12

*p<0.05 statistically significant

Discussion

New diagnostic imaging methods have been developed based on technological advances in computer systems. CBCT devices, available at lower prices than CT machines, provide dentists with valuable diagnostic information (15). Cross-sectional images obtained with CBCTs allow the dentist to evaluate the area more accurately than conventional 2 dimensional imaging methods (16).

The most important part of the examination of the tomography obtained from the surgical site in the evaluation before the dental implant surgery is to evaluate the relationship between the anatomical structures and variations of the region where the dental implant will be applied (14). The depth of SF is one of the most important parameters that should be evaluated in the mandibular posterior region before dental implant surgery to eliminate perforation of the lingual bone cortex and to eradicate potentially dangerous complication (17, 18).

Evaluation of SF by preoperative palpation or flap elevation with a direct view is insufficient for a safe surgery (19). In the literature, many studies

have been reported on lingual cortex perforation after dental implant placement (20, 21). Souze et al. reported that the depth of SF should be evaluated carefully, especially in the mandibular molar region not the premolar areas (19).

According to the results of the present study, the depth of SF showed no significant difference according to gender and occlusion status of both right and left sides. However, a statistically significant relationship was determined according to age groups. Group I SF was more common in group I, and group II SF was more common in group II. We think that submandibular fossa depth increases with increasing bone resorption with age. Contrary to our results, Parnia et al investigated no significant differences among age categories (11). The differences between our study and Parina may be based on different classifications used or the presence of age.

One of the most common groups of periodontal diseases is periodontitis characterized by alveolar bone loss (22). The success of periodontal treatment depends on many factors. One of the most important factors is the accurate

visualization of periodontal bone destruction and morphology of bone defects for treatment planning (23). It is reported that only 21% of the angular defects in periodontal diseases can be detected by panoramic radiographs, 32% by periapical radiographs, and 43% of angular bone defects can be detected with both methods (22). The results of the present study showed that PBL was more common in men than in women. Bone destruction was increased with age. Helmi et al reported that males had a higher risk of developing periodontal diseases with significantly higher alveolar bone loss compared to females (24) and this result coincided with similar results reported in literature indicating that males having higher risk of developing the disease (25, 26). A study conducted by Eke et al. to evaluated the prevalence of periodontal diseases in adults where older age groups had a higher risk and proportion of periodontitis compared to younger age groups (25)

CBCT is a valuable imaging technique especially for the diagnosis of intra-bony defects, furcation involvement and buccal / lingual bone destructions (27). Early diagnosis of bone defects is crucial for successful results in periodontal treatment. In the literature, studies comparing the 3D and 2D imaging methods for the detection of alveolar bone defects have shown that CBCT has a sensitivity of 80-100% for the detection of bone defects, and 63-67% for intraoral radiographs (28). In order to detect bone resorption on conventional radiographs, excessive mineral loss (30-50%) is required in the bone (29). Therefore, bone lesions may be overlooked in the initial stage by conventional radiographs. Early diagnosis of FDs is very important in the success rate of periodontal treatment (13).

Current study also found that group 0 was 22.6%, group I was 40.55%, group II was 30.55% group III was 6.25%. The result of this study showed that mean ages were statistically higher in group III group, and statistically lower in the group 0 when compared with other groups. Previous research demonstrated that the prevalence and severity of FD increased with age (30, 31). Recent studies demonstrated that PBL increased with age (12, 14). No significant relationship was found between gender and FD. Similar to our study, Ozcan et al. reported that gender was not an important parameter affecting the furcation defects (32).

Evaluation of periapical region and detection of changes in this area is one of the most important

steps in the planning of diagnosis and treatment of dental diseases. Because of the diagnostic confusion in the diagnosis of these periapical changes, these lesions can often be difficult to diagnose, difficult to treat, and costly. Traditional techniques have been preferred for many years in dental applications despite some diagnostic deficiencies. In traditional and digital techniques, which are 2D, approximately 30-50% of the bone destruction is required to detect lesions (33). Distortion, magnification, superposition, narrow areas of imaging and application errors are limited to the reasons such as, sometimes can give false information. CBCT gives 3D (axial, coronal and sagittal) images. These cross-sectional images are used as a reliable technique in the evaluation of root canal lesions and root canal treatments (34). Patel et al. reported that the success of both imaging systems in detecting periapical lesions was reported as 100% and 24.8%, respectively when CBCT sections and intraoral radiography images were compared (35).

In the present study shown, 58.2% of teeth had no periapical lesions, while 22.4% had group II, 11.25% had group III, 5.5% had group IV, and 2.75% had group V. The frequency of periapical lesions increases with age. Previous studies reported that periapical and periodontal lesions were increased with age (12, 14). We think that this result may be associated with longer exposure of teeth in the oral cavity having physiological and pathologic factors such as aging. Similar to our results Keser et al. reported that no statistically significant difference was found between the number of teeth with lesion in male and female subjects (36). Ampara et al observed that no significant associations between periapical lesions and gender (37).

Conclusion

CBCT should be preferred after a detailed and careful clinical evaluation, especially in complex cases where invasive treatment approaches such as regenerative and dental implant surgery are considered as conventional 2D radiography is not sufficient. According to the findings of the present study, while the effect of age on the anatomical structures and parameters examined was high, gender had an effect only on periodontal bone loss.

Occlusal status was found to be important in PDL, FD, PA evaluations in the right side of the patients.

Funding

There was no funding.

Ethical approval

The ethical approval was released by Institutional Review Board Approval of Firat University (05.10.2017-13/31).

Informed consent

For this type of study, formal consent is not required.

Declaration of competing interest

The authors declare that has no conflict of interest.

References

1. White SC, Pharoah MJ. The evolution and application of dental maxillofacial imaging modalities. *Dent Clin North Am* 2008; 52(4):689-705.
2. Erickson M, Caruso J, Leggett L, Newtom QR-DVT 9000 imaging used to confirm a clinical diagnosis of iatrogenic mandibular nerve paresthesia. *J Calif Dent Assoc* 2003; 31(11):843-5.
3. Scarfe WC, Farman AG, Sukovic P. Clinical applications of cone-beam computed tomography in dental practice. *J Can Dent Assoc* 2006; 72(1):75-80.
4. Borahan APMO, Pekiner FN. Assessment of submandibular fossa depth using cone beam computed tomography. *Therapy* 2018; 14(2):51-6.
5. Sato S, Arai Y, Shinoda K, Ito K. Clinical application of a new cone-beam computerized tomography system to assess multiple two-dimensional images for the preoperative treatment planning of maxillary implants. *Quintessence Int* 2004; 35(7):525-8.
6. Ito K, Gomi Y, Sato S, Arai Y, Shinoda K. Clinical application of a new compact CT system to assess 3-D images for the preoperative treatment planning of implants in the posterior mandible: A case report. *Clin Oral Implants Res* 2001; 12(5):539-42.
7. Cattabriga M, Pedrazzoli V, Wilson Jr TG. The conservative approach in the treatment of furcation lesions. *Periodontol* 2000 2000; 22(1):133-53.
8. Nakata K, Naitoh M, Izumi M, Inamoto K, Arijji E, Nakamura H. Effectiveness of dental computed tomography in diagnostic imaging of periradicular lesion of each root of a multiradical tooth: a case report. *J Endod* 2006; 32(6):583-7.
9. Patel S, Dawood A, Ford TP, Whaites E. The potential applications of cone beam computed tomography in the management of endodontic problems. *Int Endod J* 2007; 40(10):818-30.
10. Low KM, Dula K, Bürgin W, von Arx T. Comparison of periapical radiography and limited cone-beam tomography in posterior maxillary teeth referred for apical surgery. *J Endod* 2008; 34(5):557-62.
11. Parnia F, Fard EM, Mahboub F, Hafezqorani A, Gavvani FE. Tomographic volume evaluation of submandibular fossa in patients requiring dental implants. *Oral Surg Oral Med Oral Pathol Oral Radiol Endod* 2010; 109(1):e32-e6.
12. Yildirim TT, Güncü GN, Colak M, Tözüm TF. The Relationship between Maxillary Sinus Lateral Wall Thickness, Alveolar Bone Loss, and Demographic Variables: A Cross-Sectional Cone-Beam Computerized Tomography Study. *Med Princ Pract* 2019; 28(2):109-14.
13. Zhang W, Foss K, Wang B-Y. A retrospective study on molar furcation assessment via clinical detection, intraoral radiography and cone beam computed tomography. *BMC oral health* 2018; 18(1):75.
14. Yildirim TT, Güncü GN, Gökşülük D, Tözüm MD, Colak M, Tözüm TF. The effect of demographic and disease variables on Schneiderian membrane thickness and appearance. *Oral Surg Oral Med Oral Pathol Oral Radiol Endod* 2017; 124(6):568-76.
15. Noujeim M, Pihoda T, Langlais R, Nummikoski P. Evaluation of high-resolution cone beam computed tomography in the detection of simulated interradicular bone lesions. *Dentomaxillofac Radiol* 2009; 38(3):156-62.
16. Yildirim YD, Güncü GN, Galindo-Moreno P, Velasco-Torres M, Juodzbalys G, Kubilius M, et al. Evaluation of mandibular lingual foramina related to dental implant treatment with computerized tomography: a multicenter clinical study. *Implant Dent* 2014; 23(1):57-63.
17. Chan HL, Brooks SL, Fu JH, Yeh CY, Rudek I, Wang HL. Cross-sectional analysis of the mandibular lingual concavity using cone beam computed tomography. *Clin Oral Implants Res* 2011; 22(2):201-6.
18. Froum S, Casanova L, Byrne S, Cho SC. Risk assessment before extraction for immediate implant placement in the posterior mandible: a computerized tomographic scan study. *J Periodontol* 2011; 82(3):395-402.
19. de Souza LA, Assis NMSP, Ribeiro RA, Carvalho ACP, Devito KL. Assessment of mandibular posterior regional landmarks using cone-beam computed tomography in dental implant surgery. *Ann Ana* 2016; 205:53-9.
20. Chan HL, Benavides E, Yeh CY, Fu JH, Rudek IE, Wang HL. Risk assessment of lingual plate perforation in posterior mandibular region: a virtual implant placement study using cone-beam computed tomography. *J Periodontol* 2011; 82(1):129-35.
21. Pelayo JL, Diago MP, Bowen EM, Diago MP. Intraoperative complications during oral implantology. *Med Oral Patol Oral Cir Bucal* 2008; 13(4):239-43.
22. Tugnait A, Clerehugh V, Hirschmann P. The usefulness of radiographs in diagnosis and management of periodontal diseases: a review. *J Dent* 2000; 28(4):219-26.
23. Braun X, Ritter L, Jervøe-Storm P-M, Frentzen M. Diagnostic accuracy of CBCT for periodontal lesions. *Clin Oral Investig* 2014; 18(4):1229-36.
24. Helmi MF, Huang H, Goodson JM, Hasturk H, Tavares M, Natto ZS. Prevalence of periodontitis and alveolar bone loss in a patient population at Harvard School of Dental Medicine. *BMC oral health* 2019; 19(1):254.
25. Eke PI, Dye B, Wei L, Thornton-Evans G, Genco R. Prevalence of periodontitis in adults in the United States: 2009 and 2010. *J Dent Res* 2012; 91(10):914-20.
26. Natto ZS, Hameedaldain A. Methodological quality assessment of meta-analyses and systematic reviews of the relationship between periodontal and systemic diseases. *J Evid Based Dent Pract* 2019; 19(2):131-9.
27. Mohan R, Singh A, Gundappa M. Three-dimensional imaging in periodontal diagnosis—Utilization of cone beam computed tomography. *J Indian Soc Periodontol* 2011; 15(1):11.
28. de Faria Vasconcelos K, Evangelista K, Rodrigues C, Estrela C, De Sousa T, Silva M. Detection of periodontal bone loss using cone beam CT and intraoral radiography. *Dentomaxillofac Radiol* 2012; 41(1):64-9.
29. Mol A. Imaging methods in periodontology. *Periodontol* 2000. 2004;34(1):34-48.
30. Hou GL, Tsai CC. Relationship between periodontal furcation involvement and molar cervical enamel projections. *J Periodontol* 1987; 58(10):715-21.
31. Tal H, Lemmer J. Furcal Defects in Dry Mandibles: Part II: Severity of Furcal Defects. *J Periodontol* 1982; 53(6):364-7.

32. Ozcan G, Sekerci A. Classification of alveolar bone destruction patterns on maxillary molars by using cone-beam computed tomography. *Niger J Clin Pract* 2017; 20(8):1010-9.
33. Bender I. Factors influencing the radiographic appearance of bony lesions. *J Endod* 1982; 8(4):161-70.
34. Borahan M, Dumlu A, Pekiner F. Diş hekimliğinde yeni bir çağın başlangıcı: Dental Volumetrik Tomografi. *İstanbul Dişhekimleri Odası Dergisi*. 2012; 143:32-5.
35. Patel S. New dimensions in endodontic imaging: Part 2. Cone beam computed tomography. *Int Endod J* 2009; 42(6):463-75
36. Keser G, Pekiner FN. Comparative Evaluation of Periapical Lesions Using Periapical Index Adapted for Panoramic Radiography and Cone Beam Computed Tomography. *Clin Exp Health Sci* 2018; 8(1):50-5.
37. Ramis-Alario A, Tarazona-Alvarez B, Cervera-Ballester J, Soto-Peñaloza D, Peñarrocha-Diago M, Peñarrocha-Oltra D, et al. Comparison of diagnostic accuracy between periapical and panoramic radiographs and cone beam computed tomography in measuring the periapical area of teeth scheduled for periapical surgery. A cross-sectional study. *J Clin Exp Dent* 2019;11(8):e732