



OLGU SUNUMU/CASE REPORT

Unusual features associated with dentinogenesis imperfecta type II: report of two cases affecting the family over three generations

Dentinogenesis imperfecta tip 2 ile ilgili sıradışı özellikler: ailesi üç kuşaktan fazla etkilenmiş iki olgu

Shruthi Rao¹, Shruthi Hegde¹, Vidya Ajila¹, Subhas Babu¹, Ananya Madiyal¹, Sajad Ahmed Buch¹

¹A B Shetty Memorial Institute of Dental Sciences, Nitte University

Cukurova Medical Journal 2017;42(1):155-160.

Abstract

Dentinogenesis imperfecta (DI) is an autosomal dominant genetic disease. It has a high degree of penetrance and a very low mutation rate. DI is characterized by opalescent dentin and discoloration of the teeth. The exposed dentin may undergo severe attrition. Early diagnosis and management of this condition is essential for the prevention of further complications and for the aesthetic purpose. We present clinical and radiographic features of two cases of DI type II affecting the family over three generations. This report also highlights rare features such as odontome, multiple impacted teeth and retained deciduous teeth along with features of DI in a 16-years old male.

Key words: Dentinogenesis imperfecta, autosomal dominant, dentin.

Öz

Dentinogenesis imperfecta (DI) otozomal dominant genetik bir hastalıktır. Yüksek derecede penetrasyon ve düşük mutasyon oranına sahiptir. DI opalesant dentin ve dişlerde renk değişikliği ile karakterizedir. Dentin şiddetli yıpranmaya maruz kalabilir. Bu durumun erken tanı ve tedavisi, diğer komplikasyonların önlenmesinde ve estetik amaç için gereklidir. Bu çalışmada üç kuşak boyunca DI tip 2 den etkilenmiş bir aileden iki vakanın klinik ve radyolojik özellikleri sunulmuştur. Bu rapor aynı zamanda 16 yaşındaki bir erkekte DI özellikleri ile birlikte odontom ve çoklu dişler gibi nadir görülen özellikleri vurgulamaktadır.

Anahtar kelimeler: Dentinogenesis imperfecta, otozomal dominant, dentin.

INTRODUCTION

Dentinogenesis Imperfecta (DI) an autosomal dominant genetic disease¹. In 1939 Robert and Schour² coined the term 'dentinogenesis imperfecta'. The incidence of DI is reported to be around 1 in 6,000 to 1 in 8,000². DI is a hereditary disorder of dentin formation³. It has a high degree of penetrance and a very low mutation rate⁴. It is associated with localized mesodermal dysplasia of dental papilla of both deciduous and permanent dentitions^{4,5}.

The colour of the teeth varies from brown to blue with opalescent sheen. The enamel may show hypoplastic or hypocalcified defects in few patients and it tends to crack away from defective dentin.

The dentin which is exposed may undergo severe and rapid attrition⁶.

Early diagnosis and management of this condition is essential for the prevention of further complications and for the aesthetics. Present article describes the clinical and radiological characteristics of DI affecting three generations of a south Indian family. This case report also highlights added features such as odontome, multiple impacted teeth, and retained deciduous teeth along with DI features.

CASE 1

A 16-years-old male reported to the Department of Oral Medicine with the complaint of discoloured teeth since childhood. Patient gave history of

Yazışma Adresi/Address for Correspondence: Dr. Shruthi Rao, A B Shetty Memorial Institute of Dental Sciences, Nitte University E-mail: shruthiupaduibuidrui@gmail.com
Geliş tarihi/Received: 26.04.2016 Kabul tarihi/Accepted: 06.06.2016

discoloured deciduous and permanent teeth. He also noticed gradual chipping of teeth. There was no history of bone abnormalities or any other major systemic diseases.

His maternal grandfather, mother and both the maternal uncles have history of discoloured teeth. One maternal uncle has a child with teeth discolouration. Patient’s father, siblings and maternal grandmother were unaffected. None of his paternal relatives were affected(Figure 1).

On intraoral examination all the teeth showed generalized yellowish to brown discoloration and attrition. Severe reduction in the vertical dimension was noted. Retained deciduous root stumps with respect to maxillary right and left canine, mandibular left canine and root stumps of mandibular left and right permanent first molar were noticed (Figure 2).

Intraoral periapical radiograph (IOPA) of maxillary right permanent canine region revealed impacted permanent canine and maxillary right central incisor (Figure 3 A). IOPA with respect to maxillary left permanent canine region revealed impacted permanent canine which was surrounded by hyperplastic follicle (Figure 3 B). An IOPA with respect to mandibular left permanent canine region revealed multiple tooth like structures surrounded by radiolucency resembling compound odontome and an impacted permanent canine below the odontome (Figure 3 C).

Panoramic radiograph revealed thin enamel, generalised loss of contact point, bulbous crowns, constriction of tooth at cementoenamel junction, altered morphology of pulpal space and short roots. Multiple radio opacities resembling tooth like structures were noticed 0.5 centimetres below the retained left mandibular deciduous canine indicative of compound odontome. Impacted left mandibular permanent canine was present beneath the compound odontome. Multiple impacted teeth with respect to right maxillary permanent central incisor, right maxillary permanent canine, left maxillary permanent canine and left mandibular permanent canine were present. Retained deciduous teeth were noted with respect to right maxillary canine, left maxillary canine and left mandibular canine. Root stumps were noticed with respect to left mandibular permanent first molar and right mandibular permanent first molar (Figure 3D).

Based on history, clinical and radiographic features patient was diagnosed with Dentinogenesis Imperfecta Type II. Patient was advised extractions of retained deciduous teeth and root stumps and surgical excision of compound odontome. Orthodontic and surgical evaluation for impacted teeth and full mouth rehabilitation was planned. He is undergoing treatment and is on regular follow up.

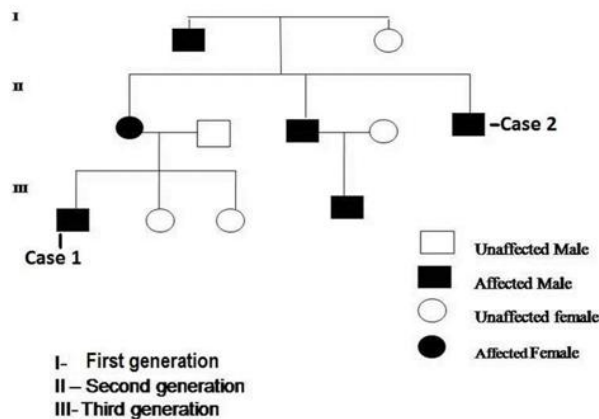


Figure 1: Pedigree showing DI affected family

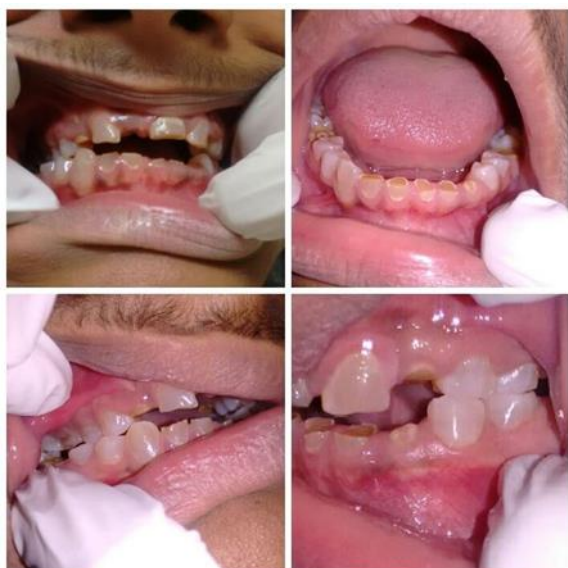

Figure 2: Clinical images of Case 1 showing discoloration and loss of vertical dimension, root stumps of mandibular left and right permanent first molar. Retained deciduous root stumps with respect to maxillary right and left canine, mandibular left canine.

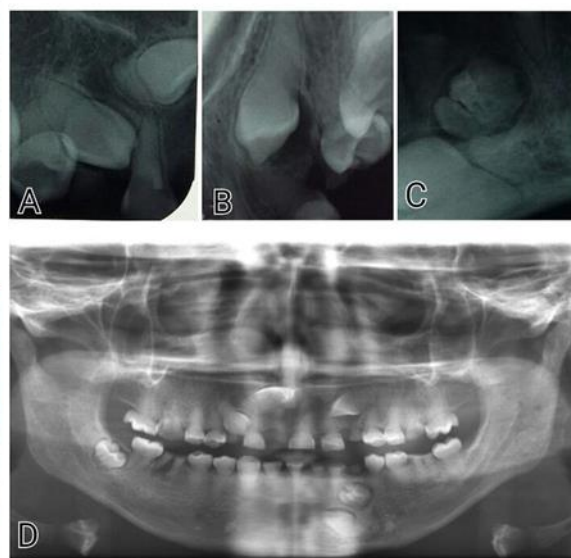


Figure 3 A: Intraoral periapical radiograph (IOPA) showing impacted permanent canine, maxillary right central incisor. **Figure 3 B:** IOPA shows impacted permanent canine surrounded by hyperplastic follicle. **Figure 3 C:** IOPA showing multiple tooth like structures surrounded by radiolucency resembling compound odontome and an impacted tooth below the odontome. **Figure 3 D:** Panoramic radiograph shows thin enamel, bulbous crowns, constriction of tooth at cervical region, altered morphology of pulp space and short roots. Multiple radio opacities resembling tooth like structures below the retained left mandibular deciduous canine indicating compound odontome. Impacted left mandibular permanent canine beneath the compound odontome observed. Multiple impacted teeth, retained deciduous teeth also can be noted.

CASE 2

Patient's maternal uncle aged 25 visited the department with complaint of chipping of teeth. He gave a history of chipping and discoloration of teeth affecting both primary and permanent dentition. Intraoral examination showed generalized yellowish brown discoloration and attrition. Severe reduction in the vertical dimension was noted (Figure 4). Panoramic radiography revealed generalised bulbous crowns with prominent cervical constriction. Altered morphology of pulp chamber and root canal was noticed. Roots were of short length. Loss of enamel cap was seen in anterior

teeth. Periapical radiolucency in maxillary right permanent first molar and mandibular right and left permanent first molar was noticed, which was suggestive of periapical infection (Figure 5 A).

IOPA of mandibular left permanent first molar shows obliteration of pulp space. Ill defined periapical radiolucency with loss of lamina dura continuity was noted indicative of periapical infection (Figure 5 B). Based on history, clinical and radiographic features patient was diagnosed with Dentinogenesis imperfecta Type II. Root canal treatment for maxillary right first molar, right central incisor and extraction of mandibular right and left permanent first molar was advised. Full mouth

rehabilitation was planned.

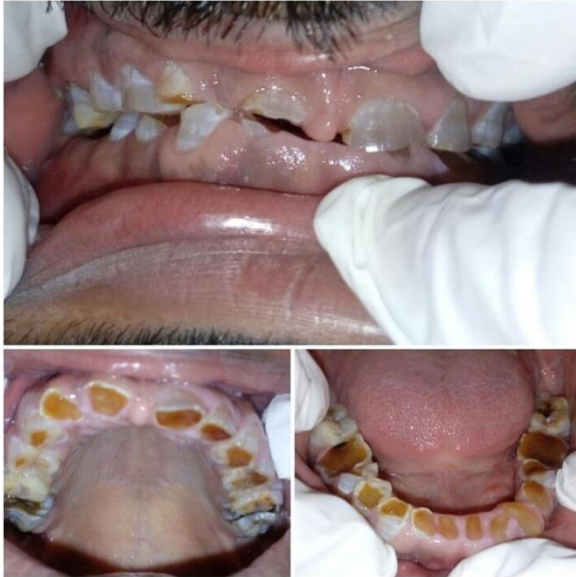

Figure 4. Clinical images of Case 2 shows generalized yellowish brown discoloration and severe attrition.

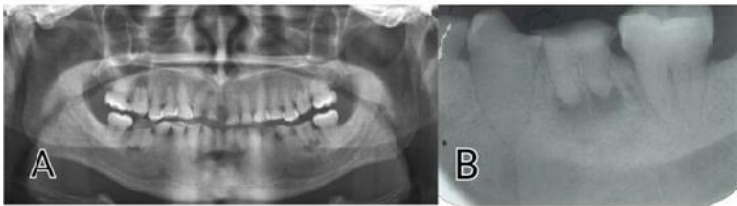

Figure 5 A: Panoramic radiograph shows generalised bulbous crowns with prominent cervical constriction, altered morphology of pulpal space, short roots, loss of enamel cap in anterior teeth, periapical radiolucency in maxillary right first molar, central incisor and mandibular right and left permanent first molar. Figure 5 B: IOPA of mandibular left permanent first molar shows obliteration of pulpal space, periapical radiolucency indicative of periapical infection.

DISCUSSION

DI was first recognized by WC Barrett¹ in 1882. The term 'hereditary opalescent dentin' was first used by Skillen, Finn and Hodge. They used this particular term to explain the brown translucent teeth with opalescent sheen which lacked pulp chambers⁴. DI is known as hereditary opalescent dentin or Capdepont dysplasia². It follows an autosomal dominant Mendelian trait. In our case three generations were affected, where in all individuals of the second generation were affected. DI is one of the most common hereditary disorders of dentin formation³. This structural abnormality

signifies basic defect in structural and regulatory protein. Dentinogenesis imperfecta is associated with chromosome number 4q21.3, which encodes a protein called dentin sialophosphoprotein^{2,7}.

Shields and co-workers classified DI into the type I, II and III defects. Studies have shown that DI and OI are distinct entities hence a revised classification was suggested, which classified DI as 1 and 2¹. Dentinogenesis imperfecta type I is associated with Osteogenesis imperfecta whereas Dentinogenesis imperfecta type II has the same clinical radiographic and histological features as DI type 1 but without Osteogenesis imperfecta. DI type 3 a rare entity is found only in Maryland among the triracial

Brandywine population is characterized by shell teeth¹.

The affected teeth show an unusual colour deviation from the natural that varies from grey to brownish or yellowish brown. In both our cases the teeth showed generalized yellow to brown colour. DI is associated with a characteristic atypical translucent or opalescent hue and broad crowns with constriction of the cervical area. The enamel being hypoplastic is easily broken leading to exposure of dentin. The yellowish to brown variant of DI is more common and is more susceptible to attrition than the opalescent grey variant². The exposed dentin undergoes severe and accelerated attrition. Our patients showed generalised attrition and severe attrition were noted with respect to all the mandibular anteriors. The enamel is normal in most of the patients; however, one third of the patients have hypoplastic or hypocalcified defects⁸. This is due to the dentinal disturbance, with enamel being normal. As a result of this the teeth are prone to extreme wear and fracture^{3,9}. Loss of enamel cap was seen in anterior teeth of case 2. Thin enamel was noticed in case 1.

Radiographically, the characteristic appearance is the bulbous crowns with constricted short roots^{4,6}. Initially the pulp chambers are usually abnormally spacious and resemble "shell teeth," but then they will progressively obliterate giving the teeth solid appearance⁴. The teeth lack pulp chambers and root canals. Present cases showed bulbous crowns, short roots and obliterated pulp spaces.

Differential diagnosis of DI Type II includes Amelogenesis imperfecta, tooth discolouration due to tetracycline therapy and Dentin Dysplasia type II. Amelogenesis imperfecta is usually associated with complete loss of enamel of both primary and permanent dentition while dentin remains unaffected¹⁰. The deciduous dentition in Dentin dysplasia type II demonstrates a blue to amber to brown translucence resembling DI type II however the permanent teeth usually appears to be normal. Radiographic abnormalities such as thistle-tube deformity of the pulp chamber and frequent pulp stones are associated with dentin dysplasia type II⁹.

Tooth discoloration due to tetracycline therapy is associated with positive history and affects both the dentition and fluoresces under ultraviolet light¹¹. These features help us in differentiating DI type II from the above mentioned conditions.

Histologically, the dentin-enamel junction is not scalloped with mantle dentin being normal, whereas the dentinal tubules are reduced in number. Most of the cases are associated with reduced mineralization and a reduced number of odontoblasts are consistent findings⁶.

The main aim of treating dentinogenesis imperfecta is to minimize the attrition and to restore proper teeth dimensions⁸. In certain patients only primary dentition was affected by dentinogenesis imperfecta and permanent dentition was normal. But those with dentinogenesis imperfecta in the permanent dentition always were found to have dentinogenesis imperfecta in the primary dentition⁶. In our cases both dentition was affected. Early diagnosis and appropriate treatment can prevent any psychological or functional morbidity in the patients with dentinogenesis imperfecta³. The prognosis of dentinogenesis imperfecta depends upon the age at which the diagnosis is made and the quality of the treatment provided. If diagnosis is done at an early age and if appropriate treatment is provided, good aesthetics and a better function can be restored thereby decreasing the problems faced by the patient⁹.

Present report describes the clinical and radiological characteristics of DI affecting a south Indian family over three generations. This case report highlights the distinctive features such as odontome, multiple impacted teeth and retained deciduous teeth along with DI features. As the association of these features with DI were not reported till date our report adds valuable information to the existing literature.

REFERENCES

1. Surendra P, Shah R, N.M. R, Reddy VVS. Dentinogenesis imperfecta: a family which was affected for over three generations. *J Clin Diagn Res.* 2013;7:1808-11.
2. Kamboj M, Chandra A. Dentinogenesis imperfecta type II: an affected family saga. *J Oral Sci.* 2007;49:241-4.
3. Bhandari S, Pannu K. Dentinogenesis imperfecta: A review and case report of a family over four generations. *Indian J Dent Res.* 2008;19:357-61.
4. Sugnani S, Subramaniam P, Mathew S. Dentinogenesis imperfecta: a case report. *J Indian Soc Pedod Prev Dent.* 2008;26:85.
5. Bai H, Agula H, Wu Q, Zhou W, Sun Y, Qi Y et al. A novel DSPP mutation causes dentinogenesis

- imperfecta type II in a large Mongolian family. *BMC Med Genet.* 2010;11:23.
6. Sapir S, Shapira J. Dentinogenesis imperfecta: an early treatment strategy. *Pediatr Dent* 2001;23:232-37.
 7. Malmgren B, Lindskog S, Elgadi A, Norgren S. Clinical, histopathologic, and genetic investigation in two large families with dentinogenesis imperfecta type II. *Hum Genet.* 2004;114:491-8.
 8. Neeti B. Dentinogenesis Imperfecta-“a hereditary developmental disturbance of dentin”. *Internet J Pediatr Neonatol.* 2011;13:1-5.
 9. Barron M, McDonnell S, MacKie I, Dixon M. Hereditary dentine disorders: dentinogenesis imperfecta and dentine dysplasia. *Orphanet J Rare Dis.* 2008;3:31.
 10. Crawford P, Aldred M, Bloch-Zupan A. Amelogenesis imperfecta. *Orphanet J Rare Dis.* 2007;2:17.
 11. Watts Addy M. Tooth discolouration and staining: Tooth discolouration and staining: a review of the literature. *Br Dent J.* 2001;190:309-16.