



OLGU SUNUMU/CASE REPORT

Accessory piriformis muscle

Aksesuar musculus piriformis

Sedat Develi¹, Ahmet Yıldırım², Bülent Yalçın¹, Fatih Yazar¹

¹Gulhane Military Medical Academy, Department of Anatomy, ²Gulhane Military Medical Academy, School of Medicine, Ankara, Turkey

Cukurova Medical Journal 2017;42(1):182-183.

Abstract

Piriformis muscle originates from facies pelvica of sacrum and inserts on the trochanter major. It is one of the lateral rotator muscles of the hip and a landmark point in the gluteal region since ischiadicus nerve descends to the thigh by passing close to the muscle. This contiguity may be associated with the irritation of the nerve which is known as piriformis syndrome. A rare anatomic variation of the muscle which observed on 74 years old male cadaver is discussed in this case report.

Key words: Piriformis muscle, extra-spinal sciatica, piriformis muscle syndrome

Öz

Piriformis kası os sacrum'un facies pelvica'sından başlar ve trochanter major'a insersiyoyu yapar. Kalçanın dış rotator kaslarından birisidir ve nervus ischiadicus kasın yakın komşuluğundan geçip uyluğa doğru seyrettiği için gluteal bölgede bir işaret noktasıdır. Bu komşuluk, piriformis sendromu olarak da bilinen sinirin irritasyonu ile ilişkili olabilir. Bu olguda, kasın 74 yaşındaki bir erkek kadavrada gözlenen nadir bir anatomik varyasyonu tartışılmıştır.

Anahtar kelimeler: Piriformis kası, ekstra-spinal siyatik, piriformis kası sendromu

INTRODUCTION

Piriformis muscle is one of the lateral rotators of the hip. It originates from facies pelvica, between foramina sacralia anteriora, by digitations. Then muscle courses outside from pelvis minor to regio glutealis by passing through for. ischiadica major and inserts on the trochanter major¹. Body of the muscle almost fulfills the foramen. Passage above the muscle is called for. suprapiriforme and superior gluteal nerve and vessels pass through it. Passage below the muscle is called for. infrapiriforme and ischiadic nerve, inferior gluteal nerve and vessels, pudendal nerve and vessels pass through it¹. Compression or inflammation of the proximal part of the ischiadic nerve within for. infrapiriforme is called piriformis syndrome which is one of the extra-spinal or non-discogenic reasons of sciatica². In this study we aimed to describe an anatomic variation of piriformis muscle which may lead to piriformis syndrome.

CASE

During routine dissection of a 74-years-old male cadaver for gross anatomy education, an accessory piriformis muscle has been found. Proper muscle was coursing outside from pelvis minor via for. ischiadica major and inserting on the trochanter major. The widest part of the muscle was 4 cm. N. ischiadicus was travelling down from for. infrapiriforme as a single trunk. Bifurcation of the nerve was observed above the popliteal fossa. Interestingly, under the n. ischiadicus a muscle was noticed (Figure 1). Such as the proper piriformis muscle, this variant muscle coming outside from for. ischiadica major and was inserting just below the insertion point of the proper piriformis muscle with a separate, thick tendon. Width of the muscle was 2.5 cm under the nerve. Distance between insertion points was 2 cm. Both muscles were covered by fascia profunda separately. Other gluteal muscles and neurovascular structures were normal.

Yazışma Adresi/Address for Correspondence: Dr. Sedat Develi, Gülhane Military Medical Academy, Department of Anatomy, Ankara, Turkey E-mail: sedaveli@gata.edu.tr
Geliş tarihi/Received: 20.08.2016 Kabul tarihi/Accepted: 23.09.2016

DISCUSSION

Piriformis is pyramid-shaped muscle which is a landmark in the gluteal region³. Clinically it is associated with piriformis syndrome. Piriformis syndrome is also described as pseudo sciatica, extra-spinal or non-discogenic sciatica or wallet sciatica^{4,5}. 6-8% of the sciatica has been reported to be associated with piriformis syndrome⁴.

Main pathology in this syndrome is the irritation of the nerve. It may be caused by muscle hypertrophy, muscle strain, anatomic variations of muscle such as muscle slips, or variations of nerve such as proximal bifurcation or passing through the muscle^{6,7}. Although the relationship regarding the muscle and nerve was classified into six groups by Beaton and Anson⁸, in literature there are reported cases which do not comply with this classification^{4,9}.

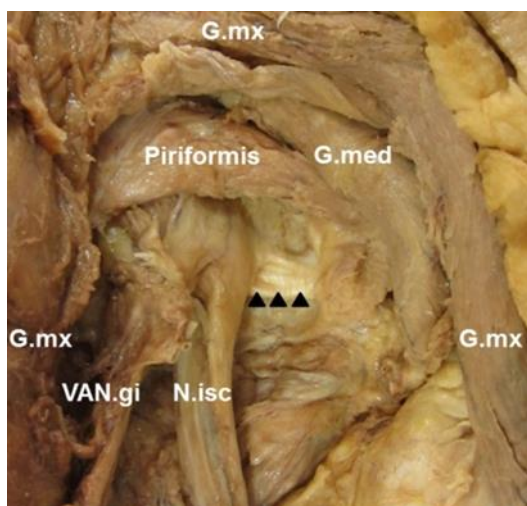


Figure 1. Gluteal region of the cadaver

Accessory piriformis muscle is seen under the n. ischiadicus (black arrow heads). G.mx: M. gluteus maximus, G.med: M. gluteus medius, N. isc: N. ischiadicus, Piriformis: M. piriformis (proper), VAN.gi: Inferior gluteal nerve and vessels

In our case, there is an accessory piriformis muscle located inferiorly to the proper muscle. Belly of the accessory muscle was crossing under the trunk of the n. ischiadicus. Since the main trunk or branches of the nerve is not piercing the muscle but passing between the muscle bellies, makes this topographical

relationship is an unclassified variation according to Benson's classification. Belly of the accessory muscle was thick and mostly tendinous. Direction of the fibers was not similar to the proper muscle which makes the case different from previously reported muscle slips, double or three-bellied variations^{4,6,9}. Piriformis syndrome is one of the extra-spinal causes of sciatica. Although a rare variation of the muscle is mentioned in this article, an approximately 18% frequency of common variations was reported in a comprehensive review⁷. Thus, this rare variation should be kept in mind in physical examination or evaluating radiological images of patients with low back pain.

REFERENCES

1. Standring S, Ellis H, Wigley C. Gray's Anatomy: The Anatomical Basis of Clinical Practice. New York, Elsevier Churchill Livingstone, 2005.
2. Michel F, Decavel P, Toussiro E, Tatu L, Aleton E, Monnier G, Garbuio P. et al. The piriformis muscle syndrome: an exploration of anatomical context, pathophysiological hypotheses and diagnostic criteria. *Ann Phys Rehabil Med.* 2013;56:300-1.
3. Jankovic D, Peng P, van Zundert A. Brief review: piriformis syndrome: etiology, diagnosis, and management. *Can J Anaesth.* 2013;60:1003-12.
4. Natsis K, Totlis T, Konstantinidis GA, Paraskevas G, Piagkou M, Koebke J. Anatomical variations between the sciatic nerve and the piriformis muscle: a contribution to surgical anatomy in piriformis syndrome. *Surg Radiol Anat.* 2014;36:273-80.
5. Ropper AH, Zafonte RD. Sciatica. *N Engl J Med.* 2015;372:1240-8.
6. Polesello GC, Queiroz MC, Linhares JPT, Amaral DT, Ono NK. Anatomical variation of piriformis muscle as a cause of deep gluteal pain: diagnosis using MR neurography and treatment. *Revista Brasileira de Ortopedia (English Edition).* 2013;48:114-7.
7. Smoll NR. Variations of the piriformis and sciatic nerve with clinical consequence: a review. *Clin Anat.* 2010;23:8-17.
8. Beaton LE, Anson BJ. The relation of the sciatic nerve and of its subdivisions to the piriformis muscle. *The Anatomical Record.* 1937;70:1-5.
9. Ravindranath Y, Manjunath KY, Ravindranath R. Accessory origin of the piriformis muscle. *Singapore Med J.* 2008;49:217-8.