

A case of foot drop secondary to a giant extraneural ganglion cyst close to the peroneal nerve

Düşük ayağa yol açan, peroneal sinir komşuluğunda dev ektranöral ganglion kisti olgusu

Elif Ilgaz AYDINLAR, Cihangir TETİK, Gökalp SILAV, Behram KAYA, Serdar ÖZGEN

ABSTRACT

Extraneural ganglion cysts of the peroneal nerve have rarely been reported in the literature. This paper reports a large extraneural ganglion cyst compressing the peroneal nerve and causing pain in the leg, and foot drop. Electromyographic study revealed a deep peroneal nerve lesion, but the superficial branch was spared. Magnetic resonance imaging showed a cystic tumor located below the superior tibiofibular joint. A complete surgical resection was undertaken. During surgery multimodal intraoperative neurophysiological monitoring was performed. An extraneural ganglion cyst should be considered in the differential diagnosis of painful foot drop. Electrophysiological and radiological studies should be carried to rule out other causes of foot drop.

Key words: Foot drop, Extraneural ganglion, Cyst, Peroneal nerve

ÖZET

Peroneal sinirin ektranöral ganglion kistlerine literatürde az rastlanmaktadır. Bu makalede bacakta ağrı ve düşük ayağa yol açan, peroneal sinire dışarıdan bası yapan, geniş çaplı bir ektranöral ganglion kisti olgusu sunuldu. Elektromiyografi peroneal sinirin derin dal tutulumuna işaret etti. Manyetik rezonans görüntüleme ise tibiofibular eklem distalinde kistik bir lezyonu ortaya koydu. Ameliyat esnasında multimodal nörofizyolojik monitörizasyon yapıldı. Hastada kist tümüyle rezekt edildi. Ektranöral peroneal ganglion kisti, ağrılı düşük ayak nedenleri arasında akla getirilmelidir.

Anahtar kelimeler: Düşük ayak, Ektranöral ganglion, Kist, Peroneal sinir

Introduction

Although ganglion cysts occur frequently, their presence in the lower extremities is rare and they seldom cause peripheral nerve compression. The most common nerve involved in the upper extremity is the ulnar nerve while passing through the cubital tunnel [1]. Peroneal neuropathy caused by a ganglion cyst, a rare pathology, was first described in 1921 [2].

Here, we report an extraneural ganglion cyst as a rare cause of foot drop due to peroneal nerve compression. The origin of an intraneural cyst is a degenerative synovial joint[3]. Extraneural cysts derive also from synovium. They are connected to joints through capsular tears, presumably for the peroneal nerve, located separately from an articular branch of the peroneal nerve.

Case report

A 36-year-old male manager presented to our clinic with dull pain starting from the right fibular head, radiating to the big toe and worsened by walking. His neurologic examination revealed paresis (2/5) of dorsiflexion of the foot and big toe. He did not complain of hypoesthesia at the same area. Ankle and knee jerks were normal. He told us that his pain started 3 years ago and that a lumbar magnetic resonance imaging (MRI), done at the time, was in the normal range.

Until one year ago the patient's symptoms seldom appeared and he did not seek medical advice. One year ago, when his pain became more intense and appeared more frequently, his consulting neurosurgeon requested an electromyography (EMG), but this did not exhibit any major abnormality. He was told not to sit cross-legged and to use cold packs whenever this condition was painful. He reported that his pain had improved over time until one month before his admission to our neurosurgery clinic, complaining of foot drop.

Another EMG showed that despite a normal nerve conduction study at the head of the fibula the peroneal compound muscle action potential amplitude recorded from the tibialis anterior and extensor digitorum brevis muscles had declined. The action potential of the superficial peroneal nerve was not affected. Needle EMG findings revealed subacute-chronic denervation of the tibialis anterior on

Elif Ilgaz Aydınlar (✉),
Department of Neurology, School of Medicine, Acibadem University, Istanbul,
Turkey
e-mail: elif.aydinlar@acibadem.edu.tr

Gökalp Silav, Serdar Özgen
Department of Neurosurgery, School of Medicine, Acibadem University,
Istanbul, Turkey

Cihangir Tetik
Department of Orthopaedics and Traumatology, School of Medicine, Acibadem
University, Istanbul, Turkey

Behram Kaya
Neurosurgery Clinic, Acibadem Maslak Hospital, Maslak, Istanbul, Turkey

Submitted/Gönderme: 02.03.2013 Accepted/Kabul: 12.04.2013

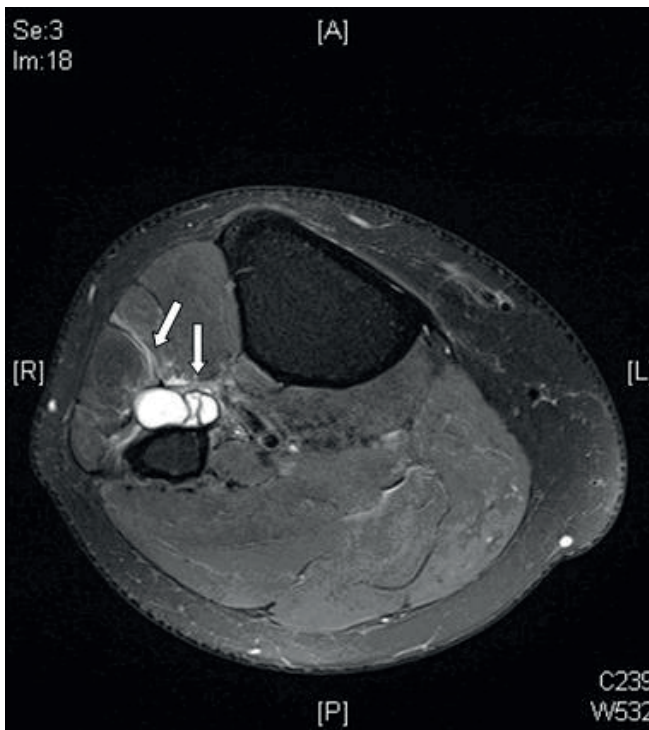


Figure 1. T2-weighted axial magnetic resonance image showing slight hyperintensity of the anterolateral muscle compartment compatible with denervation.(arrows)

the extensor hallucis longus muscles. The EMG findings supported a partial lesion of the deep peroneal branch with sparing of the superficial branch.

An MRI of the knee showed a 2.3×1.9×5.5 cm well-defined lobulated cystic mass localized at the anterior neck of the fibula, starting below the tibiofibular joint. The mass was homogenous and hypointense on T2-weighted images (Figure 1).

Surgery revealed that the cyst was located 4 cm below the neck of the fibula, at the anterior surface of the bone and pushed against the deep branch of the peroneal nerve. Meticulous dissection was performed, using loop magnification and an operating microscope. The cyst was cut from its base and curettage was performed at the joint. The mass looked like a purse in shape and contained mucinous material.

During surgery, motor evoked potentials of the muscles below both knees were studied, and bilateral tibial and peroneal somatosensory evoked potentials, were recorded. Intraoperative application of a tourniquet caused a loss in intraoperative neuromonitoring data within 15 minutes. The data reappeared within 2 minutes after the tourniquet was removed. Of these evoked responses within 15 minutes, the responses reappeared less than 2 minutes after the tourniquet was removed. There was no difference between the findings before and after the tourniquet application and there were no postoperative complications.

Histopathological evaluation of the gelatinous material verified the diagnosis of cyst.

The patient came back to full strength 10 months after surgery. His pain subsided after the 4th month.

Discussion

Although the most frequent cause of foot drop is a common peroneal neuropathy at the neck of the fibula [4], other causes include anterior horn cell disease, lumbar plexopathies, L5 radiculopathy, partial sciatic neuropathy, posttraumatic intraneural hemorrhage [5] and a nerve-sheath tumor. In our case, we excluded a possible lumbar disc herniation by a lumbosacral MRI investigation.

The common peroneal nerve is derived from L4, L5, S1 and S2 as a division of the sciatic nerve [6, 7]. Peroneal nerve entrapment is most commonly seen in the popliteal fossa, but it is rarely caused by a cyst. Synovial cysts compressing the peroneal nerve may be extraneural or intraneural [8, 9]. They are considered an anatomical variant of the same entity [10].

Most of the ganglionic cysts described in the literature causing peroneal nerve compression have been of the intraneural type [11-14]. Tehli described an intraneural cyst ascending along the sciatic nerve [15]. Extraneural ganglion cyst causing foot drop are seldom reported [9]. As in our case, extraneural cysts can compress the nerve from outside.

Radiating pain on the anterolateral surface of the leg, paraesthesia and a degree of paresis in the anterior compartment of the leg are the most common symptoms of these conditions [10]. Although our patient complained of pain, he denied any weakness as an initial symptom, right sided foot drop developed within three years of the start of his pain.

Although clinical features may indicate the level of the lesion, they are usually insufficient to establish its precise location. Electrophysiological studies are helpful in distinguishing whether it is a radiculopathy or peroneal nerve lesion. When more proximal lesions are suspected, a very useful strategy is to perform needle EMG examination of the lumbar paraspinal, gluteal and hamstring muscles. The two most important muscles to test are the short head of the biceps femoris and the tibialis anterior muscles. In our case, EMG showed that the peroneal lesion was far below the fibular neck end and that the superficial branch was not affected. Despite the absence of a palpable mass lesion, the patient underwent a MRI scan of the knee, to identify the cause. Leon and Morano emphasize the advantages of MRI for assessing soft tissue tumors [16]. However, we were unable to identify with MRI whether this case involved an intra- or extra-neural ganglion cyst.

Direct and indirect trauma to the lower limb may produce injury to the superior tibiofibular joint and cause the development of a fibular intraneural ganglion cyst [14]. In this case the history was negative for factors causing external

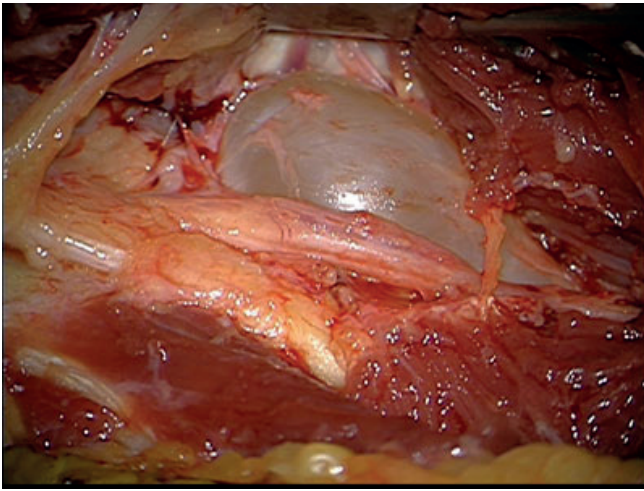
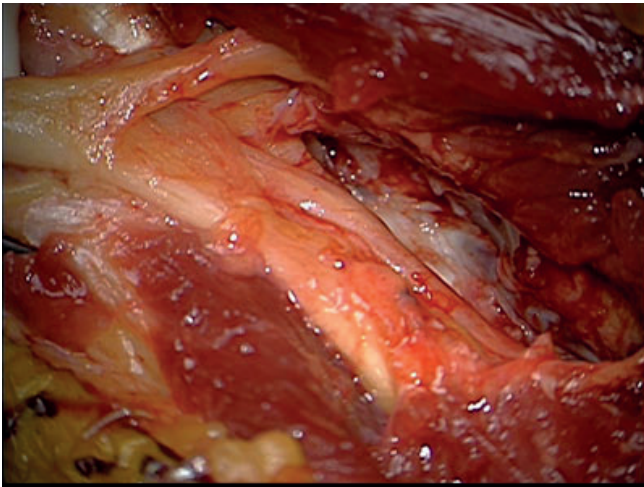


Figure 2. Intraoperative photograph showing extraneural cyst nearby the peroneal nerve, before and after (below) resection.



nerve compression at the fibular head, such as habitual leg crossing.

Compression of the peroneal nerve by an extraneural ganglion is a rare condition. After clinical evidence of a local mass and confirmation of the diagnosis with ultrasonography, computed tomography or MRI, the accepted current treatment for a peroneal nerve palsy due to peripheral compression is surgical decompression (Figure 2) [17-20].

The cyst in this case was lying between the anterior tibial artery and the peroneal nerve. The cyst originated at the proximal tibiofibular joint. Resection of the ganglion alone is not enough. The aim of treatment of this kind of ganglionic cysts is to destroy its origin in order to prevent its recurrence.

However, a ganglionic cyst causing peroneal nerve entrapment is rare. This entity should be considered in the differential diagnosis of progressive peroneal palsy.

References

1. Strickland JW, Steichen JB. Nerve tumors of the hand and forearm. *J Hand Surg* 1977; 2A: 285-91.
2. Sultan C. Ganglion der nervenscheide des nervus peroneus. *Zentralblatt für Chirurgie* 1921;48:963-5.
3. Spinner RJ, Atkinson JLD, Tiel RL. Peroneal intraneural ganglia: the importance of the articular branch. A unifying theory. *J Neurosurg* 2003 ;99: 330-43.
4. Sidey JD. Weak ankles. A study of common peroneal entrapment neuropathy. *Br Med J* 1969; 13;623-6.
5. Gurdjian ES, Larsen RD, Lindner DW. Intraneural cyst of the peroneal and ulnar nerves. Report of two cases. *J Neurosurg* 1965; 23:76-8.
6. Ducic I, Dellon AL, Graw KS. The clinical importance of variations in the surgical anatomy of the superficial peroneal nerve in the mid third of the lateral leg. *Ann Plast Surg* 2006; 56:635-8.
7. Ryan W, Mahony N, Delaney M, et al. Relationship of the common peroneal nerve and its branches to the head and neck of the fibula. *Clin Anat* 2003;16:501-5.
8. Ghossain M, Mohasseb G, Dagher F, et al. Compression of the common peroneal nerve by a sinovial cyst. *Neurochirurgie* 1987; 33:412-3.
9. Rawal A, Ratnam KR, Yin Q, et al. Compression neuropathy of common peroneal nerve caused by an extraneural ganglion: A report of two cases. *Microsurgery* 2004; 24:63-6.
10. Brooks DM. Nerve compression by simple ganglia: a review of thirteen collected cases. *J Bone Joint Surg (Br)* 1952; 34:391.
11. Coleman SH, Beredjekkian PK, Weiland AJ. Intraneuronal ganglion cyst of the peroneal nerve accompanied by complete foot drop. A case report. *Am J Sports Med* 2001; 29:238-41.
12. Johnston JA, Lyne DE. Intraneural ganglion cyst of the peroneal nerve in a four-year-old girl. *J Pediatr Orthop* 2007;27:944-6. doi: 10.1097/BPO.0b013e3181558c05.
13. Kahraman O, Akman S, Erturker E, et al. A case of an intraneural ganglion cyst in the peroneal nerve resulting in foot drop. *Acta Orthop Traumatol Turc* 2000; 34:426-9.
14. Spinner RJ, Ibrahim Elshiekh MA, et al. Posttraumatic torsional injury as an indirect cause of fibular intraneural ganglion cysts: *Clin Anat* Oct 24. doi: 10.1002/ca.21290. 2011 [Epub ahead of print]
15. Tehli O, Celikmez RC, Birgili B, et al. Pure peroneal intraneural ganglion cyst ascending along the sciatic nerve. *Turk Neurosurg* 2011;21:254-8. doi: 10.5137/1019-5149.JTN.2660-09.1, 2011
16. Leon J, Marano G. MRI of peroneal nerve entrapment due to ganglion cyst. *Magn Res Imag* 1987; 5:307-9.
17. Kim JH, Ihn YK, Kim JS, et al. Nontraumatic peroneal nerve palsy: MRI findings. *Clin Radiol* 2007; 62:58-64.
18. Ramelli GP, Nagy L, Tuncdogan E, et al. Ganglion cyst of the peroneal nerve. A differential diagnosis of peroneal nerve entrapment neuropathy. *Eur Neurol* 1999; 41:56-8.
19. Rein S, Weindel S, Schaller HE, et al. Peroneal nerve palsy caused by a recurrent proximal tibiofibular joint ganglion – a case report and review of the literature. *Handchir Mikrochir Plast Chir*; 2005; 37:267-75.
20. Yamazaki H, Saitoh S, Seki H, et al. Peroneal nerve palsy caused by intraneural ganglion. *Skeletal Radiol* 1999; 28:52-6.