



## Evaluation of Infrared Thermography Findings in Postoperative Follow-Up in Dogs with Pyometra

Dilara CEYLAN ŞENKULA<sup>1</sup>, Güneş ERDOĞAN<sup>1\*</sup>

<sup>1</sup>Aydın Adnan Menderes University, Faculty of Veterinary Medicine, Department of Obstetrics and Gynecology, Aydın, TÜRKİYE

### ABSTRACT

The usability of infrared thermography (IRT) applications in the postoperative follow-up after was investigated in dogs with pyometra. The study was carried out on 14 intact female dogs undergone ovariohysterectomy, diagnosed as pyometra (Group 1, n=7) and healthy animals (Group 2, n=7). Serum C-reactive Protein (CRP) levels were measured before the operation and on the 1<sup>st</sup>, 4<sup>th</sup>, and 7<sup>th</sup> days, postoperatively. Thermographic images from the eye and incision line were recorded, and the results were analyzed statistically. There were no intraoperative and postoperative complications in both study groups, and all dogs in Group 1 recovered uneventfully. Serum CRP levels were higher on the 0<sup>th</sup>, 4<sup>th</sup>, and 7<sup>th</sup> days in Group 1 (P<0.05), while they were at a peak level on the 1<sup>st</sup> day (P>0.05) in both groups, a decrease was observed on the 4<sup>th</sup> and 7<sup>th</sup> days (P<0.05). Postoperative CRP levels in all animals tended to decrease on the 4<sup>th</sup> and 7<sup>th</sup> days. No statistical difference between and within the eye and incision line thermographic examinations (P>0.05). While serum CRP values reached the maximum level on the 1<sup>st</sup> day after surgery in the pyometra and groups, it was seen as a milder increase due to the inflammatory reaction in the pyometra group. Due to the uncomplicated completion of the study, CRP values tended to decrease on the 4<sup>th</sup> day, and no significant difference was observed in the thermographic images. No statistical difference was observed in the temperature values taken from the eye and incision line in the pyometra group (P>0.05). Thermography is renowned as a non-invasive and practical application in clinical approaches. This technique may be included in the postoperative control systematic accompanied with CRP values in ovariohysterectomised dogs due to pyometra or elective purpose.

**Keywords:** Dog, postoperative monitoring, pyometra, thermography

## Piyometralı Köpeklerde Postoperatif İzlemede İnfrared Termografi Bulgularının Değerlendirilmesi

### ÖZET

Piyometralı köpeklerde kızılötesi termografi (IRT) uygulamalarının postoperatif izlemede kullanılabilirliği araştırıldı. Çalışma ovariohisterektomi operasyonu geçiren piyometralı (Grup 1, n=7) ve sağlıklı köpekler (Grup 2, n=7) olmak üzere 14 dişi köpekte gerçekleştirildi. Operasyon öncesi (0. gün) ve postoperatif 1, 4 ve 7. günlerde serum C-reaktif protein (CRP) düzeyi ölçüldü. Göz ve ensizyon hattından alınan termografik görüntüler kaydedildi ve istatistikî yönden incelendi. Her iki çalışma grubunda da intraoperatif ve postoperatif dönemde komplikasyon gelişmedi ve Grup 1'deki tüm köpekler sorunsuz şekilde iyileşti. Serum CRP düzeyleri Grup 1'de 0, 4 ve 7. günlerde daha yüksekti (P<0,05), her iki grupta da 1. günde pik düzeyde iken (P>0,05), 4. ve 7. günlerde azaldı (P<0,05). Tüm hayvanlarda postoperatif CRP düzeyi 4. ve 7. günlerde düşüşe geçti. Göz ve ensizyon hattından alınan termografik incelemelerde gruplar arasında fark bulunamadı (P>0,05). Piyometra ve gruplarında ameliyat sonrası 1. günde serum CRP değerleri maksimum seviyeye ulaşırken, piyometra grubunda inflamatuvar reaksiyona bağlı olarak daha hafif artış görüldü. Çalışmanın komplikasyonsuz tamamlanması nedeniyle 4. günde CRP değerleri azalma eğiliminde idi ve termografik görüntülerde belirgin bir fark görülmedi. Piyometra grubunda göz ve ensizyon hattından alınan sıcaklık değerlerinde istatistiksel bir farklılık gözlenmedi (P>0,05). Termografi, klinik yaklaşımlarda non-invaziv ve pratik bir uygulama olarak bilinmektedir. Bu teknik piyometra veya elektif amaçla ovariohisterektomi uygulanan köpeklerde CRP değerleri ile birlikte postoperatif kontrol sistematığına dahil edilebilir.

**Anahtar kelimeler:** Köpek, postoperatif izlem, piyometra, termografi

\*Corresponding Author: Güneş ERDOĞAN, Aydın Adnan Menderes University, Faculty of Veterinary Medicine, Department of Obstetrics and Gynecology, Aydın, TÜRKİYE, gerdogan@adu.edu.tr

Received Date: 13.10.2022 - Accepted Date: 7.11.2022 DOI: 10.53913/aduveterinary.1174712

## Introduction

Cystic endometrial hyperplasia-pyometra complex (pyometra) is a fatal disease in adult female dogs, characterized by pathological changes in the endometrium and systemic findings due to long-term exposure to progesterone and mutual interaction with bacteria (Franson and Ragle, 2003). Although the disease can be seen at almost any age, it is more common in nulliparous and old dogs, and its incidence increases with age. Different complications that will develop after the surgical approach in the treatment of pyometra are clinically significant; mortality is seen between 5-8%. Deaths are primarily due to sepsis or bacterial peritonitis, kidney and liver failures (Franson and Ragle, 2003; Jitpean et al., 2014).

In terms of preventing complications after the surgical operation and determining the prognosis, the serum concentration of acute phase proteins changes by at least 25% with the effect of pro- or anti-inflammatory cytokines. C-reactive protein (CRP), one of the crucial acute phase proteins, is produced in the liver in response to increased concentrations of proinflammatory cytokines (Eckersall and Bell, 2010). In dogs, it is increased in systemic inflammation following surgery, trauma, various infections, or neoplasia. Moreover, it is a reliable diagnostic marker for systemic inflammation (Christensen et al., 2015; Martinez-Subiela et al., 2011; Petersen et al., 2004; Slavov et al., 2011). The measurement of CRP levels in the postoperative period in dogs effectively determined the prognosis, and routine operations were used to check the healthy status (Dabrowski et al., 2009; Nevill et al., 2010; Serin and Ulutaş, 2010). It was observed that CRP concentration increased at 6 hours following the various surgical approaches (Mathon et al., 2011) and reached its maximum level at 12-24 hours (Freeman et al., 2009; Nevill et al., 2010; Saunders et al., 2009). CRP concentrations, which increase significantly during the few days following surgery (Freeman et al., 2009; Mathon et al., 2011), begin to decline due to gradual homeostasis during average postoperative recovery (Dabrowski et al., 2007). It may take one week (Mathon et al., 2011), two weeks (Zhang et al., 2013), or longer (Dabrowski et al., 2007) to return to the preoperative level.

Infrared Thermography (IRT) is a real-time, non-invasive, side-effect-free method used as an additional diagnostic tool in veterinary medicine (Franco et al., 2019; Vollmer and Mölmann, 2017). It provides the opportunity to view the changes in the skin surface temperature without touching the tissue, using a catheter or contrast material. This method allows us to view the changes in infection (Yang et al., 2018); animal welfare assessment and feed efficiency can be monitored (Cilulko et al., 2013; Martins et al., 2013; Stewart et al., 2007). In addition, IRT has been used to evaluate tissue healing by cold versus hot marking (Howe, 2006).

In the presented study, it was aimed to investigate the usability of IRT images to be taken during the first week following the operative treatment, especially in dogs

diagnosed with pyometra, in the evaluation of the patient's general condition and wound healing, and to evaluate the relationship between the postoperative thermographic results and serum CRP levels.

## Materials and Methods

Fourteen female dogs, 2-12 year old, were used in the study among the owned dogs brought to Aydın Adnan Menderes University, Faculty of Veterinary Medicine, Department of Obstetrics and Gynecology, without age or breed discrimination. During the study, the patients' perioperative general/reproductive examinations and ovariohysterectomy operations were carried out following the regulations of Aydın Adnan Menderes University Experimental Animals Application and Research Center and in line with the relevant ethics committee decision (64583101/2019/093).

In the study, it was used 14 female dogs divided into two main groups. In the first group, there were intact female dogs with variable (sanguineous/mucopurulent/purulent) vaginal discharge, polyuria, polydipsia, vomiting, diarrhea, and one or more other symptoms such as anorexia, lethargy, and depression. Moreover, confirmation of uterine infection was performed ultrasonographically (Group 1, n=7). Second group consisted healthy female dogs undergone elective ovariohysterectomy as control (Group 2, n=7). The number of dogs in groups was assigned following power test, statistically. After the anamnesis information and general examination, serum was extracted from the venous blood samples, and hemogram values were examined. In addition, the size and contents of the uterus were evaluated by transabdominal ultrasonography (My Lab-Vet 30, Esaote<sup>®</sup>-Italy). After all these examinations, dogs with a definite diagnosis of pyometra were included in the study. For the control group (Group 2) of the study, healthy female dogs (n=7) brought to our clinic with the request of elective sterilization were used and spayed via ovariohysterectomy. In addition, the general health status of the dogs allocated for the control group was checked, it was confirmed that they did not have any genital pathology after ultrasonographic examination, and attention was paid for all dogs were in the diestrus or anestrus. Venous blood samples were taken from all dogs in the study during the preoperative period; temperature, hemogram, and serum biochemical parameters (BUN, Creatinine, ALP, GPT, GGT, Total Bilirubine, Total Protein, CRP) measurements were recorded. Food and fluid intake was stopped 12 hours before the surgery. All operations during the study were performed from the median line and following standard procedures (Howe, 2006) under inhalation anesthesia using a combination of medetomidine (Medetomidine, Domitor<sup>®</sup>, Pfizer<sup>®</sup>, Finland) – isoflurane (Isoflurane USP<sup>®</sup>, Istanbul, Türkiye). After stabilization of the patients, the operation area was shaved, disinfected with iodinated antiseptic solutions, and prepared according to the necessary asepsis-antiseptis rules. Following the incision above the linea alba, both ovaries and hor-

ns were ligated and removed in routine applications, as previously stated (Hove, 2006). After the tissues were removed, an antibiotic (Unacefin®, Istanbul, Türkiye) was applied to the intra-abdominal cavity. After controlling all ligations, the closing the abdominal wall, the skin was closed with a hidden subcutaneous suture.

The operation day was recorded as the start of the study (day 0). At the end of the operation, a single dose of meloxicam (Bavet Meloxicam® Bavet, Istanbul, Türkiye) and antisedative atimepazole hydrochloride (Atipamezole, Antisedan®, Pfizer®, Finland) were administered for analgesia. Again, starting with the end of the operation, antibacterial treatment was performed with 10 mg/kg of intramuscular amoxicillin-clavulanic acid (Synulox®, Pfizer, Istanbul, Türkiye) for seven days.

Serum CRP levels were measured from venous blood samples taken on preoperative and postoperative 1<sup>st</sup>, 4<sup>th</sup>, and 7<sup>th</sup> days for patient follow-up. In addition, thermographic images were recorded by performing IRT over the eye and incision line on days 1-4 and 7. Image samples were taken from the face and operation area with an infrared Thermal camera (Flir, E6- Flir Systems®-Sweden). The changes in the temperature of the region were recorded and evaluated in terms of local and general infection. All dogs were rested for 15 minutes at room temperature in an environment without air flow, and then the thermal measurement was made at a vertical angle from an average distance of 1 meter to the operation line (Figure 1, Figure 2). After the thermographic measurement, a venous blood sample was taken, and a CRP measurement was performed with a rapid test kit (Test-sealabs®, Hangzhou, China).

On the relevant days, the general health status of all dogs (rectal body temperature, appetite level, pain symptoms) was recorded, and possible hyperemia, hyperthermia, and bloody-serous discharge in the wound area were investigated. In addition, the possible contribution of the thermographic findings to the postoperative patient condition and complications diagnosis were evaluated.

Statistical Package for the Social Sciences 22.0 (SPSS,

IBM SPSS Statistics®, Chicago, IL, USA) package program was used for the statistical evaluation of the data obtained in this study. Distribution analysis of the data was performed using the Kolmogorov–Smirnov test. Parametric tests were applied to the parameters with a normal distribution (eye, abdomen). In this context, the Independent samples t-test was used to determine the differences between groups at each measurement time. In addition, the time-dependent variation of these parameters within the group was evaluated by repeated-measures analysis of variance, and the sampling time of the differences was evaluated with the post-hoc Bonferroni test. It was determined that serum CRP levels did not show a normal distribution despite the logarithmic transformation, and the intergroup evaluation of this parameter was evaluated with the Mann-Whitney U test. The time-dependent changes within the group were evaluated with the Friedman test.  $P < 0.05$  was considered significant in all analyses.

## Results

During a total of 14 ovariohysterectomy operations performed during the study. Any intra/postoperative complications were not recorded as major bleeding, mesovarium, and/or uterine rupture, especially anesthesia-related complications, and related death did not occur during the monitoring period of the dogs. After one week of antibacterial and analgesic applications, the pyometra and control groups achieved the desired clinical improvement.

Postoperatively, no rectal temperature increase, opening in the incision line, seroma, or other local infection symptoms were observed in both groups. In all study material, it was observed that the surgical incision line was at a lower temperature than the surrounding tissues. However, the caudal part of the incision line was lighter in color than the cranial part. The lowest thermal temperature image was at the nipples, displayed in purple-blue. Regarding secondary infections that may occur due to suppressed immune response in the postoperative period, enlargement of various lymph nodes (mandibular, prescapular, popliteal) was not observed in our spayed

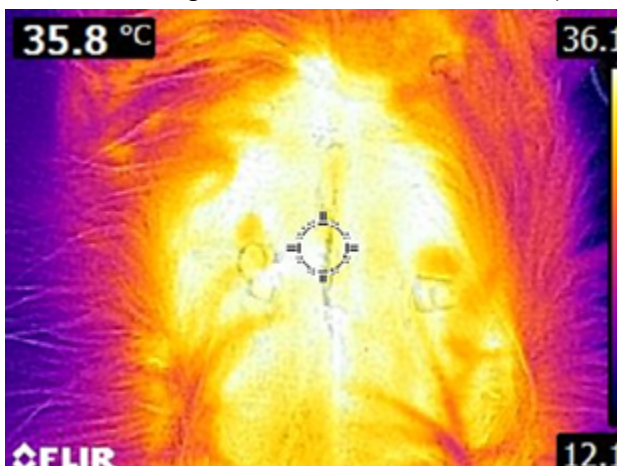


Figure 1. Incision line focused thermal image example of Group 1 (Pyometra).

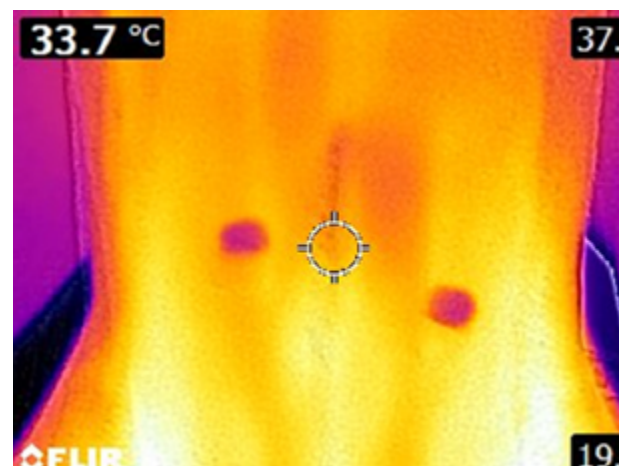


Figure 2. Incision line focused thermal image example of Group 2 (Control).

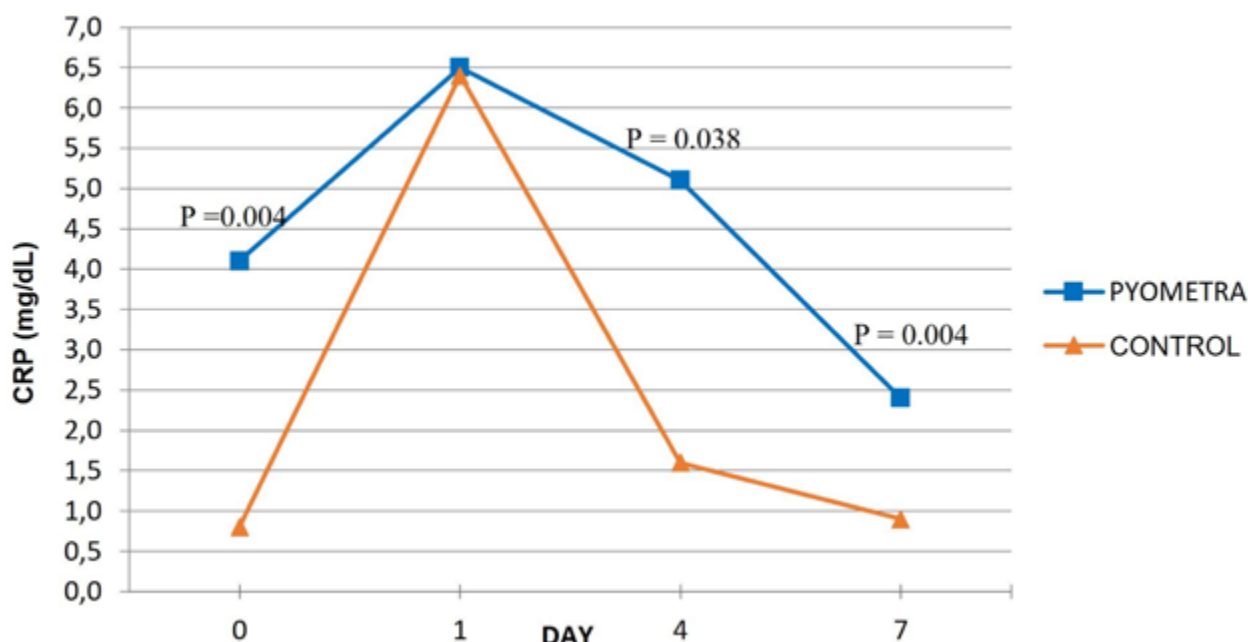


Figure 3. The mean serum CRP levels of the study groups (mg/dL).

dogs for seven days.

The mean age was 6.8 years in Group 1 and 3.7 years in Group 2, and mean rectal temperature values were measured as 39 °C in Group 1 and 38.7 °C in Group 2. No hyperthermia was observed in any animal during the postoperative 7-day period. Four patients of Group 1 had an active vaginal discharge in the preoperative period.

Accordingly, mean serum CRP values on days 0-1-4 and 7, for Group 1 were 4.1±0.95 mg/dL, 6.5±0.37 mg/dL, 5.1±0.95 mg/dL and 2.38±0.51 mg/dL; and for Group 2 were 0.84±0.25 mg/dL, 6.4±0.29 mg/dL, 1.58±0.22 mg/dL and 0.87±0.1 mg/dL, respectively. As a result of the statistical measurements, a significant increase ( $P>0.05$ ) was observed in the first 24 hours following the operation; It showed a significant decrease on the 4<sup>th</sup> day ( $P<0.05$ ) (Figure 3).

CRP level of Group 1 (pyometra) was significantly higher

on day 0 ( $P<0.01$ ); on Day 4 ( $P<0.05$ ) and Day 7 ( $P<0.01$ ). However, there was no difference between the groups on the 1st day when the serum CRP levels were maximum ( $P>0.05$ ). As time-dependent variation for Group 1: significant between the 1st and 7th days ( $P<0.01$ ), a moderate ( $P<0.05$ ) difference between the 1st and 4th days were seen. For Group 2: significant difference was found between preoperative and 1st days ( $P<0.05$ ); also, between the 1st and 7th days ( $P<0.05$ ). Since the preoperative CRP level of Group 2 was lower, it gave a faster and more dramatic response to the surgical intervention. Afterward, it showed a tendency to decline rapidly.

The mean values of the IRT results taken over the eye and incision line for postoperative follow-up are presented in Table 1 and Table 2. Thermal images of the eye and the incision line of both groups were recorded on days 1-4 and 7 after surgery were recorded. The values of the acquired images are shown in Figure 4 and Figure 5.

Table 1. The mean eye temperature of the study groups (°C).

Days	Group 1 (n=7) (Pyometra) $\bar{x} \pm S$	Group 2 (n=7) (Control) $\bar{x} \pm S$	P
1	33.72 ± 0.19	33.40 ± 0.88	0.72
4	33.88 ± 0.28	33.67 ± 0.74	0.79
7	33.21 ± 0.26	33.85 ± 0.15	0.06
P	0.21	0.77	

$P<0.05$ : Significant difference between study groups.

**Table 2.** The mean incision line temperatures of study groups (°C).

Days	Group 1 (n=7) (Pyometra) $\bar{X} \pm S$	Group 2 (n=7) (Control) $\bar{X} \pm S$	P
1	35.50 ± 0.14	35.10 ± 0.15	0.21
4	35.60 ± 0.22	34.64 ± 0.57	0.14
7	35.51 ± 0.41	35.30 ± 0.21	0.65
<b>P</b>	0.93	0.52	

P<0.05: Significant difference between study groups.

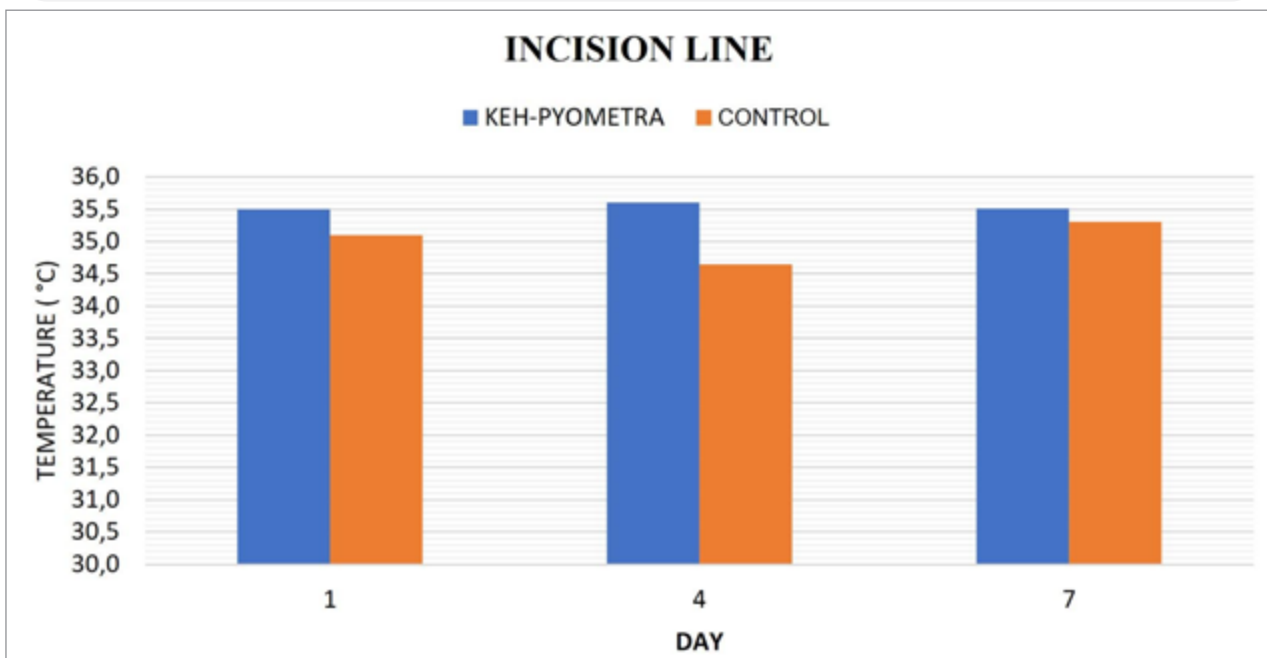


Figure 4. The mean incision line temperature of the study groups (°C).

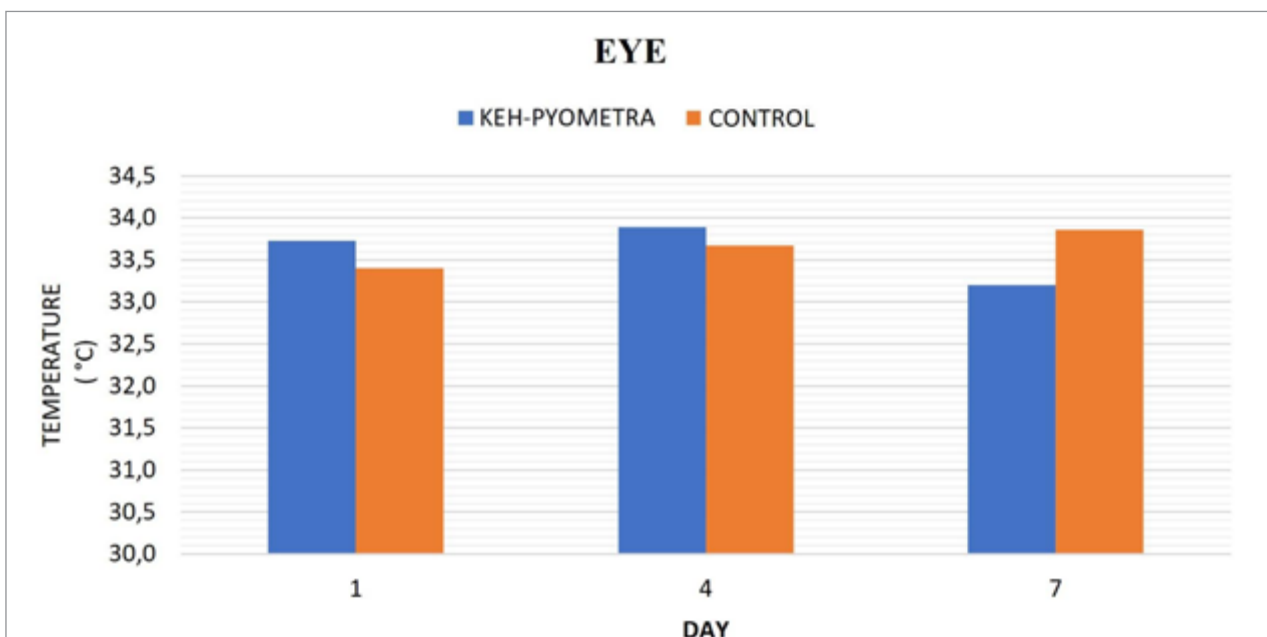


Figure 5. The mean eye temperature of the study groups (°C).

Statistically, no difference was observed in the in-group and between-group evaluations ( $P>0.05$ ).

### Discussion

Pyometra is a widespread phenomenon in intact adult female dogs and has an important place in the patient portfolio of small animal clinics. Medical treatment methods are tried in a minimal group, but generally, patients can be cured with radical operations (Franson and Ragle, 2003). Although ovariectomy is a routine practice with well-defined borders, new applications that will determine the prognosis in the postoperative period are vital in increasing physicians' clinical success. Our literature research found no thermographic study example after pyometra operation in dogs. In this respect, it can be accepted that our study is a first in its field.

In the presented study, it was aimed to investigate the usability of IRT images to be taken during the first week following the operative treatment, especially in dogs diagnosed with pyometra, in the evaluation of the patient's general condition and wound healing and to evaluate the relationship between the postoperative thermographic results and serum CRP levels. At the end of the first 24 hours after the surgical intervention, the serum CRP level was found to be at its maximum level for both groups. Therefore, in the postoperative follow-up of spayed dogs, CRP results at about 6 ng/mL in the 1st-day controls can be a reference value for healthy groups and can be evaluated in routine applications. Serum CRP values have been evaluated as a reliable parameter for monitoring the postoperative period in dogs (Dabrowski et al., 2009; Jitpean et al., 2014). In addition, CRP is an inflammatory product marker for complications ranging from local complications to severe septic responses (Black et al., 2004; Löfqvist et al., 2018). Since it is known that using ketamine as an anesthetic causes a decrease in postoperative CRP concentration (Liao et al., 2014; Singh et al., 2020), inhalation anesthesia was preferred in our study, besides its safety in dogs with pyometra that are in older ages and have high renal dysfunction risks. In this respect, it is clear that physicians who want to follow up with CRP should be careful about the anesthetic agent they will use. Due to the CRP measurements' limited prognostic value to be made preoperatively or once afterward (Jitpean et al., 2014), periodic sampling was performed at least three times during the first week.

At the beginning of the study, the serum CRP value was higher in the pyometra group ( $P<0.01$ ), and the peak value on the 1st day following the operation in both study groups is in line with the literature (Mathon et al., 2011; Nevill et al., 2010). Results in the range of 6-6.5 mg/dl on the first day were the maximum values achieved for uncomplicated cases. However, 296.6 µg/ml were seen as local complications. In that study, the maximum increase in CRP level was detected on the 4<sup>th</sup> day in the presence of redness at the wound line, hyperthermia at the incision line, and local bloody-serous discharge in the postoperative period in dogs with pyometra (Dabrowski et al.,

2009). Again, the inflammatory response to the surgical intervention can be observed on the 1<sup>st</sup> and 4<sup>th</sup> postoperative days (Albert et al., 2019). In our study, the tendency to CRP levels to decrease is a typical situation in both groups in which rectal temperature and other vital values remained stable on the control days and no complications were observed. However, this decrease progressed more slowly in the pyometra group and more rapidly in the control group than in the control group. This situation is very positive in determining the prognosis, and it has been found clinically very useful to take the relevant measurements quickly, easily, and cheaply.

Postoperative wound care is one of the essential steps of clinical recovery. In animal studies, thermographic monitoring is used after burns, thrombosis formations, various malformations, oncological surgical interventions, and flap applications (Casas-Alvarado et al., 2020; Hummelink et al., 2020; Kraemer et al., 2011). Research in this area has high standardization and precision in median incision line examination results. Determining the criteria for wound control and the presence of sensitive techniques are essential in reducing complications, in this respect, quick and practical evaluations by small-sized thermal cameras are effective. In this study's results, in the abdominal images, by the literature, it was seen that the coldest points of the region are the nipples and the incision line. Again, in parallel with the same study results, the temperature increase in the caudal part of the incision line was detected in the color change in the thermal images. Gumpert Herlofson (2017) reported that the coldest points of the abdominal images were the nipples and the incision line. Meanwhile, a high temperature was detected on the caudal abdominal wall, which was thought to be associated with the increasing friction effect (Gumpert Herlofson, 2017). Since the imaging sample was evaluated from a single area along the incision line in our study, it was decided that more sensitive evaluations could be made with two samples taken from the most cranial and the most caudal point of the incision, especially in large dogs. An increase in temperature due to inflammation is expected in infective wounds, such as in diabetic foot cases (Slavov et al., 2011).

The thermal effects are seen differently. Immediately after the operation, regardless of the level of infection, decreased temperature in the region related to the accumulation of interstitial fluid rich in glucosamine, salt, and plasma proteins (Wiig and Swartz, 2012). Depending on the amount and location of fluid accumulation, the distribution of cold foci in thermal images varies. In cases without infection formation, the region's temperature rises with the formation of new capillaries and the onset of the healing process. However, in case of infection in the incision line, cold foci begin to be seen in thermography. Researchers noted that infective surgical wounds have cold areas in the first 4 days after colorectal surgery and are viewed at a lower temperature than healthy surgical wounds (Siah et al., 2019). Additionally, on the cesarean sections in obese women, temperature drops around 2

°C, which started on the second day, were interpreted as an infection (Childs et al., 2016). Thick subcutaneous adipose tissue in obese individuals but low vascularization is also effective in imaging the region as cold. In a similar study, cold areas on the 7<sup>th</sup> day after a cesarean section were accepted as a meaningful sign in terms of infection, and it was observed that a decrease of 1 °C in the temperature of the incision line increased the risk of infection three times (Childs et al., 2019). In addition, cooling is more severe in obese patients due to subcutaneous adipose tissue's high thermal insulation capacity (Zhang et al., 2013). In our study, no obese dog was in both study group, and neither skin cooling nor infection signs were observed. There was no delay in wound healing, the opening of the sutures, or open wound formation; also, postoperative vital values were within normal limits. Again, no difference was observed in response to stimuli, activity, appetite level, urination, and defecation behaviors according to follow-up anamnesis. During the establishment of the working hypothesis, the higher risk of postoperative infection in the pyometra group was expected to affect the results of the thermographic examination. Despite the lack of a statistical difference, the numerically higher temperature of the area compared to the control group can be explained by the successful use of postoperative antibiotics, where the healing process is at the desired level.

Since the study was completed without complications, there were no differences in IRT results between the pyometra and control groups. Similar conclusions have been made in previous studies, and wound thermography performed within two weeks postoperatively is not sufficient for diagnosis of infection unless significant complications occur (Gumpert Herlofson, 2017). However, it can be thought that these results may change with the development and use of more sensitive thermal cameras in the future. Although it is not statistically, higher temperature values were seen for the eye on the 1st and 4th days and the incision line on all days in the pyometra group. The eye temperature to be taken in the range of 33-34 °C at optimum room temperature will be considered normal for dogs. Due to the limited study material, possible differences might not be detected statistically. Therefore, it will be beneficial to apply a similar method to a much larger number of materials in the future. Patient follow-up via postoperative IRT seems to be a promising alternative, especially for laboratory animals and wild species having handling difficulties.

It was observed that dogs with pyometra showed significant changes in serum CRP levels, even if no complications were observed after surgical treatment. The change caused by the inflammatory reaction after surgery is more evident in elective operations. The response to surgery was relatively low in the patient group since CRP levels were higher in the preoperative period. While serum CRP decreased slower in dogs with the uneventful operation and postoperative recovery, it decreased more rapidly in healthy dogs.

## Conclusion

It was possible to measure the wound area and general body temperature with IRT after abdominal operations in environments where remote monitoring is required to prevent increased stress response in the patient. IRT findings may help evaluate the patient's clinical recovery more accurately, for the level of vascularization and thus healing of surgical wounds, and for the early diagnosis of possible infections. Although IRT has not been widely used in patients' routine control procedures after sterilization operations, this technique may be included in the postoperative control systematic accompanied with CRP values in ovariohysterectomized dogs due to pyometra or elective purpose.

## Acknowledgments

The authors would like to thank Aydın Adnan Menderes University Scientific Research Projects Unit for funding this research project numbered VTF-20014.

## Conflict of Interest

The authors declare that they have no conflict of interest in this study.

## References

- Albert, R., Reese, S., Nolff, M. C., & Meyer-Lindenberg, A. (2019). Evaluation of Systemic Effects of Negative Pressure Wound Therapy in Open Wound Treatment in Dogs. *VCOT Open*, 2(2), e1–e8. <https://doi.org/10.1055/s-0039-1693007>
- Black, S., Kushner, I., & Samols, D. (2004). C-reactive protein. *Journal of Biological Chemistry*, 279(47), 48487–48490. <https://doi.org/10.1074/jbc.R400025200>
- Casas-Alvarado, A., Mota-Rojas, D., Hernández-Ávalos, I., Mora-Medina, P., Olmos-Hernández, A., Verduzco-Mendoza, A., Reyes-Sotelo, B., & Martínez-Burnes, J. (2020). Advances in infrared thermography: Surgical aspects, vascular changes, and pain monitoring in veterinary medicine. *Journal of Thermal Biology*, 92, 102664. <https://doi.org/10.1016/j.jtherbio.2020.102664>
- Childs, C., Siraj, M. R., Fair, F. J., Selvan, A. N., Soltani, H., Willmott, J., & Farrell, T. (2016). Thermal territories of the abdomen after caesarean section birth: Infrared thermography and analysis. *Journal of Wound Care*, 25(9), 499–512. <https://doi.org/10.12968/jowc.2016.25.9.499>
- Childs, C., Wright, N., Willmott, J., Davies, M., Kilner, K., Ousey, K., Soltani, H., Madhuvrata, P., & Stephenson, J. (2019). The surgical wound in infrared: thermographic profiles and early stage test-accuracy to predict surgical site infection in obese women during the first 30 days after caesarean section. *Antimicrobial Resistance & Infection Control*, 8(1), 7. <https://doi.org/10.1186/s13756-018-0461-7>
- Christensen, M. B., Eriksen, T., & Kjelgaard-Hansen, M. (2015). C-reactive protein: Quantitative marker of surgical trauma and post-surgical complications in dogs: A systematic review. *Acta Veterinaria Scandinavica*, 57(1), 71. <https://doi.org/10.1186/s13028-015-0164-5>
- Cilulko, J., Janiszewski, P., Bogdaszewski, M., & Szczygielska, E. (2013). Infrared thermal imaging in studies of wild animals. *European Journal of Wildlife Research*, 59(1), 17–23. <https://doi.org/10.1007/s10344-012-0688-1>
- Dabrowski, R., Kostro, K., Lisiecka, U., Szczubiał, M., & Krakowski, L. (2009). Usefulness of C-reactive protein, serum amyloid A component, and haptoglobin determinations in bitches with pyometra for monitoring early post-ovariohysterectomy complications. *Theriogenology*, 72(4), 471–476. <https://doi.org/10.1016/j.theriogenology.2009.03.017>
- Dabrowski, R., Wawron, W., & Kostro, K. (2007). Changes in CRP, SAA

- and haptoglobin produced in response to ovariectomy in healthy bitches and those with pyometra. *Theriogenology*, 67(2), 321–327. <https://doi.org/10.1016/j.theriogenology.2006.07.019>
- Eckersall, P. D., & Bell, R. (2010). Acute phase proteins: Biomarkers of infection and inflammation in veterinary medicine. *Veterinary Journal*, 185(1), 23–27. <https://doi.org/10.1016/j.tvjl.2010.04.009>
- Franco, N. H., Gerós, A., Oliveira, L., Olsson, I. A. S., & Aguiar, P. (2019). ThermoLabAnimal – A high-throughput analysis software for non-invasive thermal assessment of laboratory mice. *Physiology and Behavior*, 207, 113–121. <https://doi.org/10.1016/j.physbeh.2019.05.004>
- Fransson, B., & Ragle, C. (2003). Canine pyometra: an update on pathogenesis and treatment. *Compendium on Continuing Education for the Practising Veterinarian*, 25, 602–612. [www.VetLearn.com](http://www.VetLearn.com)
- Freeman, L. J., Rahmani, E. Y., Sherman, S., Chiorean, M. v., Selzer, D. J., Constable, P. D., & Snyder, P. W. (2009). Oophorectomy by natural orifice transluminal endoscopic surgery: feasibility study in dogs. *Gastrointestinal Endoscopy*, 69(7), 1321–1332. <https://doi.org/10.1016/j.gie.2008.10.028>
- Gumpert Herlofson, E. (2017). *The use of thermography in evaluation of surgical wounds in small animal practice*. Second cycle, A2E. Uppsala: SLU, Dept. of Clinical Sciences.
- Howe, L. M. (2006). Surgical methods of contraception and sterilization. *Theriogenology*, 66(3), 500–509. <https://doi.org/10.1016/j.theriogenology.2006.04.005>
- Hummelink, S., Kruit, A. S., van Vlaenderen, A. R. W., Schreinemachers, M. J. M., Steenbergen, W., & Ulrich, D. J. O. (2020). Post-operative monitoring of free flaps using a low-cost thermal camera: a pilot study. *European Journal of Plastic Surgery*, 43(5), 589–596. <https://doi.org/10.1007/s00238-020-01642-y>
- Jitpean, S., Holst, B. S., Höglund, O. v., Pettersson, A., Olsson, U., Strage, E., Södersten, F., & Hagman, R. (2014). Serum insulin-like growth factor-I, iron, C-reactive protein, and serum amyloid A for prediction of outcome in dogs with pyometra. *Theriogenology*, 82(1), 43–48. <https://doi.org/10.1016/j.theriogenology.2014.02.014>
- Kraemer, R., Lorenzen, J., Knobloch, K., Papst, S., Kabbani, M., Koennecker, S., & Vogt, P. M. (2011). Free flap microcirculatory monitoring correlates to free flap temperature assessment. *Journal of Plastic, Reconstructive and Aesthetic Surgery*, 64(10), 1353–1358. <https://doi.org/10.1016/j.bjps.2011.04.030>
- Liao, P. Y., Chang, S. C., Chen, K. S., & Wang, H. C. (2014). Decreased postoperative C-reactive protein production in dogs with pyometra through the use of low-dose ketamine. *Journal of Veterinary Emergency and Critical Care*, 24(3), 286–290. <https://doi.org/10.1111/vec.12178>
- Löfqvist, K., Kjelgaard-Hansen, M., & Nielsen, M. B. M. (2018). Usefulness of C-reactive protein and serum amyloid A in early detection of postoperative infectious complications to tibial plateau leveling osteotomy in dogs. *Acta Veterinaria Scandinavica*, 60(1), 30. <https://doi.org/10.1186/s13028-018-0385-5>
- Martínez-Subiela, S., Caldin, M., Parra, M. D., Ottolini, N., Bertolini, G., Bernal, L. J., García-Martínez, J. D., & Cerón, J. J. (2011). Canine C-reactive protein measurements in cerebrospinal fluid by a time-resolved immunofluorimetric assay. *Journal of Veterinary Diagnostic Investigation*, 23(1), 63–67. <https://doi.org/10.1177/104063871102300109>
- Martins, R. F. S., do Prado Paim, T., de Abreu Cardoso, C., Stéfano Lima Dallago, B., de Melo, C. B., Louvandini, H., & McManus, C. (2013). Mastitis detection in sheep by infrared thermography. *Research in Veterinary Science*, 94(3), 722–724. <https://doi.org/10.1016/j.rvsc.2012.10.021>
- Mathon, D. H., Paliarne, S., Meynaud-Collard, P., Layssol-Lamour, C., Dulaurent-Ferrieres, A., Colson, A., Lacroix, M., Bousquet-Melou, A., Delverdier, M., & Autefage, A. (2011). Laparoscopic-Assisted Colopexy and Sterilization in Male Dogs: Short-Term Results and Physiologic Consequences. *Veterinary Surgery*, 40(4), 500–508. <https://doi.org/10.1111/j.1532-950X.2011.00835.x>
- Nevill, B., Leisewitz, A., Goddard, A., & Thompson, P. (2010). An evaluation of changes over time in serum creatine kinase activity and C-reactive protein concentration in dogs undergoing hemilaminectomy or ovariectomy. *Journal of the South African Veterinary Association*, 81(1), 22–26. <https://doi.org/10.4102/jsava.v81i1.90>
- Petersen, H. H., Nielsen, J. P., & Heegaard, P. M. H. (2004). Application of acute phase protein measurements in veterinary clinical chemistry. *Veterinary Research*, 35(2), 163–187. <https://doi.org/10.1051/vetres:2004002>
- Saunders, A. B., Hanzlicek, A. S., Martinez, E. A., Stickney, M. J., Steiner, J. M., Suchodolski, J. S., & Fosgate, G. T. (2009). Assessment of cardiac troponin and C-reactive protein concentrations associated with anesthetic protocols using sevoflurane or a combination of fentanyl, midazolam, and sevoflurane in dogs. *Veterinary Anaesthesia and Analgesia*, 36(5), 449–456. <https://doi.org/10.1111/j.1467-2995.2009.00483.x>
- Serin, G., & Ulutas, P. A. (2010). Measurement of serum acute phase proteins to monitor postoperative recovery in anoestrous bitches after ovariectomy. *Veterinary Record*, 166(1), 20–22. <https://doi.org/10.1136/vr.b5585>
- Siah, C. J. R., Childs, C., Chia, C. K., & Cheng, K. F. K. (2019). An observational study of temperature and thermal images of surgical wounds for detecting delayed wound healing within four days after surgery. *Journal of Clinical Nursing*, 28(11–12), 2285–2295. <https://doi.org/10.1111/jocn.14832>
- Singh, D., Kashav, R., Magoon, R., Kohli, J. K., Kaur, M., Gupta, A., & Gupta, V. (2020). Evaluation of Low-Dose Ketamine on Inflammatory Biomarker Profile Following Off-Pump Coronary Artery Bypass Grafting. *Journal of Cardiac Critical Care TSS*, 04(01), 33–39. <https://doi.org/10.1055/s-0040-1713299>
- Slavov, E., Mircheva Georgieva, T., Andonova, M., Urumova, V., Girginov, D., & Dzhelebov, P. (2011). Blood C reactive protein (CRP) and fibrinogen concentrations during staphylococcal experimental infection in obese dogs. *Revue de Medecine Veterinaire*, 162(12), 599–603.
- Stewart, M., Webster, J. R., Verkerk, G. A., Schaefer, A. L., Colyn, J. J., & Stafford, K. J. (2007). Non-invasive measurement of stress in dairy cows using infrared thermography. *Physiology and Behavior*, 92(3), 520–525. <https://doi.org/10.1016/j.physbeh.2007.04.034>
- Vollmer, M., & Möllmann, K. P. (2017). Infrared thermal imaging: Fundamentals, research and applications. In *Infrared thermal imaging: Fundamentals, research and applications* (2<sup>nd</sup> ed.). <https://doi.org/10.1002/9783527693306>
- Wiig, H., & Swartz, M. A. (2012). Interstitial fluid and lymph formation and transport: Physiological regulation and roles in inflammation and cancer. *Physiological Reviews*, 92(3), 1005–1060. <https://doi.org/10.1152/physrev.00037.2011>
- Yang, C., Li, G., Zhang, X., & Gu, X. (2018). Udder skin surface temperature variation pre- and post- milking in dairy cows as determined by infrared thermography. *Journal of Dairy Research*, 85(2), 201–203. <https://doi.org/10.1017/S0022029918000213>
- Zhang, S. X., Wang, H. bin, Zhang, J. T., Zhang, N., & Pan, L. (2013). Laparoscopic colopexy in dogs. *Journal of Veterinary Medical Science*, 75(9), 1161–1166. <https://doi.org/10.1292/jvms.12-0538>