



## The Effect of Ulipristal Acetate on Surgical Endometriosis Created in Rats

## Ulipristal Asetatın Ratlarda Oluşturulan Cerrahi Endometriozise Etkisi

Mehmet Nuri Duran<sup>a\*</sup>, Hacı Öztürk Şahin<sup>b</sup>, Nihal Kılınç<sup>c</sup>, Bülent Demir<sup>d</sup><sup>a</sup> Operatör Doktor, Kadın Hastalıkları ve Doğum, Midyat Devlet Hastanesi, Mardin, Türkiye. ORCID: <https://orcid.org/0000-0001-6925-711X><sup>\*</sup> İletişimden sorumlu yazar, E-mail: [mnduran34@gmail.com](mailto:mnduran34@gmail.com)<sup>b</sup> Doçent Doktor, Jinekolojik Onkoloji Cerrahisi, Bursa Şehir Hastanesi, Bursa, Türkiye. ORCID: <https://orcid.org/0000-0002-7915-8235><sup>c</sup> Profesör Doktor, Tıbbi Patoloji, Çanakkale Onsekiz Mart Üniversitesi Tıp Fakültesi, Çanakkale, Türkiye. ORCID: <https://orcid.org/0000-0002-9731-0560><sup>d</sup> Profesör Doktor, Kadın Hastalıkları ve Doğum, Çanakkale Onsekiz Mart Üniversitesi Tıp Fakültesi, Çanakkale, Türkiye. ORCID: <https://orcid.org/0000-0001-6608-9886>

## ARTICLE INFO

Article History:  
Received: 26.09.2022  
Accepted: 17.10.2022Keywords:  
Rat model  
Ulipristal acetate  
Endometriosis  
COX-2  
Ki-67

## ABSTRACT

**Objective:** The effect of Ulipristal Acetate on endometriosis foci created in rats was investigated.**Methods:** The study was conducted with 12-week-old rats weighing approximately 280 grams. After creating an autologous endometriosis model, the group that did not receive ulipristal acetate negative was administered with oral saline daily, and the group given ulipristal acetate positive was administered with 0.5 mg/kg (0.125 mg/rat/day) orally for 4 weeks. Ectopic endometrial tissues were removed for histopathological and immunohistochemical evaluations. Staining was performed with Hematoxylin Eosin, Ki-67, and Cyclooxygenase-2.**Results:** The Hematoxylin-Eosin Staining score of the ectopic endometrium surface epithelium was found to be 2.5 points in the ulipristal acetate negative group, and 0.5 points in the ulipristal acetate positive group. In the immunohistochemical evaluation, Ki-67 positivity of the ectopic endometrial surface epithelium was found to be 71.2% in the ulipristal acetate negative group vs. 31.7% in the ulipristal acetate positive group. Cyclooxygenase-2 positivity was detected as 67% in the ulipristal acetate negative group vs. 27% in the ulipristal acetate positive group.**Conclusions:** Hematoxylin-Eosin staining revealed that ulipristal acetate negative group was 2.5 (well-moderately preserved epithelium), and the ulipristal acetate positive group was 0.5 (epithelium was rarely present or absent). It was found that the percentage of Ki-67 and Cyclooxygenase-2 immunohistochemical positivity was decreased in the ulipristal acetate positive group compared to the ulipristal acetate negative group at a statistically significant level. More literature data are needed on this subject.

## MAKALE BİLGİLERİ

Makale Geçmişi:  
Geliş Tarihi: 26.09.2022  
Kabul Tarihi: 17.10.2022Anahtar Kelimeler:  
Rat model  
Ulipristal asetat  
Endometriozis  
COX-2  
Ki-67

## ÖZET

**Amaç:** Ulipristal Asetat'ın ratlarda oluşturulan endometriozis odakları üzerindeki etkisinin araştırılması hedeflendi.**Gereç ve Yöntem:** Çalışma, yaklaşık 280 gram ağırlığında 12 haftalık ratlarla yürütüldü. Otolog endometriozis modeli oluşturulduktan sonra, ulipristal asetat almayan gruba günlük oral salin, ulipristal asetat verilen gruba ise 4 hafta süreyle 0.5 mg/kg (0.125 mg/rat/gün) oral yolla verildi. Histopatolojik ve immünohistokimyasal değerlendirmeler için ektopik endometriyal dokular çıkarıldı. Boyama Hematoksilen-Eozin, Ki-67 ve Siklooksijenaz-2 ile yapıldı.**Bulgular:** Ektopik endometrium yüzey epitelinin Hematoksilen-Eozin Boyama skoru ulipristal asetat negatif grubunda 2,5 puan, ulipristal asetat pozitif grubunda 0,5 puan olarak bulundu. İmmünohistokimyasal değerlendirmede ektopik endometriyal yüzey epitelinin Ki-67 pozitifliği ulipristal asetat negatif grubunda %71,2, ulipristal asetat pozitif grubunda ise %31,7 olarak bulundu. Siklooksijenaz-2 pozitifliği ulipristal asetat negatif grubunda %67, ulipristal asetat pozitif grubunda ise %27 olarak tespit edildi.**Sonuçlar:** Hematoksilen-Eozin boyaması, ulipristal asetat negatif grubunun 2.5 (iyi-orta derecede korunmuş epitel) ve ulipristal asetat pozitif grubunun 0.5 (epitel nadiren var veya yok) olduğunu ortaya koydu. Ulipristal asetat pozitif grubunda Ki-67 ve Siklooksijenaz-2 immünohistokimyasal pozitiflik yüzdesinin ulipristal asetat negatif grubuna göre istatistiksel olarak anlamlı düzeyde azaldığı bulundu. Bu konuda daha fazla literatür verisine ihtiyaç vardır.

## 1. Introduction

Endometriosis is a benign, chronic, and common gynecological disease defined as the presence of an endometrial gland and stroma outside the endometrium or myometrium (1,2). Endometriosis is an estrogen-dependent chronic inflammatory syndrome mostly affecting the pelvic tissues (2). It is frequently seen in reproductive women. Endometriosis implants are most commonly located on the peritoneum, and may also exist in the ovaries, rectovaginal septum, ureter, and less frequently in the bladder, pericardium, and pleura with an incidence of 6-10% in the reproductive period (1). The true prevalence of endometriosis is not yet known. It is considered to be between 2% and 10% in the population, reaching 50% in infertile women (3). Endometriosis ranks third among the gynecological diseases causing hospitalization in the United States (4). They were discovered by famous pathologist Karl Freiherr Von Rokitansky as the observation of ectopic endometrial tissue (adenomyoma) within the myometrium in 1860 (5). New theories have been proposed since then about the mechanism of formation of endometriosis; however, no single theory has been comprehensive enough to explain all its clinical presentations. Among these theories, there are theories such as retrograde menstruation, stem cell theory, immune system, endocrine, genetic, and environmental factors. With the widespread use of molecular methods in recent years, more detailed information on its etiopathogenesis was obtained and new approaches were proposed for its diagnosis and treatment. Today, it is accepted that multiple factors, which include ectopic endometrial tissue, altered immune system response, unbalanced cell proliferation and apoptosis, abnormal endocrine signaling, and genetic factors, play roles in the pathogenesis of endometriosis, which is a progressive, estrogen-dependent, and inflammatory disease. Nonsteroidal Anti-Inflammatory Drugs (NSAIDs) are used widely in the treatment of endometriosis and are effective in primary dysmenorrhea. Combined Oral Contraceptives (COCs) and progestin are first-line hormonal options. Second-line treatment is Gonadotropin-Releasing Hormone (GnRH) agonists (6). The treatment option must be patient-based and must be edited to the stage of endometriosis, area of involvement, depth, fertility demand, and age of the patient.

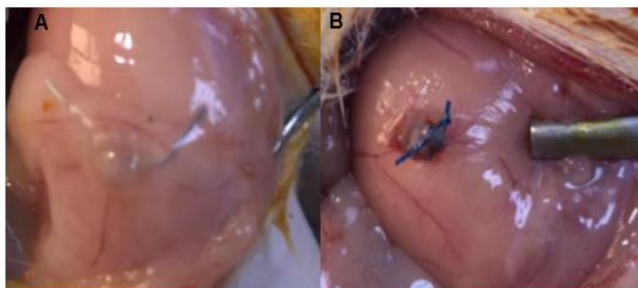
Ulipristal Acetate (UPA) suppresses endometrial prostaglandin production by providing selective inhibition of endometrial proliferation (7). It binds to the progesterone receptor and acts as an antagonist in the presence of progesterone, binding to the progesterone receptor and acting as a progesterone agonist in the absence of progesterone (7,8). Ki-67 protein is associated with cell proliferation. It is a nuclear protein that is essential for the formation of the perichromosomal layer, which is a ribonucleoprotein sheath

covering the condensed chromosomes during mitosis. It is an antigen expressed highly in all active stages of the cell cycle (G1, S, G2, and mitosis) but is down-regulated strongly in the resting phase (G0) cells (9). Cyclooxygenase-2 (COX-2) plays roles in the pathogenesis of endometriosis by increasing angiogenesis. COX-2 is synthesized during inflammation, cell proliferation, and differentiation. It is expressed by Interleukin-1 (IL-1) stimulation in macrophages, fibroblasts, vascular endothelial cells, neurons, and chondrocytes (10). COX-2 plays roles in the pathogenesis of endometriosis by increasing angiogenesis. The increased COX-2 in ectopic tissue was proven to be associated with the progression of endometriosis (10). Prostaglandin E2 (PGE2) is the most potent aromatase enzyme activity stimulator and acts via the prostaglandin estradiol (E2) receptor subtype in the stromal cells of the endometrium (11). Estradiol that is produced in response to increased aromatase activity increases the production of PGE2 by stimulating the COX-2 enzyme in the uterine endothelial cell. The positive feedback contributes to the progression of endometriosis with its estrogenic effect (12). Here, we investigated the effects of UPA on ectopic endometrial tissue formed in rats and compared the percentages of COX-2 and Ki-67 Immunohistochemical (IHC) staining to evaluate cell proliferation of ectopic endometrial tissue in both groups.

## 2. Methods

The experimental procedures were approved by Çanakkale Onsekiz Mart University (ÇOMU) Animal Experiments Local Ethics Committee (Approval number: 2020-E.200008635). All applications were performed in line with the experimental animals' care and use guidelines and the Declaration of Helsinki (13,14). The study was conducted with 24 adult female Wistar albino rats, 12-week old weighing approximately 280 grams. The rats were fed in steel cages in a temperature-controlled ( $22\pm 2$  °C) setting in 12/12-hour light-dark periods with sufficient amounts of feed and water. The study was done in three stages. First stage: All rats were administered with intraperitoneal anesthesia with a mixture of 40 mg/kg ketamine hydrochloride and 2 mg/kg xylazine hydrochloride. After the incision area was shaved, it was stained with 10% povidone-iodine, and a 4 cm vertical abdominal incision was applied to the rats. The left uterine horn was ligated from the uterotubal junction and the lower uterine segment and approximately 1 cm segment was removed. This horn segment was placed in sterile saline solution and the endometrial tissue was completely exposed by making an incision in the antimesenteric axis. Approximately 5x5x1 mm endometrial tissue sections were prepared. Explants were

sutured to the left anterolateral peritoneal surface with 6-0 prolene. Abdominal layers were closed with sterile 4-0 vicryl suitable for anatomy. The incision line on the skin was closed with silver nitrate spray, and the rats were housed in separate cages followed daily for three weeks without any medication for possible complications after surgery. Second stage: To observe the formation of ectopic endometrial tissue, all rats were administered with intraperitoneal anesthesia with a mixture of 40 mg/kg ketamine hydrochloride and 2 mg/kg xsyazine hydrochloride. We waited until there was no response to the painful stimulus. The abdominal cavities were then opened and endometriotic foci were observed. The presence of endometriotic implants was observed in all rats. The abdomen of the rats was covered with a double layer. The incision line was closed with silver nitrate spray. UPA-11 rats were randomized as UPA+ 13 and were placed in separate cages. The UPA- group was administered with 1 ml/kg/day normal saline orally for 28 days, and the UPA+ group was administered with 0.5 mg/kg/day (0.125 mg/rat/day). Oral administration was performed by using a steel gastric gavage cannula. Third stage: All rats were administered with intraperitoneal anesthesia with a mixture of 40 mg/kg ketamine hydrochloride and 2 mg/kg xylazine hydrochloride. We waited until there was no response to painful stimuli. The abdominal cavities were opened with laparotomy, the endometriotic implants were removed completely (Figure 1) and the subjects were then sacrificed.



**Figure 1.** Endometriosis Focus Observed at 3<sup>rd</sup> Laparotomy. A: UPA- Group, B: UPA+ Group

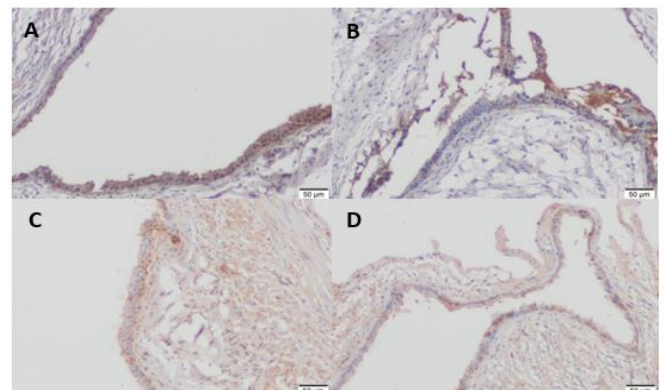
Hematoxylin-Eosin (H&E) evaluation was examined with a light microscope (Zeiss Scope a1) and images were taken. Endometrial gland formation and the presence of stroma were searched in microscopic examination. By using the scoring system developed by Keeanan et al (15). scores were given between 0-3 according to the histopathological features of the endometrial epithelial cells in the implants (3 well-preserved epithelia, 2 moderately preserved epithelia, and leukocyte infiltration, 1 epithelium rarely present, 0 no epithelium). For IHC examination, 4-micron ( $\mu$ ) sections were taken from each of the formalin-fixed-paraffin-embedded blocks on polylysine slides. Ki-67 Rabbit monoclonal antibody and COX-2

were used as the primary antibodies. When the percentage of staining was calculated based on the previous studies (8,16). 4 different areas with the most intense staining were selected, and the mean staining percentage was calculated by counting the stained cells in the area that corresponded to 100 cells in the basal layer.

The analysis was done by using the SPSS version 22.0 software (IBM-SPSS, Chicago, IL). For continuous variables, the descriptive statistics were expressed as mean, standard deviation, minimum, and maximum values, and categorical variables were expressed as numbers and percentages. One-Way Analysis of Variance was performed to compare the group means in terms of continuous variables. The Mann-Whitney Multiple Comparison Test was used to identify different groups following analysis of variance. The Pearson Correlation Coefficients were calculated separately for the groups to determine the relations between variables. In addition, the t-test was used to compare the values of UPA- and UPA+ preparations separately in the groups. In all analyses, P values below 0.05 were considered statistically significant.

### 3. Results

As a result of the H&E staining, it was observed that the endometrial epithelial tissue was preserved in most of the samples in the UPA- group (Figure 1). According to the scoring system, the median values were  $2.5 \pm 0.22$  in the UPA- group,  $0.5 \pm 0.22$  in the UPA+ group, and  $p:0.001$ , respectively. It was found that the UPA+ group had a significantly lower score (Table 1). In the tissues evaluated as a result of Ki-67 staining, it was found that the endometrial epithelial tissue was preserved in most of the samples in the UPA- group, and the samples in the UPA+ group were reduced or completely disappeared (Figure 2).



**Figure 2.** IHC Evaluation Result. A: Ki-67 UPA- Group, B: Ki-67 UPA+ Group, C: COX-2 UPA- Group, D: COX-2 UPA+ Group

Although the percentage of Ki-67 IHC positivity was  $71.2\% \pm 19\%$  in the UPA- group, it was  $31.7\% \pm 31$  and  $p: 0.01$  in the UPA+ group

(Table 1). In the tissues that were evaluated as a result of COX-2 staining, it was found that the endometrial epithelial tissue was preserved in most of the foci in the UPA- group and decreased in the UPA+ group (Figure 2). Although the percentage of COX-2 IHC positivity was  $62 \pm 7\%$  in the UPA- group, it was  $27 \pm 6\%$  and  $p:0.003$  in the UPA+ group (Table 1).

**Table 1.** H&E Staining Score, Percentage of Ki-67, and COX-2 Positivity

	H&E score	Ki-67 (%)	COX-2 (%)
UPA-	2.5± 0.22	71.2% ±19	62% ±7
UPA+	0.5± 0.22	31.7% ±31	27% ±6
<i>P</i> value*	0.001	0.01	0.003

\*Mann-Whitney U test

#### 4. Discussion

Endometriosis is a benign, chronic, and common gynecological disease that is defined as the extrauterine presence of the endometrial gland and stroma. The treatment modalities used for symptomatic patients include medical treatment and surgical excision. Medical treatments that are used today are analgesics, COCs, progestin (oral, depot, or intrauterine), GnRH agonists, and antagonists (17). It is difficult to completely excise endometriotic foci in many patients for the treatment of endometriosis (18). UPA reduces menstrual bleeding and fibroid volume at significant levels (19). Studies on endometriosis are ongoing in the treatment of pelvic pain associated with pelvic pain, and phase IV clinical studies are underway (17). There are studies that use off-label in the treatment of endometriosis.19 When UPA (5 mg daily dose) is administered for three months before the surgery in the treatment of fibroids, it reduced vaginal bleeding and fibroid size, facilitated the operation, and helped patients (20,21). In the present study, it was shown that daily doses of 5mg and 10mg used for 3 months seem safe and effective in bleeding control (22). There are also publications arguing that UPA does not contribute to the treatment of adenomyosis patients increasing the symptoms of the disease. Conway et al. (23). investigated the effects of UPA on adenomyosis retrospectively. They investigated the changes in pain symptoms in patients with adenomyosis who were erroneously diagnosed as myoma uteri and were given 5 mg/day UPA treatment and detected ultrasound images that suggested progression in adenomyosis lesions and worsening of pain symptoms. Drug-induced liver toxicity was rarely detected in patients who used UPA. Today, liver function tests are checked before and after using UPA, even if there is no liver disease (24).

#### 5. Conclusion and Recommendations

Similar to our study, Bax/Bcl-2, cytochrome C, Ki-67, and COX-2 expression were evaluated in the surgically created endometriosis model of UPA in rats compared to the control group.9 Statistically significant differences were detected in all three H&E, Ki-67 IHC positivity percentages, and COX-2 IHC positivity variables in the foci in the surgically created endometriosis model. Although its mechanism of action is not completely clear, it has the potential to be used as a drug for treating endometriosis in the future. Larger group and multicenter studies are needed to demonstrate the effects of UPA on ectopic endometriosis clearly.

**Conflict of Interest:** The authors declare no conflict of interest for this article.

**Financial Support:** The cost of this research is 19.452,95 TL. All financial support was provided by COMU Scientific Research Projects Coordination Unit.

**Ethics Committee Approval:** Animal experiments local ethics committee decision, File number: 2020 – E.200008635, Decision number: 2020/06-01, Date: 03.06.2020.

**Acknowledgments:** ÇOMU Scientific Research Projects Coordination Unit would like to thank for providing the financial support of our study in the scope of the project with the number TTU-2021-3514.

#### Authorship Contribution:

MND: Data collection, statistical analysis, surgical operations.

HOS: Literature review, surgical operations.

NK: Microscopic examination, data collection.

BD: Literature review, critical review, research design.

#### 6. References

- Giudice LC, Kao LC. Endometriosis. *The Lancet*. 2004;364(9447):1789-1799.
- Bulun SE, Yilmaz BD, Sison C, et al. Endometriosis. *Endocrine Reviews*. 2019;40(4):1048-1079.
- Meuleman C, Vandenabeele B, Fieuws S, Spiessens C, Timmerman D, D'Hooghe T. High prevalence of endometriosis in infertile women with normal ovulation and normospermic partners. *Fertility and Sterility*. 2009;92(1):68-74.
- Eskenazi B, Warner ML. Epidemiology of endometriosis. *Obstetrics and Gynecology Clinics of North America*. 1997;24(2):235-258.
- Chaichian S. It is the time to treat endometriosis based on pathophysiology. *Journal of Reproduction & Infertility*. 2019;20(1):1-2.
- Ferrero S, Barra F, Leone Roberti Maggiore U. Current and emerging therapeutics for the management of endometriosis. *Drugs*. 2018;78(10):995-1012.

7. Chwalisz K, Garg R, Brenner RM, Schubert G, Elger W. Selective progesterone receptor modulators (SPRMs): a novel therapeutic concept in endometriosis. *Annals of the New York Academy of Sciences*. 2002;955:373-393,396-406.
8. Huniadi CA, Pop OL, Antal TA, Stamatian F. The effects of ulipristal on Bax/Bcl-2, cytochrome C, Ki-67 and cyclooxygenase-2 expression in a rat model with surgically induced endometriosis. *European Journal of Obstetrics & Gynecology and Reproductive Biology*. 2013;169(2):360-365.
9. Scholzen T, Gerdes J. The Ki-67 protein: from the known and the unknown. *Journal of Cellular Physiology*. 2000;182(3):311-322.
10. Ota H, Igarashi S, Sasaki M, Tanaka T. Distribution of cyclooxygenase-2 in eutopic and ectopic endometrium in endometriosis and adenomyosis. *Human Reproduction*. 2001;16(3):561-566.
11. Noble LS, Takayama K, Zeitoun KM, et al. Prostaglandin E2 stimulates aromatase expression in endometriosis-derived stromal cells. *The Journal of Clinical Endocrinology & Metabolism*. 1997;82(2):600-606.
12. Jarzabek K, Koda M, Walentowicz-Sadlecka M, Grabiec M, Laudanski P, Wolczynski S. Altered expression of ERs, aromatase, and COX2 connected to estrogen action in type 1 endometrial cancer biology. *Tumour Biology: The Journal of the International Society for Oncodevelopmental Biology and Medicine*. 2013;34(6):4007-4016.
13. Özkul T. *Deney Hayvanlarının Kullanımında Genel Mevzuat, Düzenleme ve Kurallar*. Ankara: Derman Medical Publishing; 2006:1-4.
14. Thatte U, Puri K, Suresh K, Gogtay N. Declaration of Helsinki, 2008: Implications for stakeholders in research. *Journal of Postgraduate Medicine*. 2009;55(2):131.
15. Keenan JA, Williams-Boyce PK, Massey PJ, Chen TT, Caudle MR, Bukovsky A. Regression of endometrial explants in a rat model of endometriosis treated with the immune modulators loxoribine and levamisole. *Fertility and Sterility*. 1999;72(1):135-141.
16. Sanketh DS, Kumari K, Rao RS, et al. Expression of Ki-67, p53,  $\alpha$ -SMA and COX-2 in lichen planus and related lesions: A pilot study. *Journal of Oral Biology and Craniofacial Research*. 2019;9(2):230-235.
17. Singh SS, Evans D, McDonald S, Senterman M, Strickland S. Ulipristal acetate prior to surgery for endometriosis. *Reproductive Sciences*. 2020;27:1707-1714.
18. Singh SS, Suen MWH. Surgery for endometriosis: Beyond medical therapies. *Fertility and Sterility*. 2017;107(3):549-554.
19. Wagenfeld A, Saunders PTK, Whitaker L, Critchley HOD. Selective progesterone receptor modulators (SPRMs): Progesterone receptor action, mode of action on the endometrium and treatment options in gynecological therapies. *Expert Opinion on Therapeutic Targets*. 2016;20(9):1045-1054.
20. Rozenberg S, Praet J, Pazzaglia E, Gilles C, Manigart Y, Vandromme J. The use of selective progestin receptor modulators (SPRMs) and more specifically ulipristal acetate in the practice of gynaecology. *The Australian & New Zealand Journal of Obstetrics & Gynaecology*. 2017;57(4):393-399.
21. Dolmans M, Donnez J, Fellah L. Uterine fibroid management: Today and tomorrow. *Journal of Obstetrics and Gynaecology Research*. 2019;45(7):1222-1229.
22. Donnez J, Tatarchuk TF, Bouchard P, et al. Ulipristal acetate versus placebo for fibroid treatment before surgery. *The New England Journal of Medicine*. 2012;366(5):409-420.
23. Conway F, Morosetti G, Camilli S, et al. Ulipristal acetate therapy increases ultrasound features of adenomyosis: A good treatment given in an erroneous diagnosis of uterine fibroids. *Gynecological Endocrinology*. 2019;35(3):207-210.
24. Donnez J, Arriagada P, Marciniak M, Larrey D. Liver safety parameters of ulipristal acetate for the treatment of uterine fibroids: a comprehensive review of the clinical development program. *Expert Opinion on Drug Safety*. 2018;17(12):1225-1232.