

EDİTÖRE MEKTUP / LETTER TO THE EDITOR

An extremely rare presentation of hydatid cyst disease: hepatic artery pseudoaneurysm bleeding and synchronous duodenal fistula

Kist hidatiğin nadir prezantasyonu: hepatic arter psödoanevrizma kanaması ve senkron duodenal fistül

İdris Kurt¹, Nazlıcan Cengiz², Neslican Demir², Ali Rıza Soylu³, Osman Kula⁴

¹Kastamonu Eğitim ve Araştırma Hastanesi, Kastamonu Merkez, Gastroenteroloji, Kastamonu, Turkey

²Trakya Üniversitesi Tıp Fakültesi, Edirne, Turkey

³Trakya Üniversitesi Tıp Fakültesi Hastanesi, Gastroenteroloji, ⁴Girişimsel Radyoloji, Edirne, Turkey

Cukurova Medical Journal 2022;47(4):1776-1779

To the Editor,

Echinococcosis is a zoonosis caused by the adult or larval stages of tapeworms belonging to the genus *Echinococcus*. The main organ involved is the liver¹. The most common complications of liver hydatid cyst are infection and perforation into the biliary tree. The perforation into the gastrointestinal tract is very rare². In this case report, we aim to present a patient with liver hydatid cyst which is perforated into the duodenum and caused an upper gastrointestinal bleeding due to the ruptured hepatic artery pseudoaneurysm.

A 45-year-old male was admitted to the emergency department with hematemesis, hematochezia, and abdominal pain with a history of hydatid cyst disease involving the liver and lungs. Hepatic resection and pericystectomy was planned 8 months ago. However, could not be performed due to COVID-19 pandemic and the patient was still on 400 mg twice daily peroral Andazole therapy.

On physical examination, blood pressure was 122/76 mmHg, heart rate 106 bpm and body temperature was 39°C. Tenderness was examined in the right upper quadrant and the liver was palpable under the costal margin. Laboratory findings were : haemoglobin 12.3 g/dl, leucocytes count 12.2x 10³/uL, platelets count 118x10³/uL, total bilirubin 10 mg/dl, direct bilirubin

5.6 mg/dl, alkaline phosphatase 442 U/L , gama glutamile transferase 367 U/L, alanine aminotransferase:64U/L, aspartate aminotransferase :62 U/L.

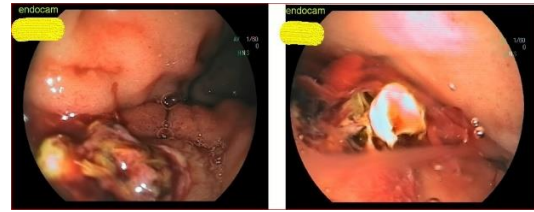

Figure 1. Unusual appearance of ulcer in the duodenum: yellow membranes raising in the middle of ulcer.

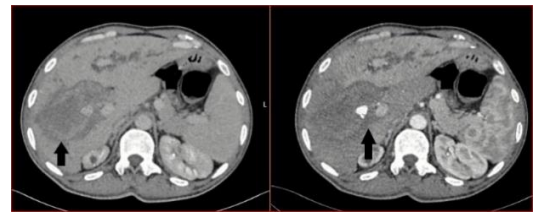


Figure 2. CT images: blood in the cyst in venous phase (left). Hepatic artery pseudoaneurysm in arterial phase (right)

Emergency endoscopy revealed an unusual ulcerated lesion located on the duodenal bulb. Unusual and

Yazışma Adresi/Address for Correspondence: Dr. İdris Kurt, Kastamonu Eğitim ve Araştırma Hastanesi, Kastamonu Merkez, Gastroenteroloji, Kastamonu, Turkey Email: idrisk8607055022@gmail.com
Geliş tarihi/Received: 15.10.2022 Kabul tarihi/Accepted: 05.12.2022

yellow membranes were observed in the middle of the ulcer (Figure 1). Biphasic abdomen CT was performed to verify the source of the bleeding. The CT revealed a hydatid cyst cavity in right liver lobe and hyperechogenic fluid resembling blood, which was oozing from hepatic artery pseudoaneurysm (Figure 2). The borders of cyst and duodenum were not clearly separated and there was not soft tissue between them. A air bubble was identified in the cyst (Figure 3).

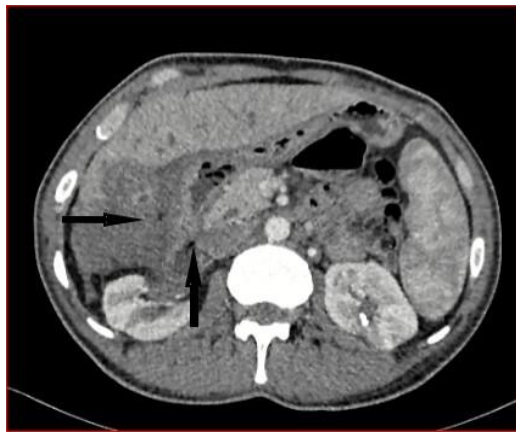


Figure 3. Air bubble in the cyst and suspected duodenal fistula

CT combined with the endoscopic views, hepatic artery pseudoaneurysm bleeding and spontaneous fistulation into the duodenum was diagnosed. Intrahepatic biliary ducts were dilatated due to the pressure of cystic lesion on the common bile duct. Hepatic artery coil embolization was performed by interventional radiology department (Figure 4).

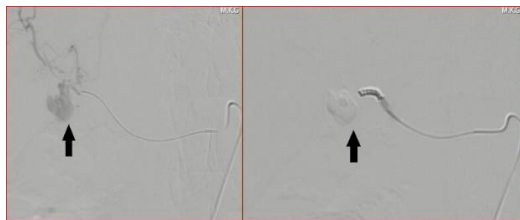


Figure 4. Hepatic artery aneurysm bleeding: before (left) and after (right) coil embolization.

After the coil embolisation of the lesion, Charcot's cholangitis triad was observed. Along with antibiotic therapy an urgent percutaneous transhepatic cholangiography and biliary drainage catheter was performed (Figure 5).

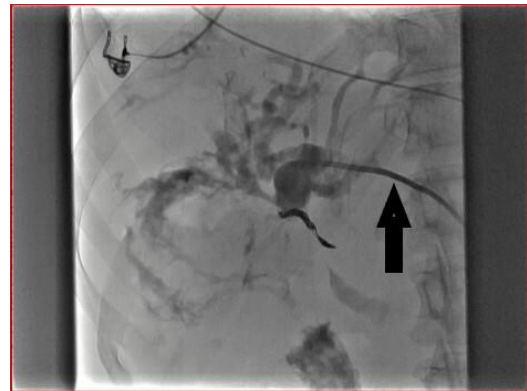

Figure 5. Percutaneous transhepatic cholangiography and biliary drainage catheter placement.

After resolution of the septic condition and intensive care unit follow-up, 10 fr 10 cm plastic stent insertion was performed in common bile duct with ERCP. Bilirubin level normalization was observed in the third day of the procedure. On-set fever occurred while the patient was under broad-spectrum antibiotics administration on the 16th day of hospitalization. On control CT a giant abscess was seen in the upper part of the right liver lobe (Figure 6).

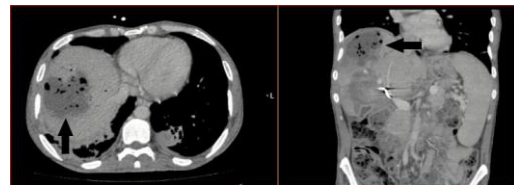


Figure 6. Abscess in the right lobe of the liver

A large percutaneous drainage catheter was inserted into the abscess cavity. The blockage of catheter has occurred due to an abundant amount of solid necrotic materials. Thus, surgical treatment option was considered. Necrotic tissues were removed, cholecystectomy, invasive duodenal repair were performed and temporary jejunostomy tube was placed. After being discharged, the patient is healthy and observed through out patient check-ups.

The liver is the most frequently affected organ by hydatid cyst. The right lobe is involved in 80% and the left lobe in 20% of cases³. Although multiple lesions can be observed (up to 20-40%), the cyst usually tends to be single. Its growth rate is on average 1 to 5 mm per year. It may remain

asymptomatic for years¹. In our patient, the disease was known for 7 years. Liver and lungs were affected. The lesion in the liver was single and localized in the right lobe.

Usually patients become symptomatic when complications occur. Complications are separated under two main categories: rupture and secondary bacterial infection. Ruptures are divided into three subtypes: contained, communicating and direct. The first one represent endocyst rupture, which result with fluid accumulation between the pericyst and endocyst. Then endocyst collapses and forme the typical waterlily sign. The most common type is communication rupture, which connects cyst content with the biliary tract. The least one, direct rupture, is tearing the whole wall's layers and opening the cyst lesion into the peritoneal cavity, thoracic cavity, mediastinum or hollow gastrointestinal organs⁴.

On the endoscopy of our patient a hemorrhagic atypical ulcer with yellow membranes were observed in the duodenum. The CT revealed loss of fatty layers between the cystic lesion and the duodenal wall with air bubble in the cyst. These findings were compatible with rarely seen direct rupture and fistula formation between cystic lesion and duodenum.

In the literature research, cases fistulated into the duodenum, there is only one case presented with hematemesis. The common presentations are nausea, vomiting, fever, right upper quadrant pain, hydatid emesis and hydatid diarrhea. In a single case, melena without additional hematemesis was described^{5,6}. On the other hand the main causes of hematemesis in hydatid cyst disease are hemobilia and esophageal variceal bleeding because of portal vein obstruction^{7,8}. Our patient is unique because of the clinical presentation with hematemesis related to ruptured hepatic artery pseudoaneurism and fistulation into the duodenum synchronously.

In the background of hydatid cyst disease hepatic artery aneurysm can occur. Spontaneous formation of the aneurysm is due to the intracystic inflammation and infection which damages the arterial wall. The treatment of aneurysm can be performed successfully with the endovascular embolization method⁹.

Although hepatic abscess after hepatic artery embolization is a rare entity, it can still occur with incidence rate of 1.4%. The standard treatment method is drainage with percutaneous inserted catheter, but surgical intervention is also required in 14% of the cases¹⁰. In our case, initial approach was

also catheter drainage. But surgery decision was considered after inadequate resolution of the abscess.

Hepatic artery aneurysm and cyst rupture should be considered in patient with liver hydatid cyst disease, presented with upper gastrointestinal bleeding. In order to avoid morbidity and mortality, rapid diagnosis and treatment should be done. Multidisciplinary approach is mandatory to manage such complicated hydatid cystic lesions.

Yazar Katkıları: Çalışma konsepti/Tasarım: İK, NC, ND, ARS, OK; Veri toplama: NC, ND, İK, OK; Veri analizi ve yorumlama: İK, ARS, OK; Yazı taslağı: İK, ND, NC; İçeriğin eleştirilme: İK, ARS; Son onay ve sorumluluk: İK, NC, ND, ARS, OK; Teknik ve malzeme desteği: ARS, OK, İK; Süpervizyon: İK, ARS, OK; Fon sağlama (mevcut ise): yok.

Etik Onay: Bu çalışma için hastadan yazılı bilgilendirilmiş onam alınmıştır.

Hakem Değerlendirmesi: Editoryal değerlendirme.

Çıkar Çatışması: Yazarlar çıkar çatışması beyan etmemişlerdir.

Finansal Destek: Yazarlar finansal destek beyan etmemişlerdir.

Author Contributions: Concept/Design : İK, NC, ND, ARS, OK; Data acquisition: NC, ND, İK, OK; Data analysis and interpretation: İK, ARS, OK; Drafting manuscript: İK, ND, NC; Critical revision of manuscript: İK, ARS; Final approval and accountability: İK, NC, ND, ARS, OK; Technical or material support: ARS, OK, İK; Supervision: İK, ARS, OK; Securing funding (if available): n/a.

Ethical Approval: Written informed consent was obtained from the patient for this study.

Peer-review: Editorial review.

Conflict of Interest: Authors declared no conflict of interest.

Financial Disclosure: Authors declared no financial support

REFERENCES

1. Nunnari G, Pinzone MR, Gruttadauria S, Celesia BM, Madeddu G, Malaguarnera G et al. Hepatic echinococcosis: clinical and therapeutic aspects. *World J Gastroenterol.* 2012;18:1448-58.
2. Saidani A, Saad S, Belhadj A, Rakkeh H, Kammoun M, Chebbi F. Surgical management of a hepatic hydatid cyst fistulized into the duodenum: A case report. *Int J Surg Case Rep.* 2021;88:106518.
3. Beggs I. The radiology of hydatid disease. *AJR Am J Roentgenol.* 1985;145:639-48.
4. Alexiou K, Mitsos S, Fotopoulos A, Karanikas I, Tavernaraki K, Konstantinidis F et al. Complications of Hydatid Cysts of the Liver: Spiral Computed Tomography Findings. *Gastroenterology Res.* 2012;5:139-143.
5. de la Fuente-Aguilar V, Beneitez-Mascaraque P, Bergua-Arroyo S, Fernández-Riesgo M, Camón-García I, Cruza-Aguilera I et al. Hydatidosis and the duodenum: A systematic review of the literature. *World J Metaanal.* 2020;8: 265-74.
6. Gilmas Y, Mocoroa A. Hepatic hydatid cyst perforated into the duodenum and hemorrhagic. *Rev Esp Enferm Apar Dig Nutr.* 1963;22:118-22.
7. Bahreini A, Alavinejad P, Asna Ashari M. A Young Man with Hemobilia Due to a Fistula between

- Hepatic Artery and Biliary Tract. Middle East J Dig Dis. 2020;12:284-87.
8. Ramia JM, De La Plaza R, Kuhnhardt AW, Gonzalez JD, Valenzuela JC, Garcia-Amador C et al. Severe vascular complications due to liver hydatid cyst relapse: a case report and review of the literature. J Surg Surg Res. 2015;1:001-003.
 9. Venkatesh HA, Das C J, Sharma S, Chumber S. Hepatic artery pseudoaneurysm secondary to an infected hydatid cyst and its management. Trop Gastroenterol. 2016;37: 293-5.
 10. Mezhir JJ, Fong Y, Fleischer D, Seo SK, D'Amico F, Petre E et al. Pyogenic abscess after hepatic artery embolization: a rare but potentially lethal complication. J Vasc Interv Radiol. 2011;22:177-82.