

Stubborn Cough; A Rare Symptom Due to Pacemaker Lead Perforation

ORCID iD Mehmet Erat¹, ORCID iD Damla Yalçinkaya¹, ORCID iD Mikail Yarlioğlu¹, ORCID iD Sani Namık Murat¹

¹Department of Cardiology, Ankara Education and Research Hospital, Ankara, Turkey.

Abstract

Cardiac perforation by pacemaker (PM) lead is a rare but potentially life-threatening complication. The clinical presentation is highly variable. Patients may be asymptomatic or present with chest pain, dyspnea or tamponade. In this case, we report a patient with pacemaker implantation who developed a stubborn cough secondary to lead perforation.

Keywords: Cough, lead perforation, pacemaker

Introduction

Cough is a natural defense system of the respiratory tract. It is a common symptom that can be seen in many pathological conditions in addition to respiratory system diseases. It is not always easy to detect the underlying etiology (1).

With the increase in the elderly population all over the world, the incidence of atrioventricular (AV) block is rising (2). In patients with third degree AV block, PM implantation is recommended regardless of symptom status (3). Depending on the procedure and device type, complication rate after cardiac pacing is approximately 5-15%. This rate is even higher in the elderly (2). Cardiac perforation is a rare complication with a rate of 0.3-0.7% (3). Here we report a patient with pacemaker implantation who developed a stubborn cough secondary to lead perforation.

Case Report

A 91-year-old female patient was admitted to the emergency department with stubborn cough and dyspnea. She had a history of hypertension and VVI-R PM (Vitatron SR MRI SureScan™ SSIR, Maastricht, The Netherlands pacemaker and Medtronic CapSureFix Novus MRITM SureScan™ 5076 – 58 cm, Minneapolis, Minnesota, USA ventricular lead; pacing threshold = 0.9 mV, lead impedance = 510 Ω) implantation 1 month earlier due to high-grade

atrioventricular block. Her complaints started approximately after 2 weeks of PM implantation. Physical examination was unremarkable with a pulse rate of 80 bpm, a blood pressure of 125/75 mmHg, an oxygen saturation level of 94%, and a respiratory rate of 26/minute. It was learned that the patient was started on antibiotics by a pulmonologist 1 week earlier, however her cough did not regress. Pneumonia, pneumothorax and pulmonary embolism were excluded in chest computed tomography (CT) imaging. Electrocardiography revealed PM rhythm with a left bundle branch block pattern and intermittent capture failure (arrow) (Figure 1a). On transthoracic echocardiography, the global ejection fraction (EF) was 60% and there was minimal pericardial fluid surrounding the heart. On modified apical 4-chamber view, PM lead protrusion through the right ventricular (RV) apex was observed (arrow) (Figure 1b). The position of the lead was evaluated with chest X-ray (Figure 2a). Although the chest X-ray did not show the lead position accurately, CT showed that the tip of the lead had perforated the RV apically and extended into the pericardium (arrow) (Figure 2b). A complete PM check showed that the pacing threshold of the RV lead had increased to 5 volts/1.0 ms. Initially, open thoracic surgery and epicardial lead placement were planned for the patient, but a conservative approach was decided due to advanced age and high surgical risk of the patient. After 1 week of follow up, the patient was discharged since there was no clinical deterioration or further changes on control echocardiography and CT.

Corresponding Author: Mehmet Erat

e-mail: m.erat42@hotmail.com

Received: 11.10.2022 • **Accepted:** 22.12.2022

DOI: 10.33706/jemcr.1186646

©Copyright 2020 by Emergency Physicians Association of Turkey -

Available online at www.jemcr.com

Cite this article as: Erat M, Yalcinkaya D, Yarlioğlu M, Murat SN. Stubborn cough; a rare symptom due to pace-maker lead perforation. Journal of emergency medicine case reports. 2023;14(1): 10-12

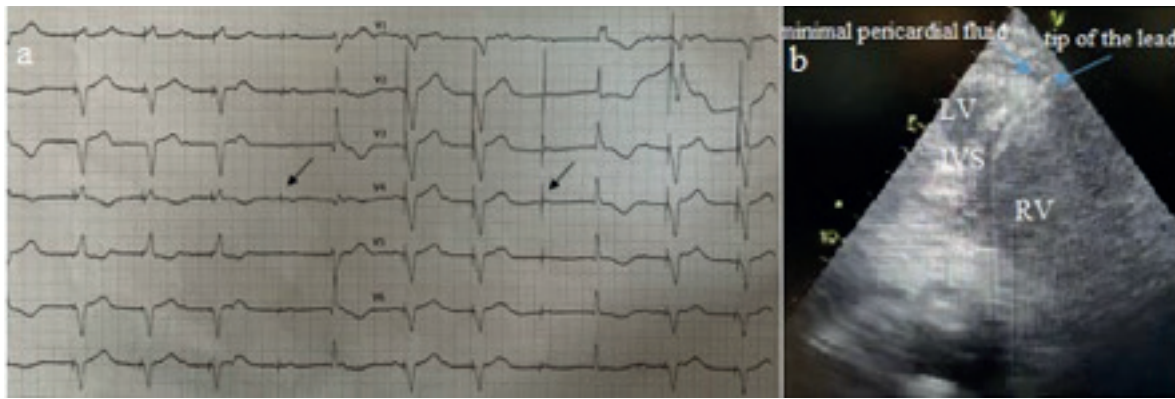


Figure 1. Electrocardiography revealed pacemaker rhythm with a left bundle branch block pattern and intermittent capture failure (arrow) (a), and modified apical 4-chamber view on transthoracic echocardiographic examination showing pacemaker lead protrusion through the right ventricular apex was observed (arrow) and minimal pericardial fluid surrounding the heart (arrow) (b).

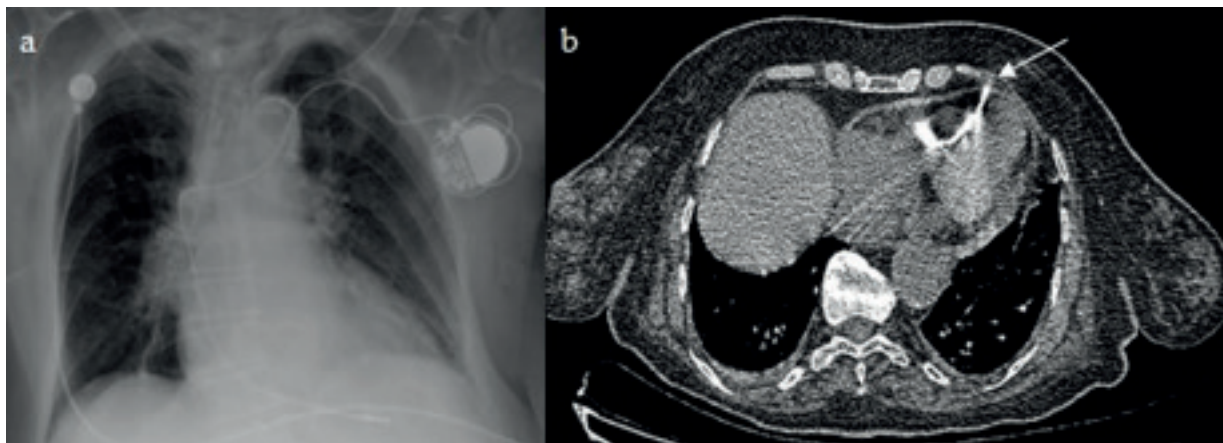


Figure 2. Chest X-ray showing the position of the pacemaker lead (a), and computed tomography showed that the tip of the lead had perforated the right ventricular apically and extended into the pericardium (arrow) (b).

Discussion

In this case, it is demonstrated that permanent PM perforation can cause stubborn cough. Cardiac perforation by PM lead is a rare but potentially life-threatening complication (4). The clinical presentation is highly variable. Patients may be asymptomatic or present with chest pain, dyspnea or tamponade (5,6).

Since cough is a common symptom in respiratory tract diseases, it may not be associated with PM-related complications. In a case report, Steiner S. and friends report a PM lead perforation related chronic cough (7). VVI pacing may be associated with a variety of symptoms called PM syndrome. Cough is an unusual but known symptom of this syndrome (8). Diaphragmatic stimulation is rare but can occur when a misplaced lead stimulates the diaphragm directly or via the phrenic nerve. This can be the first sign of cardiac perforation. The most common complaints of these patients are hiccups, contractions and contraction induced chest pain and shortness of breath (9). Cough usually occurs

as a result of stimulation of sensory nerves in the larynx and tracheobronchial tree by various inflammatory, mechanical, thermal or chemical stimuli. These sensory nerves are also located in organs such as pericardium, esophagus, diaphragm, and stomach (10). We thought that the cough and dyspnea that developed in our patient was due to mechanical irritation of the pericardium and diaphragm.

If we evaluate other conditions that may cause cough; since the left ventricular EF was normal on echocardiography and there was no sign of pulmonary congestion or peripheral edema, the complaints were not considered to be due to heart failure. Diseases affecting the respiratory system such as pneumothorax, pneumonia and pulmonary embolism, which are other causes of cough, were ruled out with thorax CT. The use of angiotensin converting enzyme inhibitors, which is also a frequent cause of cough, was not seen in our patient. Considering the mechanisms discussed above and since the patient did not have symptoms prior to PM implantation, we attributed her symptoms to cardiac perforation.

Conclusion

Although it is rare, PM-related cardiac perforation should be considered in the differential diagnosis of stubborn cough as it can be fatal.

References

1. De Blasio F, Virchow JC, Polverino M, Zanasi A, Behrakis PK, Kiliç G, et al. Cough management: a practical approach. *Cough*. 2011 Oct 10;7(1):7. doi: 10.1186/1745-9974-7-7. PMID: 21985340; PMCID: PMC3205006.
2. Aktürk İF, Erol MK. Bradyarrhythmias and pacemaker indications in elderly patients. *Türk Kardiyol Dern Ars* 2017;45 Suppl 5: 71–74 doi: 10.5543/TKDA.2017.05315
3. Glikson M, Nielsen JC, Kronborg MB, Michowitz Y, Auricchio A, Barbash IM, et al. 2021 ESC Guidelines on cardiac pacing and cardiac resynchronization therapy. *Eur Heart J*. 2021 Sep 14;42(35):3427-3520. doi: 10.1093/eurheartj/ehab364. PMID: 34455430.
4. Mori H, Kato R, Ikeda Y, Tsutsui K, Hasegawa S, Tanaka S, et al. Percutaneous Simple Lead Traction Is a Feasible and Effective Method for Right Ventricular Lead Perforations. *Int Heart J*. 2020 Jan 31;61(1):54-59. doi: 10.1536/ihj.19-326. Epub 2020 Jan 17. PMID: 31956147.
5. Hirschl DA, Jain VR, Spindola-Franco H, Gross JN, Haramati LB. Prevalence and characterization of asymptomatic pacemaker and ICD lead perforation on CT. *Pacing Clin Electrophysiol* 2007; 30: 28-32.
6. Huang XM, Fu HX, Zhong L, Osborn MJ, Asirvatham SJ, Sinak LJ, et al. Outcomes of lead revision for myocardial perforation after cardiac implantable electronic device placement. *J Cardiovasc Electrophysiol*. 2014 Oct;25(10):1119-24. doi: 10.1111/jce.12457. Epub 2014 Jul 7. PMID: 24863054.
7. Steiner S, Schueller PO, Blondin D, Winter J. Husten als seltenes Symptom einer Schrittmacherelektrodenperforation [Cough as a rare symptom of a pacemaker lead perforation]. *Pneumologie*. 2015 Feb;69(2):86-8. German. doi: 10.1055/s-0034-1391263. Epub 2015 Jan 14. PMID: 25588023.
8. Cohen SI, Frank HA. Preservation of active atrial transport: an important clinical consideration in cardiac pacing. *Chest*. 1982;81:51-4.
9. Beatriz F, Jorge T, Ramon AE, Ignacio FL. Pacemaker Lead Displacement: Mechanisms And Management. *Indian Pacing Electrophysiol J*. 2003 October–December; 3: 231–8
10. Erdiç M. Definition, Epidemiology and Basic Pathophysiologic Mechanisms. *Türk Toraks Derg* 2013; 14(Supplement 3): 1-5 DOI: 10.5152/ttd.2013.100