



## Secondary Occipital Infarct Due to Shunt Dysfunction: Case report

1 Department of Neurosurgery, Yuzuncu Yil University, Medical School, Van, Turkey

2 Department of Neurosurgery, Pamukkale University, Medical School, Denizli, Turkey

3 Department of Neurosurgery, Erciş State Hospital, Van, Turkey

4 Department of Neurosurgery, Yüksekova State hospital, Hakkari, Turkey

### ÖZET

Hydrocephalus is a clinical table characterized with the enlargement of ventricles due to progressive accumulation of Cerebrospinal Fluid (CSF) and an increase in intracranial pressure (ICP). Ventriculo-peritoneal shunt is currently the most effective and frequent method used in the treatment of hydrocephaly. Spite to the continuous development monitored in shunt technology, today approximately 70% of the patients with a shunt inserted may face with shunt dysfunction within a ten years period. The current case is a 3 years old patient who was hospitalized and treated due to a shunt dysfunction diagnosis where a secondary occipital infarct and blindness developed against the shunt dysfunction. Shunt-induced complications may develop in hydrocephalus patients. We have presented a rare complication accompanied with the related literature regarding loss of vision relative to shunt dysfunction.

**Keywords:** Hydrocephalus, shunt dysfunction, occipital infarct, visual loss.

### ABSTRACT

**Corresponding Author:** Dr. Ismail Gülşen  
**Adress:** Department of Neurosurgery, Yuzuncu Yil University,  
Medical School, Van, Turkey  
**E-mail:** dr-ismailgulsen@hotmail.com

**Başvuru Tarihi/Received:** 02-12-2015  
**Kabul Tarihi/Accepted:** 31-12-2015



## 1. INTRODUCTION

Hydrocephalus is a clinical table which can develop due to an obstruction of CSF in the circulatory tract or an impaired balance between CSF production and absorption, and is a progressive abnormal buildup of cerebrospinal fluid (CSF) in the ventricles of the brain and increased intracranial pressure and can compress and damage the brain. Treatment of hydrocephalus is surgical. A surgical shunt (ventriculoperitoneal, ventriculoatrial, ventriculopleural or lumboperitoneal) or endoscopic third ventriculostomy can be applied to such patients. Nowadays ventriculoperitoneal shunt is the most present effective and frequent method used in the treatment of hydrocephalus.

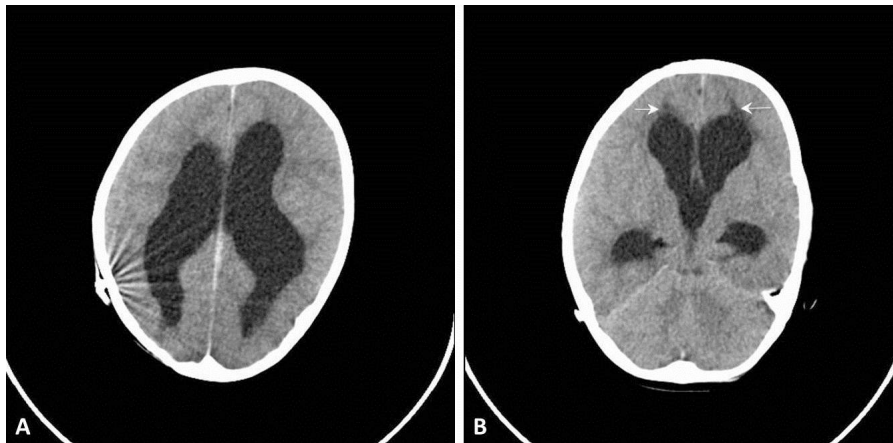
The most frequent cause of dysfunction is ventricular catheter obstruction and infection. Approximately 1/3 of patients with shunt inserted undergo a revision surgery within the first year [1]. After then, 4-5% can be added for per year. This ratio may reach approximately 50% during a 5-years term [2]. Patients who developed shunt dysfunction may display clinical symptoms due to an infection or increased intracranial pressure. Increase in intracranial pressure may lead to various visual impairments [3]. Even though there are very large series related with shunt complications, there are no adequate data related with visual loss complication and therefore, the actual incidence and etiology of visual loss cannot be completely recognized

[3]. Our intention in this article is to present a case with bilateral occipital infarct due to shunt dysfunction which lead to visual loss in a patient.

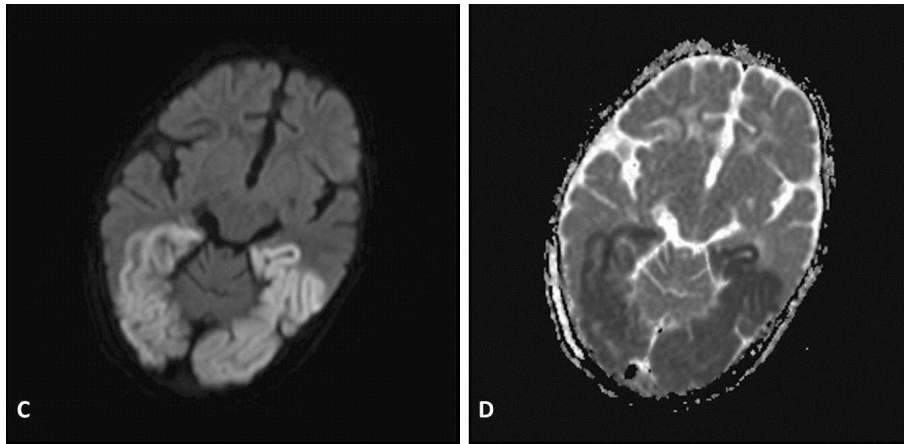
## 2. CASE

A 3 years old boy was referred to the emergency unit due to deterioration of his unconsciousness state which developed 4 hours after complaints such as nausea, and vomiting whereas a ventriculoperitoneal shunt was inserted to the patient because of congenital hydrocephalus reported in his medical background. Preoperative neurological examination of the patient revealed a closed consciousness state, spontaneous respiration and pupillary isochoric IR +/- IIR +. Patient retracted his extremities by painful stimulants. Computerized Tomography (CT) showed wide ventricles and a shunt catheter extended inside the ventricles (Figure 1). Patient was immediately operated due to the diagnosis of shunt dysfunction. The proximal tip of the shunt was found obstructed during the surgery. There was no any signs of infection at CSF. Patient's unconsciousness state opened after the surgery and his complaints such as nausea and vomiting recovered, but examination at the 6<sup>th</sup> postoperative hour showed us that patient had no vision. Brain and diffusion MR images displayed bilateral occipital infarct (Figure 2).

At the postoperative 6 months the patient is capable to see only the light and objects at near sight as shadows.



**Figure 1:** Both two lateral ventricles can be monitored dilated in cranial CT images (A,B) and hydrocephalus is present. Furthermore, more significant in lateral ventricle frontal horn neighborhood's, extravasation areas are noticed (Arrow).



**Figure 2:** Restricted areas compatible with acute infarct at the both two occipital lobes and temporal lobe posteriors can be monitored in diffusion MR images (C,D).

### 3. DISCUSSION

Ventriculoperitoneal shunt dysfunction is considered as a significant neurosurgical disease which may cause important morbidity and mortality rates [4,5,6]. Significant complications after ventriculoperitoneal shunt applications are reported in the literature to occur with a ratio between 6% and 53% [4,5,7]. Shunt complications can include mechanical obstruction of the shunt, infection, seizures, accumulation of extracerebral fluid, subdural hematoma, slit ventricle, acid peritonitis, intestinal perforation and wound site complications [4-9]. The most frequent complications are mechanic obstruction of the shunt and infection. Ventricular tip obstruction is the most frequently encountered reason for mechanic failure and may compose the 2/3 of entire obstructions [9]. In our patient shunt dysfunction developed due to an obstruction at the ventricular tip of the shunt. We observed a rare occipital infarct and visual loss which developed due to an increase in intracranial pressure.

Increase in intracranial pressure may cause a number of various visual impairments. Optic tracts and oculomotor nerves are intensively sensitive to changes in the intracranial pressure and alterations in structures of intracranial sites. Even though no any increase in intracranial pressure was determined by radiological means in such patients, symptoms such as headache, nausea, vomiting, impaired vision and changes

in optic nerve are indicators of increased intracranial pressure. According to the literature, CT of patients who undergone a shunt operation may not reveal any changes in ventricles, however, there are a number of patients with increased secondary intracranial pressure and who developed visual impairment [8,10,11].

The Visually Impaired Program demonstrated that permanent blindness may develop in 1.8% of young children during the period where an increase is determined in secondary intracranial pressure due to shunt dysfunction [10,12]. A search in the literature showed that, Oyama et al [10], Arroyo et al. [12], Cedzich et al. [3], Constantini et al. [13], Lorber J. [14], Shehu et al. [15] and Gimeno-Pita et al. [11] presented cases who developed visual loss due to shunt dysfunction. Among these authors, Arroyo HA and Gimeno-Pita P determined occipital infarct by radiological means in their patients. Nevertheless, other authors mentioned an increase observed in ICP induced by shunt dysfunction or intracranial structures affected by a sudden decrease in pressure that occurred during revision.

There are several hypotheses related with increased ICP and loss of vision due to the development of shunt dysfunction. If a decrease is present in optic atrophy and light reflex, then the lesion is commonly located at the pregeniculate tract (anterior optic tract), otherwise it is located at the postgeniculate tract (cortical blindness)

[3,8,10,12,13]. However, it must be noted that optic atrophy may develop due to trans-synaptic degeneration after posterior lesions. Therefore, it may be not possible to only perform a basic physical evaluation regarding anatomical localization [13].

Based onto a vascular mechanism, anterior optic tract are fed by veins that extend alongside bones. This may cause a circulatory stasis due to a high pressured compression of the arteries and ischemia [3,10,12].

In a study carried out by Arroyo et al., visual loss was determined in the pregeniculate tract in 9 and in the postgeniculate tract in 5 children due to ischemia. CT scans also described unilateral or bilateral infarcts in irrigation fields of the posterior cerebral artery (PSA) [12].

A sudden increase in ICP may cause an infarct in the occipital lobe because it may compress PSA or it's branches throughout the tentorial notches, at any site [3,8,12,13].

According to another hypothesis, sudden changes in intracranial pressure during the treatment of shunt dysfunction may affect optic tracts and lead to visual loss [3,8,10,13].

When a patient who developed a shunt dysfunction is not appropriately and immediately treated, increased intracranial pressure may cause herniations. This condition may lead to sudden loss of consciousness and death. In our patient, we observed a loss of consciousness

that developed shortly after complaints occurred. Patient was immediately hospitalized in immediate terms right after referred to the hospital and undergone a shunt revision. Postoperative examination displayed visual loss while brain and diffusion MR demonstrated infarct in PSA irrigation fields (Figure 2). We assumed that, loss of consciousness cause an increase in intracranial pressure and consequently initiated herniation and occipital infarct developed due to secondary PSA obstruction.

Visual loss due to shunt dysfunction is a rare complication. Therefore, shunt dysfunction must be considered in patients with a ventriculoperitoneal shunt, headache, nausea, vomiting and impaired vision, even though these patients have normal CTs. Associated with increased intracranial pressure, PSA is the first to be affected in these patients and reversible or irreversible impaired vision may develop according to the degree of obstruction, or to the timing of surgical intervention.

Consequently, shunt dysfunction is a neurosurgical immediate state which may lead to visual loss. If left untreated, may cause neurological deficits.

## CONFLICTS OF INTERESTS

None of the authors get fund from anywhere and they have no other conflicts of interest.

## REFERENCES

1. S. S. Shah, M. Hall, A. D. Slonim, G. W. Hornig et al., "A multicenter study of factors influencing cerebrospinal fluid shunt survival in infants and children," *Neurosurgery*, vol. 62, pp. 1095-1103, 2008.
2. M. J. McGritt, A. Zaas, H. E. Fuchs et al., "Risk factors for pediatric ventriculoperitoneal shunt infection and predictors of infectious pathogens," *Clin. Infect. Dis*, vol. 36, pp. 858-862, 2003.
3. C. Cedzich, J. Schramm, D. Wenzel, "Reversible visual loss after shunt malfunction," *Acta Neurochir (Wien)*, vol. 105, pp.121-3, 1990.
4. F. Khan, M. S. Shamim, A. Rehman et al., "Analysis of factors affecting ventriculoperitoneal shunt survival in pediatric patients," *Childs Nerv Syst*, vol. 29, pp. 791-802, 2013
5. G. K. Reddy, P. Bollam, G. Caldito, "Long-term outcomes of ventriculoperitoneal shunt surgery in patients with hydrocephalus," *World Neurosurg*, vol. 81, pp. 404-10, 2014.
6. M. Vinchon, H. Rekate, A. V. Kulkarni, "Pediatric hydrocephalus outcomes: a review," *Fluids Barriers CNS*, vol. 9, pp.18, 2012.
7. F. Nigim, J. F. Critchlow, B. E. Schneider et al., "Shunting for hydrocephalus: analysis of techniques and failure patterns," *J Surg Res*, vol. 191, pp. 140-7, 2014.
8. M. Sunil, C. Payne, M. Panda, "Transient binocular visual loss: a rare presentation of ventriculoperitoneal shunt malfunction," *BMJ Case Rep*, doi: 10.1136/bcr.10.2011.4929, 2011.

9. J. M. Drake, C. Sainte-Rose, "Shunt Complications. In: Shunt Book. Drake JM, Sainte- Rose(ed), Blackwell Scientific Publications Ltd: New York," 1995.
10. H. Oyama, K. Hattori, A Kito et al. "Visual disturbance following Shunt malfunction in patient with congenital hydrocephalus," *Neurol Med Chir*, vol. 52, pp.835-8, 2012.
11. P. Gimeno-Pita, M. Moros-Peña, T. Guillén-Ballard et al., "Permanent visual loss resulting from bilateral occipital infarction after shunt malfunction," *Rev Neurol*, vol. 32, pp. 835-7, 2001.
12. H. A. Arroyo, J.E. Jan, A. Q. McCormick et al., "Permanent visual loss after shunt malfunction," *Neurology*, vol. 35, pp.25-9, 1985.
13. S. Constantini, F. Umansky, R. Neshet et al., "Transient blindness following intracranial pressure changes in a hydrocephalic child with a V-P shunt," *Childs Nerv Syst*, vol. 3, pp.379-81, 1987.
14. J. Lorber, "Recovery of vision following prolonged blindness in children with hydrocephalus or following pyogenic meningitis," *Clin Pediatr (Phila)*, vol. 6, pp. 699-703, 1967.
15. B. B. Shehu, K. Tunau K, "Blindness following ventriculo-peritoneal shunt block in a child with spinal dysraphism: case report," *East Afr Med J*, vol. 82, pp.106-7, 2005.