

Effect of Combination of Hypericum Perforatum, Calendula Officinalis and Aloe Vera Plant Extracts on Incisional Wound Healing

Hypericum Perforatum, Calendula Officinalis ve Aloe Vera Bitki Ekstraktlarının Kombinasyonunun İnsizyonel Yara İyileşmesine Etkisi

Sultan KAYA¹, Şevkinaz DOĞAN²

¹Burdur Public Education Center, Burdur, Türkiye

²Burdur Mehmet Akf Ersoy University, Faculty of Health Sciences, Department of Fundamentals of Nursing, Burdur, Türkiye

Abstract: Today, patients and health professionals are turning to innovative approaches due to the lack of success in treating chronic wounds. This study aimed to investigate the effect of a mixture of *Hypericum Perforatum* histopathologically, *Calendula Officinalis*, and *Aloe Vera* plant extracts on incisional wound healing. A total of 14 rats, 7 rats, were used in each group. The groups were divided into experimental and control. While daily wound care was performed with an herbal extract mixture in the experimental group, sterile saline was used for daily wound care in the control group. During the study, wound surface area measurement, macroscopic evaluation, and histopathological examination were performed in both groups. According to research findings, the control group's wound-healing process is shorter. Histopathological analyses revealed that wound healing was completed on day 21.

Keywords: *Aloe Vera, Calendula Officinalis, Hypericum Perforatum, Incisional wound, Wound healing.*

Öz: Günümüzde hastalar ve sağlık profesyonelleri, kronik yaraların bakım ve tedavisinde başarı sağlanamaması nedeniyle yenilikçi yaklaşımlara yönelmektedir. Bu çalışmada, *Hypericum perforatum, Calendula officinalis ve Aloe vera* bitki ekstraktlarının bir karışımının insizyonel yara iyileşmesi üzerine etkisinin histopatolojik olarak incelenmesi amaçlanmıştır. Çalışmada her grupta 7 sıçan olmak üzere toplam 14 sıçan kullanılmıştır. Gruplar deneysel ve kontrol olarak ikiye ayrıldı. Deney grubunda bitkisel ekstre karışımı ile günlük yara bakımı yapılırken, kontrol grubunda günlük yara bakımı için steril salin kullanılmıştır. Çalışma süresince her iki grupta da yara yüzey alanı ölçümü, makroskopik değerlendirme ve histopatolojik inceleme yapıldı. Araştırma bulgularına göre kontrol grubunda yara iyileşme süreci daha kısadır. Histopatolojik incelemelerde yara iyileşmesinin 21. günde tamamlandığı gözlemlendi.

Anahtar Kelimeler: *Aloe vera, Calendula officinalis, Hypericum perforatum, İnsizyonel yara, Yara iyileşmesi.*

*Corresponding author : Şevkinaz DOĞAN

e-mail : skonak@mehmetakif.edu.tr

Geliş tarihi / Received : 27.10.2022

Kabul tarihi / Accepted: 14.12.2022

Introduction

Chronic wounds are an important cause of mortality and morbidity. The long duration of wound healing in chronic wounds causes prolonged hospitalization, increased care costs and workload. In addition to these problems, the prolongation of the healing process negatively affects the quality of life of the individual, causing physical and psychosocial trauma, leading to the inability of the individual to fulfill his responsibilities and an increase in care

expenditures economically (Özkorkmaz et al., 2009; Kısacık, 2015). Herbal therapy has gained popularity around the world in recent years. The World Health Organization (WHO) reports that approximately 60% of the world population and 60-90% of developing countries turn to treatment with medicinal plants (Sançar et al., 2017). The rich content of herbal medicines, their effect on many regions, their cheapness, low level of side effects and easy availability make them used by large masses. Medicinal plants that affect various stages

of wound healing such as coagulation, inflammation, collagen production and epithelial formation take their place in the scientific literature (Sançar et al., 2017). The effects of the extracts of these plants on wound healing can be listed as antibacterial, collagen synthesis enhancer, proliferation-fibroblast stimulating, antimicrobial and antioxidant (Sançar et al., 2017). *Hypericum perforatum* has been used in wound treatment for centuries and is known to have important effects, especially in incisional wounds (Prisacaru et al., 2013; Altan et al., 2015). It is reported that *H. perforatum* extracts increase collagen production, fibroblast migration, keratinocyte differentiation and epithelialization, as well as antimicrobial and antibacterial effects (Sançar et al., 2017). *Calendula officinalis* is used in wound healing as an anti-inflammatory agent (Erçetin et al., 2012; Parente et al., 2012; Nicolaus et al., 2017). It is seen that the hexane and ethanolic extract of *C. officinalis* stimulates the proliferation and migration of fibroblasts, accelerates re-epithelialization, increases cell proliferation, and the amount of collagen and noncollagen proteins (Budovsky et al., 2015). Another plant used in wound treatment is *Aloe vera*. *Aloe vera* is a medicinal plant with high efficacy in the treatment of skin wounds. Both *Aloe vera* gel and *Aloe vera* extract have been reported to promote wound healing in in vitro and in vivo studies. It contains many active ingredients for wound healing, including polysaccharide, aloin, emodin, rhein, aloesin and vitamins. The antibacterial, anti-inflammatory, anti-oxidant and immunomodulatory properties of these compositions have positive effects on skin wound healing. Aloe polysaccharide and anthraquinone, aloin, rhein and emodin components, which are found in large amounts in aloe vera, perform wound healing with their anti-inflammatory, antibacterial, angiogenic and immunomodulatory effects (Attah et al., 2016; Sa et al., 2016; Liang et al., 2020). This study was carried out to examine the effectiveness of combinations of *H. perforatum*, *C. officinalis* and *Aloe vera* plant extracts (HCA) on incisional wound healing and to make a scientific contribution to the literature.

H₁ hypothesis: The use of a mixture of *Hypericum perforatum*, *Calendula officinalis* and *Aloe vera* plant extract in the treatment of incisional wounds shortens the healing process.

Materials and Methods

The ethics committee approval of the study was obtained by Burdur Mehmet Akif Ersoy University Animal Experiments Local Ethics Committee with the decision numbered 512 on 15.05.2019. In the study, Wistar breed, average weight 250-350 gr. 14 male rats, ranging in age from 8-12 weeks old, were used. Rats were divided into experimental and control groups by simple randomization method. After incisional wounds were created, all rats were housed in separate cages for 12 hours during the day and 12 hours at night, under constant temperature (17-20°C environment) and humidity under laboratory conditions. During the experiment, rats were fed with tap water and standard chow. Extracts of *Hypericum perforatum* and *Calendula officinalis* plants were obtained by classical maceration method. *Aloe vera* plant was obtained as a gel. Extracts from these plants were mixed in equal proportions. Anesthesia, dorsal hair shaving and cleaning with 70% isopropanol and surgical field staining with betadine were performed on each rat. Then, wounds were created by making 3 cm incisional incisions with a scalpel in the dorsal region of the rats. The dressing of both groups was performed once a day for 21 days, at the same time every day, assuming 0 on the day the wound was formed (no dressing was applied on the day 0). The mixture obtained from HCA plant extracts was applied to the experimental group in a 0.5 cc amount of injector to completely cover the wound area. After the dressing application, the wound area was covered with sterile sponge and fixed with an adhesive bandage dressing. On the other hand, 1 cc sterile Serum Physiological was applied to the rats in the control group, and the wound area was closed and fixed with sterile sponge. Healing of incisional wounds was evaluated at two levels, macroscopically and microscopically. In order to calculate the wound healing percentages in

macroscopic examination, first of all, photographs of the wounds on the 7th, 14th and 21st days were taken and the wound surface areas and healing percentages were calculated using a computer program. In microscopic examination, excisional biopsy was performed for histological examination of tissue fragments, each containing the wound edge and surface, on days 7, 14, and 21, after wounds were created. On the 7th and 14th days after the biopsy procedure, the area from which

the biopsy was taken was sutured. On the 21st day, after the anesthesia phase, wound evaluations were made and the rats were sacrificed using the cervical dislocation method. The data obtained in the research were analyzed using the SPSS (Statistical Package for Social Sciences) for Windows 25.0 program. When examining the difference between groups; $p < 0.05$ interpreted as statistically significant.

Table 1. Wound area reduction over time in groups (%)

Time	Group	n	Mean	Standard deviation
Wound area percentage 0. day	Control	7	100.00	0.00
	Experiment	7	100.00	0.00
Wound area percentage 7. day	Control	7	84.15	10.86
	Experiment	7	85.58	9.51
Wound area percentage 14. day	Control	7	24.05	7.90
	Experiment	7	36.29	15.21
Wound area percentage 21. day	Control	7	7.13	5.53
	Experiment	7	9.00	4.56

Table 2. Gruplarda yara alanlarının zamana göre değişimi (%)

Time	Control			Experiment			z value	P value
	Med	Min.	Mak.	Med	Min.	Mak.		
Wound area percentage 0. day	100.0	100.0	100.0	100.0	100.0	100.0	-0.192	0.848
Wound area percentage 7. day	86.36	62.10	95.65	87.36	67.39	95.55	-1.597	0.110
Wound area percentage 14. day	24.46	11.57	36.95	33.33	18.88	62.53	-1.023	0.306
Wound area percentage 21. day	5.26	2.32	17.39	8.42	3.26	15.38	-1.023	0.306
Test value	21.000			21.000				
p value	0.000			0.000				

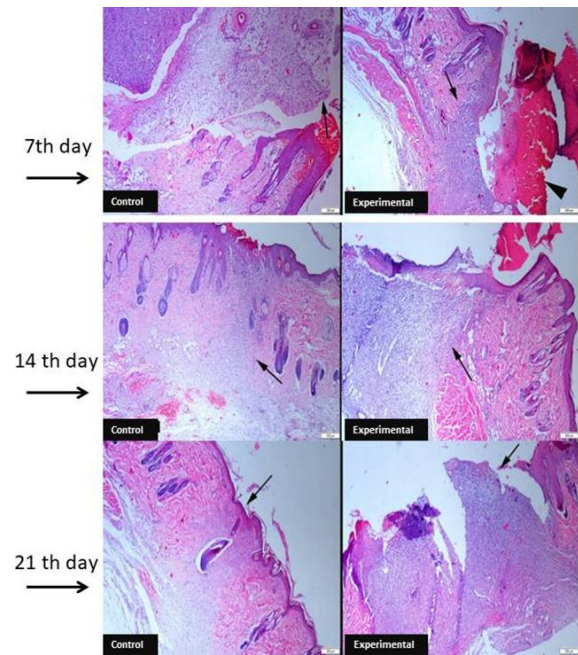
Results

Macroscopic and Wound Surface Findings

On the 4th day of wound healing, it was observed that wound crusting was completed in both study groups. Wound healing progressed more slowly in the experimental group rats for 21 days, and infection findings were observed in the experimental group. It was observed that there was a statistically significant difference in wound area shrinkage of the experimental and control groups according to time ($p < 0.05$) (Table 1). In the multiple comparison test performed to find out which group the difference originated from, the wound area shrinkage on Day 0 was greater than on the 14th and 7th days; It was determined that the wound area shrinkage on the 21st day was smaller than the 7th day. It was determined that there was no statistically significant difference between the groups on all days ($p > 0.05$) (Table 2).

Microscopic and Histopathological Findings

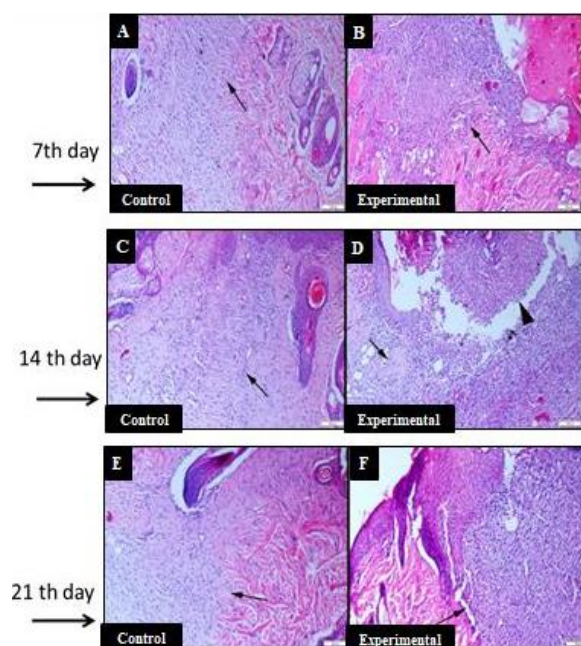
In the histopathological examination of biopsies taken on the 7th day of wound healing; In the control group, it was determined that the connective tissue formation progressed significantly and the healing of the epithelial layer began. In the experimental group, it was observed that the connective tissue was not fully formed, a necrotic crust layer and a severe inflammatory reaction were observed on the epithelial layer. In the histopathological examination of the 14th day of wound healing, it was observed that the healing was better shaped in the control group and that in addition to the healing in the connective tissue, the healing occurred in the epithelial tissue. It was observed that healing progressed in the connective tissue and epithelium in the experimental group, but the inflammatory reaction still continued. Recovery was delayed in the experimental group compared to the control group. In the histopathological examination of the 21st day of wound healing, it was observed that the healing was completed in the control group.



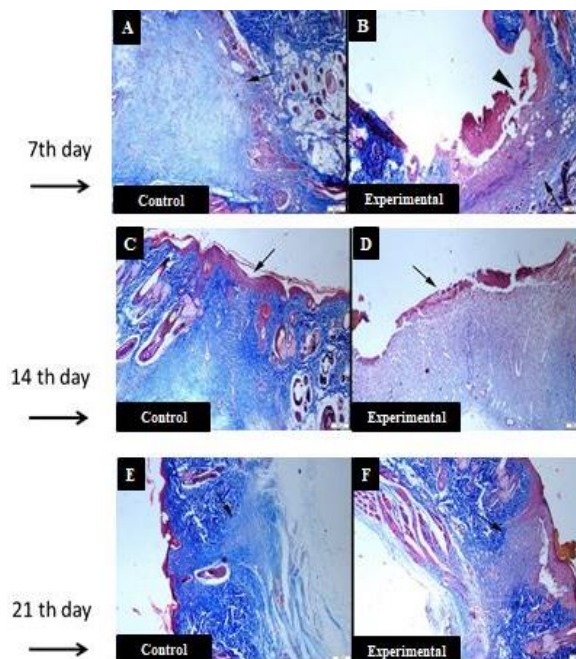
Picture 1: Wound healing on days 7, 14 and 21. Histopathological appearance of skin biopsies on days A: Extensive connective tissue development in the control group (arrow), B: Slight connective tissue formation (arrow) and extensive necrotic crustal mass (arrowhead) in the experimental group, C: Connective tissue development in the control group is about to be completed (arrow), D: Experimental In the group, it was observed that the inflammatory reaction remained prominent especially in the connective tissue (arrow). While the healing of the epithelium was about to be completed in the control group, very slight improvement was observed in the experimental group, E: Significant improvement in the epithelium and connective tissue in the control group, the epithelial layer was completely regenerated (arrow), F: Diffuse inflammatory reaction in the epithelium and connective tissue in the experimental group and delayed healing (arrow), HE, Bar= 200 μ m.

In the experimental group, it was determined that widespread inflammatory reaction and loss of epithelial layer continued, and chronic granulation tissue became evident. Pictures 1 and 2 show the histopathological appearance of wound biopsies taken on days 7-14 and 21 of wound healing. In Masson trichrome staining performed for connective tissue development, it was observed that the connective tissue healing in the control group was shaped more clearly than in the experimental group in all weeks. In the control

group, it was observed that the connective tissue development took shape from the 7th day of wound healing. In the biopsies taken on the 14th day of wound healing, the improvement in the control group was observed. On the 21st day of wound healing, complete connective tissue healing was observed in the control group, while a decrease in connective tissue and collagen formation was observed in the experimental group (Picture 3).



Picture 2: Wound healing on days 7, 14 and 21. Magnified view of skin biopsies on days. A: Connective tissue formation in the control group, B: Connective tissue formation in the experimental group (arrows), C: Connective tissue formation in the control group (arrow), D: Inflammatory reaction in the experimental group (arrowhead), E: Completely healed incision area in the control group (arrow), F: Chronic granulation tissue formation in the connective tissue in the experimental group (arrow), HE, Bar= 100µm.



Picture 3: Wound healing on days 7, 14 and 21. Connective tissue formation. A: Significant connective arrow formation in the control group, B: mild connective tissue formation (arrows) in the experimental group, ulcer formation in the experimental group (arrowhead), C: Connective tissue development and epithelial regeneration (arrow), characterized by significant blue coloration in the control group, D: Delay in healing of both connective tissue and epithelium (arrow) in the experimental group, E: Connective tissue formation in the control group (arrow) F: Connective tissue formation in the experimental group (arrow), Masson Trichrome method, Bar= 200µm.

Discussion

Measuring and recording the changes in the wound surface area is an objective evidence in determining the wound healing status. Considering the wound area percentages, the smallest wound area compared to the initial wound area belongs to the control group with 86.36%. A more effective wound area reduction was observed in all three measurements of the control group compared to the experimental group. As a result, it was observed that the HCA herbal mixture was not effective at the macroscopic level on wound healing. In the study of Nayak et al. (2017), in which they examined the effect of *H.*

perforatum on wound healing, a better healing was observed in the *H. perforatum* application group, unlike our study. In another study, in which herbal extracts were examined, a mixture of *Musa paradisiaca colla* and *Aloe vera* extract in different proportions was used, as a result, it was observed that using them separately or together in incision wounds affected wound healing equally. (Hashemi et al., 2015; Oryan et al., 2016; Kundarto et al., 2020). There is a lot of evidence that *H. perforatum* and *Aloe vera* have a positive effect on wound contraction and epithelialization, and even capillary formation is positively affected (Altıparmak et al., 2019; Teplicki et al., 2018; Koga et al., 2020). In addition, it is stated that *C. officinalis* effectively heals wounds and can be used in the treatment of superficial wounds (Rahman et al., 2020). On the 7th day of our study, the epithelial layer of the control group started to heal. In the experimental group, a necrotic crust layer and a severe inflammatory reaction were detected on the epithelial layer. In the following days, better regeneration was seen in the control group. In the experimental group, the progression was impaired and epithelial layer loss and chronic granulation were detected. It was concluded that the plant mixture used did not affect the epithelialization development much. Collagens in the wound area provide the formation of collagen fibrils, which are an important part of the connective tissue matrix. At the end of this study, it was observed that the connective tissue and collagen formation in the control group was better than the experimental group. However, in a study examining the effect of *Plantago major* and *Aloe vera* on wound healing together, it was observed that *Aloe vera* gave better results in terms of epithelialization, collagen production and neovascularization (Ashkani-Esfahani et al., 2019). Ali et al. (2021) reported that *Aloe Vera* gel increases histopathologically epithelialization, collagenase and angiogenesis. Gunesakan et al. (2020) proved that *C. officinalis* is a wound healing agent by increasing growth factors, collagen and contraction in excisional wounds. The results of these studies do not support our study. Hidayat et al. (2021) reported that ozonated *Aloe vera* oil

increases the number of fibroblasts, macrophages and endothelial cells, accelerates the wound healing process, and increases epithelialization and collagenization in full-thickness cutaneous wounds. It has also been reported that the spray form of *Aloe vera* gel has high healing activity in acute wounds (Sikumbang et al., 2020). In one study, wound healing was observed using aloe vera-containing alginate, and an increase in anti-inflammatory activity, collagen production and angiogenesis was observed (Koga et al., 2020). On the contrary, in our study, the inflammatory reaction was observed continuously, the healing time was prolonged and the collagenization decreased in the experimental group using herbal extract.

Conclusion

Wound and wound healing is one of the quality indicators in the health care system. Nowadays, despite all medical and alternative treatment approaches, wound care and treatment is an important health problem. Healing in chronic wounds can be prolonged with the effect of various factors. Therefore, new approaches to wound treatment are needed. In this study, it was determined that wound healing resulted negatively due to many factors, and healing stages such as connective tissue formation, tissue regeneration, and collagen synthesis could not be fully realized according to the content of the dressing material used in wound care. In the literature, it is reported that single or double combinations of medicinal plants used in our study accelerate wound healing, accelerate collagen synthesis and epithelialization, and stimulate proliferation. However, the herbal mixture used in this study prolongs the wound healing period, reduces collagen synthesis, and causes a widespread inflammatory reaction. Therefore, it was concluded that this mixture should not be used in wound healing. As a result, we think that this mixture should be supported by more comprehensive studies and its effect on all phases of wound healing should be examined separately.

Acknowledgments

This work was supported by Burdur Mehmet Akif Ersoy University Research Fund under Grant (BAP-Project No: 593-YL-19).

Conflicts of interest

There are no conflicts of interest to declare.

References

Ali, F., Wajid, N., Sarwar, MG., Qazi, AM., 2021. Oral aloe vera uygulaması, sprague dawley farelerinde iyileştirilmiş anjiyogenez ve kemotaksis yoluyla yara iyileşmesini iyileştirir. *Curr Ecz. Biyoteknoloji*. 2021; 22(8): 1122-8. DOI: 10.2174/1389201021999201001204345.

Altan, A., Damlar, İ., Aras, M.H., Alparslan, C., 2015. Sarı kantaronun (*hypericum perforatum*) yara iyileşmesi üzerine etkisi. *Çukurova Üniversitesi Arşiv Kaynak Tarama Dergisi*, 24(4), 578-591.

Altıparmak, M., Kule, M., Öztürk, Y., Çelik, SY., Öztürk, M., Duru, ME ve Koçer, U., 2019. *Hypericum perforatum*, *Liquidambar orientalis* ve propolis karışımlarının cilt yaralarını iyileştirme özellikleri. *Avrupa Plastik Cerrahi Dergisi*, 42(5), 489-494 <https://doi.org/10.1007/s00238-019-01538-6>

Ashkani-Esfahani, S., Khoshneviszadeh, M., Noorafshan, A., Miri, R., Rafiee, S., Hemyari, K., Kardeh, S., Hosseinabadi, O.K., Fani1, D., Faridi, E., 2019. The healing effect of plantago major and aloe vera mixture in excisional full thickness skin wounds: Stereological Study. *World J Surg.*, 8(1), 51.

Attah, M.O., Jacks, T.W., Jacob, A., Eduitem, O., John, B., 2016. The effect of aloe vera (linn) on cutaneous wound healing and wound contraction rate in adult rabbits. *NJMBS.*, 5(3).

Budovsky, A., Yarmolinsky, L., Ben-Shabat, S., 2015. Effect of medicinal plants on wound healing. *Wound Repair Regen.*, 23(2), 171-183.

Erçetin, T., Şenol, F., Orhan, I., Toker, G., 2012. Comparative assessment of antioxidant and cholinesterase inhibitory properties of the marigold extracts from *Calendula arvensis* L. and *Calendula officinalis* L. *Ind Crops Prod.*, 36(1), 203–208.

Gunasekaran, S., Nayagam, A.A.J., Natarajan, R., 2020. Wound healing potentials of herbal ointment containing *Calendula officinalis* Linn. on the alteration of immunological markers and biochemical parameters in excision wounded animals. *Clin. Phytoscience*, 6(1), 1-8.

Hashemi, S.A., Madani, S.A., Abediankenari, S., 2015. The review on properties of aloe vera in healing of cutaneous wounds. *Biomed Res. Int.*, 1-6.

Kısacık, G.Ö., 2015. İskemik yaraların iyileşmesinde kudret narı ekstraktı ile yapılan pansumanın, saf zeytinyağı, nitrofurazon ve serum fizyolojik kullanılarak yapılan pansumanlara göre etkinliğinin incelenmesi. Doktora Tezi, Hemşirelik Esasları Anabilim Dalı Programı, Ege Üniversitesi Sağlık Bilimleri Enstitüsü, İzmir.

Koga, A.Y., Felix, J.C., Silvestre, R.G.M., Lipinski, L.C., Carletto, B., Kawahara, F.A., Pereira, A.V., 2020. Evaluation of wound healing effect of alginate film containing Aloe vera gel and cross-linked with zinc chloride. *Acta Cir. Bras.*, 35(5), e202000507.

Kundarto, W., Pangesti, K.A.Y., Shabrina, F., Sasongko, H., 2020. Wound healing activity of skin incision and skin burn from spray gel formula contains combination of banana stem (*Musa acuminata* Colla) and Aloe vera ethanol extracts on mice. *In IOP Conf. Ser.: Mater. Sci. Eng.*, 858(1), 012027.

Nayak, S.B., Işık, K., Marshall, J.R., 2017. Wound-healing potential of oil of *Hypericum perforatum* in excision wounds of male Sprague Dawley rats. *Adv Wound Care.*, 6(12), 401-406.

Oryan, A., Mohammadalipour, A., Moshiri, A., Tabandeh, M.R., 2016. Topical application of aloe vera accelerated wound healing, modeling, and remodeling: an experimental study. *Ann. Plast. Surg.*, 77(1), 37-46.

Özkorkmaz, E.G., Özay, Y., 2009. Yara iyileşmesi ve yara iyileşmesinde kullanılan bazı bitkiler. *Türk J Med Sci.*, 2(2), 63-67.

Parenthe LM, Lino Júnior Rde S, Tresvenzol LM, Vinaud MC, de Paula JR, Paulo NM., 2012. Wound healing and anti-inflammatory effect in animal models of *Calendula officinalis* L. growing in Brazil. *Evid Based Complement Alternat Med.*, 375671: 1– 10.

Prisacaru, A.I., Andritoiu, C.V., Andriescu, C., Havarneanu, E.C., Popa, M., Motoc, A.G.M., Sava, A., 2013. Evaluation of the wound-healing effect of a novel *hypericum perforatum* ointment in skin injury. *Rom J Morphol Embryo.*, 54(4), 1053-1059.

Rahman, M.T., Hasan, M., Hossain, M.T., Islam, M.S., Rahman, M.A., Alam, M.R., Juyena, N.S., 2020. Differential efficacies of marigold leaves and turmeric paste on the healing of the incised wound in sheep. *J. Adv. Vet. Anim. Res.*, 7(4), 750-757.

Sa, S., Dhiman, A., Nanda, S., 2016. Traditional Indian medicinal plants with potential wound healing activity: a review. *Int. J. Pharm. Sci. Res.*, 7(5), 1809-1819.

Sançar, B., Canbulat, Ş., İlhan, S.E., 2017. Yara bakımında kullanılan bitkisel yöntemler ve hemşirelik. *Türkiye Klinikleri J Intern Med Nurs-Special Topics.*, 3(2), 116-124.

Sikumbang, IM., Astuti, RA., Wahyuningtyas, ES., Lutfiyati, H., Wijayatri, R., & Nasruddin, N., 2020. Erkek balb/c farelerinde akut yarada aloe vera özü

spreyinin yara iyileştirme etkinliği. *Pharmaciana*, 10(3), 315.

Teplicki, E., Ma, Q., Castillo, DE., Zarey, M., Hustad, AP., Chen, J., Li, J., 2018. *Aloe vera'nın* Hücre Çoğalması, Göçü ve Canlılığında Yara İyileşmesi Üzerindeki Etkileri. *Yaralar*, 30 , 263–268.