

FLORID CEMENTO-OSSEOUS DYSPLASIA: A CASE REPORT¹

FLORİD SEMENTO-OSSEÖZ DİSPLAZİ: VAKA RAPORU

Semra KAYAALTI ÖZARSLAN*
Müge ÇINA AKSOY***

H. Hüseyin YILMAZ**
Timuçin BAYKUL****

Makale Kodu/Article code: 312
Makale Gönderilme tarihi: 15.04.2010
Kabul Tarihi: 30.06.2010

ÖZET

Florid cemento-osseous dysplasia (FCOD) is a very rare benign fibro-osseous lesion presenting in the jaws. The process may be totally asymptomatic and in such cases, the lesion is generally detected during routine radiographic examination unless an asymmetry or pain occurs. The etiology of the lesion is unknown. A 41-year-old Turkish woman was referred to our clinic with a complaint of pain in the left third molar region. Based on clinical, radiographic and histopathological evaluation the diagnosis was concluded as florid cemento-osseous dysplasia. The displaced impacted third molar was extracted because of pain and recontouring was performed after one year from the initial diagnosis. The pain and displaced impacted third molar are unusual findings for FCOD. When FCOD was diagnosed, cortical expansion should be followed vigilantly life time to prevent the complications of an excessive surgery.

Key words: florid cemento-osseous dysplasia, fibro-osseous lesion, tooth migration.

ABSTRACT

Florid semento-osseöz displazi, çenelerde nadiren ortaya çıkan benign, fibro-osseöz bir lezyondur. Bu lezyonlar, asimetri veya ağrı meydana gelmediği surece asemptomatik olup, genellikle rutin radyografik muayene esnasında tespit edilmektedirler. Lezyonun etyolojisi bilinmemektedir. Kırk bir yaşındaki bayan hasta kliniğimize, sol üçüncü molar diş bölgesinde ağrı şikayeti ile başvurdu. Klinik, radyolojik ve histopatolojik bulgular değerlendirilerek hastaya florid semento-osseöz displazi tanısı konuldu. İlk aşamada, ağrı nedeniyle gömülü 3. molar diş çekilirken, bu operasyondan 1 yıl sonra mandibulada yeniden şekillendirme işlemi uygulandı. Ağrı ve dişlerde görülen yer değişikliği, florid semento-osseöz lezyonlar için nadir görülen bulgudur. Florid semento-osseöz lezyon tanısı konulduktan sonra, ileri cerrahi işlemler nedeniyle meydana gelebilecek komplikasyonları önleyebilmek amacıyla, kortikal ekspansiyon ömür boyu takip edilmelidir.

Anahtar kelimeler: florid semento-osseöz displazi, fibro-osseöz lezyon, diş migrasyonu.

INTRODUCTION

The classification of cemento-osseous lesions of the jaws has long been a matter of discussion for pathologists and clinicians. The current classification of cementomatous lesions, released in 1992 by the World Health Organization, is based on age, sex and histopathologic, radiographic and clinical characteristics, as well as location of the lesion. This classification

includes cemento-ossifying fibroma, benign cementoblastoma and the cemento-osseous dysplasia group.^{1,2} Periapical cemental dysplasia and florid cemento-osseous dysplasia (FCOD), which have also been reported under the term "gigantiform cementoma," are included in the cemento-osseous dysplasia group.³

FCOD is a benign fibro-osseous multifocal dysplastic lesion of the jaw in which mature bone is

¹ AÇBİD 1.Uluslararası Kongresi, 2007/Antalya, Poster Sunumu

* Dentist, PhD, Private Practice, Antalya,

** Associate Professor, Süleyman Demirel University, Faculty of Dentistry, Department of Oral Diagnosis and Radiology, Isparta,

*** Assistant Professor, Süleyman Demirel University, Faculty of Dentistry, Department of Oral and Maxillofacial Surgery, Isparta,

**** Associate Professor, Süleyman Demirel University, Faculty of Dentistry, Department of Oral and Maxillofacial Surgery, Isparta,



replaced with woven bone in a matrix of fibrous connective tissue.^{4,5} The etiology of FCOD is unknown, and there is no good explanation for its gender and racial predilections.⁶ FCOD has been reported in black, Asian and white populations but classic presentation of this disorder is found in middle-aged black women.⁷⁻¹² The true incidence of the lesion is also unknown. The process is mostly asymptomatic, and the lesion is usually detected incidentally on a radiograph taken for some other purposes.^{6,10,12} The classical radiographic appearance includes diffuse, lobular, irregular-shaped radiopacities throughout the alveolar process of the maxilla and mandible.^{1,13} It is initially radiolucent and opacifies progressively as it becomes more mature. The vascularity of the lesion decreases with the increased cementum-like deposition and the affected alveolar bone gradually changes into avascular, cementum-like tissue.¹³ It sometimes gives rise to extreme deformities and functional disturbances caused by dysplastic hyperproliferation.¹⁴ Also there may be localized expansion of the cortical plates or symptoms of dull aching pain or drainage. Lesions are often bilateral and have a symmetrical appearance.⁴

CASE PRESENTATION

A 41-year-old woman was admitted to Süleyman Demirel University, Faculty of Dentistry, Department of Oral and Maxillofacial Surgery with pain in the left third molar region. She was systemically healthy and extra-oral examination was within normal limits. Intraoral examination showed a slight buccal cortical expansion in the left mandibular posterior region. The vitality test of all affected teeth was positive. Radiographic examination revealed mixed radiopaque-radiolucent lesions throughout the mandible, from the right molar region to the left retromolar region. The third molar was impacted below the first molar. A root resorption was observed in the distal root of the second molar (Figure 1). A scintigraphic bone scan disclosed 3 areas of increased osteoblastic activity (Figure 2). The impacted third molar was removed and biopsy was performed. Histopathologically the lesion was composed of osteoid and cementum-like material, with fibroblasts associated with the trabeculae of the calcified material. Based on the clinical examination, radiographic evaluation and histopathological examination, we confirmed the diagnosis as florid cemento-osseous dysplasia. An expansion at the

anterior mandible was detected and recontouring was performed under local anesthesia a year later (Figure 3). The patient is under our follow-up as of 2004 (Figure 4,5,6).

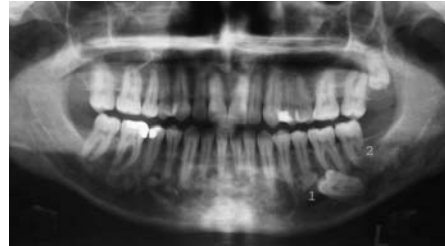

Figure 1. Panoramic radiograph taken at the 1st visit in 2004, showing irregular radioopaque-radiolucent lesions throughout the mandible.

1. Impacted 3rd molar under the roots of the 1st molar; a position suggesting possible migration from the retromolar region.
2. Resorption of the distal root of the 2nd molar due to the possible migration of the 3rd molar.

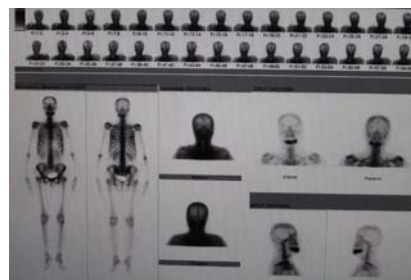


Figure 2. Scintigraphic bone scans disclosing 3 areas of increased osteoblastic activity throughout the mandible

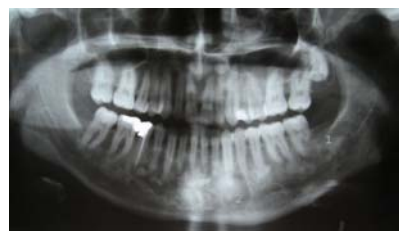

Figure 3. Panoramic radiograph taken at the postoperative 1st year showing increased radiopaque areas due to the maturation of the lesions.

1. Increased opacity due to the maturation of the lesion compared with 2004.
2. The amount of the opacities at the apical region of the canine can be detected compared with 2004.
3. Recontouring was performed due to the expansion at the anterior region of the mandible.

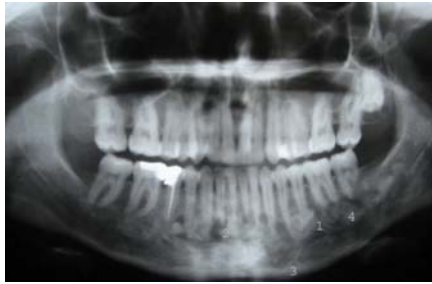

Figure 4. Panoramic radiograph taken at the postoperative 2nd year.

1. The radiolucencies at the apices of 2nd premolar and 1st molar were increased because of the maturation of the lesions at this site.
2. The borders of the radiolucent area at the lateral incisor and canine region were more detectable compared with previous radiographs.
3. The radiolucency at the apex of the canine increased to the inferior border of the mandible.
4. At apices of the 1st and 2nd molars, a brief radiolucency was detected, especially compared with previous lesions.

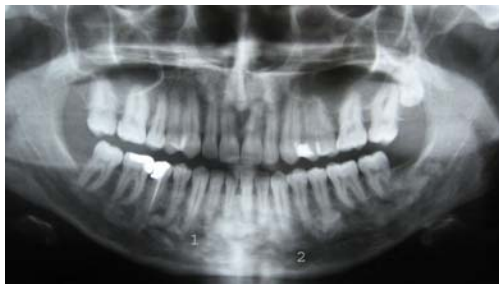

Figure 5. Panoramic radiograph showing changes in radiodensity at the postoperative 3rd year.

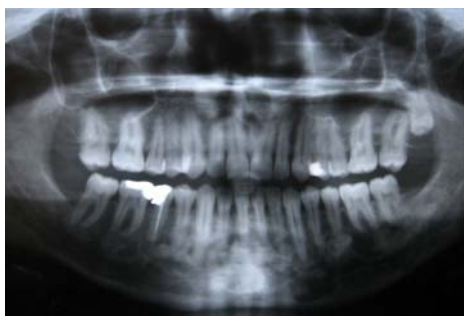

Figure 6. Panoramic radiograph taken 1 year after the last visit, demonstrating no changes compared with 2007

DISCUSSION

The presented case was referred to our clinic with a complaint of pain and swelling in the left mandibular posterior region. As the radiographic examination revealed cemento-osseous lesions in the whole mandible, it was seen that the source of the pain was the impacted third molar which was localized under the roots of the first molar (Figure 1). The swelling was interpreted as cortical expansion because of the impacted third molar and cemento-osseous lesions in the same area. Another conspicuous finding at this region was the localization of the impacted third molar that was under the first molar and the nearly completely resorbed distal root of the second molar. It suggested to us a possible migration of the impacted third molar because of the hyperproliferation at the related site. With the anterior cortical expansion and mucosal perforation that came out at the first year follow-up this case revealed almost all possible clinical findings.

In the asymptomatic patient, it is probably wise to keep the patient under observation without surgical intervention. A biopsy is not required to confirm the diagnosis as this is usually established radiographically. It is not normally justified to surgically remove these lesions, as this often requires extensive surgery. Instead, follow-up and recontouring when cortical expansion occurs is recommended.¹⁵ Whenever surgical treatment is planned, the lack of vascularity of the lesion and increased risk of osteomyelitis should be considered. The affected area undergoes changes from normal vascular bone into an avascular cementum-like lesion. Furthermore, complete removal of necrotic tissue may result in a large discontinuity defect.¹³ But, in lesions causing pain and disturbance as in the presented case, these risks of the surgery must be taken for an adequate treatment. However, recontouring should be the treatment of choice if there is only cortical expansion and mucosal perforation due to the cemento-osseous lesions as we performed one year after the initial diagnosis.

Radiographically, a mixed radiolucent and radiopaque appearance is the common finding and the lesions usually are bilateral and present in both jaws. However, the mandible is the more common location. The density of internal structure can vary from an equal mixture of radiolucent and radiopaque regions to almost complete radiopacity.^{7,16} It depends on the

degree of maturation of the lesion.¹⁷ The initial radiographic appearance of this group of lesions is radiolucent. Over the time, the lesions progress to a mixed radiolucent-radiopaque stage before progressing to a completely radiopaque stage.⁴ The classical appearance of the radiopaque regions includes diffuse, small oval and circular regions (cotton-wool appearance), irregular-shaped radiopacities throughout the alveolar process of the maxilla and mandible.¹³ On the radiographs of the presented case, the above-mentioned radiographic appearance and the progression of the radiographic findings can be evaluated demonstratively (Figure 1,3,4,5,6).

Although FCOD may have similarities with jaw bone changes in familial adenomatosis coli (Gardner's syndrome), florid cemento-osseous dysplasia has no other skeletal changes or skin tumors or even the dental anomalies that are seen in this syndrome. As such, Paget's disease should be differentiated with the polyostotic dysplastic lesions and the disease also shows biochemical serum changes.¹⁵ Also, chronic diffuse sclerosing osteomyelitis should be differentiated from FCOD which shows a single area of diffuse sclerosis containing small, ill-defined osteolytic areas, whereas florid cemento-osseous dysplasia is seen as multiple round or lobulated opaque masses.¹⁸

CONCLUSION

FCOD is an asymptomatic disease though clinical symptoms like mucosal perforation due to cortical expansion, tooth displacement or pain may occur. Patients inflicted with such lesions should be followed-up life time to prevent excessive surgery that may cause serious complications due to lack of vascularity.

REFERENCES

1. Goncalves M, Pispico R, Alves Fde A, Lugao CE, Goncalves A. Clinical, radiographic, biochemical and histological findings of florid cemento-osseous dysplasia and report of a case. *Braz Dent J* 2005; 16(3): 247- 50.
2. Kramer IR, Pindborg JJ, Shear M. The WHO Histological Typing of Odontogenic Tumors. A commentary on the Second Edition. Review. *Cancer* 1992; 70(12): 2988-94.
3. Toffanin A, Benetti R, Manconi R. Familial florid cemento-osseous dysplasia: a case report. *J Oral Maxillofac Surg* 2000; 58(12) :1440-6.
4. Singer SR, Mupparapu M, Rinaggio J. Florid cemento-osseous dysplasia and chronic diffuse osteomyelitis. Report of a simultaneous presentation and review of the literature. *J Am Dent Assoc* 2005; 136(7): 927-31.
5. Wakasa T, Kawai N, Aiga H, Kishi K. Management of florid cemento-osseous dysplasia of the mandible producing solitary bone cyst: report of a case. *J Oral Maxillofac Surg* 2002; 60(7): 832-5.
6. Beylouni I, Farge P, Mazoyer JF, Coudert JL. Florid cemento-osseous dysplasia: Report of a case documented with computed tomography and 3D imaging. *Oral Surg Oral Med Oral Pathol Oral Radiol Endod* 1998; 85(6): 707-11.
7. Tonioli MB, Schindler WG. Treatment of a maxillary molar in a patient presenting with florid cemento-osseous dysplasia: a case report. *J Endod* 2004; 30(9): 665-7.
8. Zafersoy Akarslan Z, Altundağ Sandıkçı S. Radiographic evaluation of a florid cemento-osseous dysplasia lesion seen in a Caucasian with panoramic radiography, cone beam CT and 3D reconstruction. *Atatürk Üniv. Dış Hek. Fak. Derg* 2010; 20(1): 38-42.
9. Özen Sandıkçı E, Zengin Z, Sümer P, Günhan Ö. Semento-osseöz displazi: Dört olgu raporu. *Cemento-osseous dysplasia: Report of four cases. Hacettepe Dışhekimliği Fakültesi Dergisi* 2007; 31(2): 38-42.
10. Meral G, Çakacı M, Er N. Florid cemento-osseous dysplasia: A case report. *Hacettepe Dışhekimliği Fakültesi Dergisi* 2005; 29(4): 104-7.
11. Akkaya N, Avcu N, Kansu Ö, Er N, Kansu H. Florid semento osseöz displazi: Olgu raporu Florid cemento-osseous dysplasia: A case report. *Hacettepe Dışhekimliği Fakültesi Dergisi* 2005; 29(1): 52-5.
12. Gündüz K, Çelenk P, Metin M, Günhan Ö. Florid semento-osseöz displazi [Florid cemento-osseous dysplasia]. *GÜ Dışhek Fak Derg* 2005; 22(3): 181-4.



13. Bencharit S, Schardt-Sacco D, Zuniga JR, Minsley GE. Surgical and prosthodontic rehabilitation for a patient with aggressive florid cemento-osseous dysplasia: a clinical report. J Prosthet Dent 2003; 90(3): 220-4.
14. Miyake M, Nagahata S. Florid cemento-osseous dysplasia. Report of a case. Int J Oral Maxillofac Surg 1999; 28(1): 56-7.
15. Jerjes W, Banu B, Swinson B, Hopper C. Florid cemento-osseous dysplasia in a young Indian woman: A case report. Br Dent J 2005; 198(8): 477- 8.
16. White SC, Pharoah MJ,eds. Oral Radiology - Principles and Interpretation. St Louis; Mosby: 2000.
17. Mangala M, Ramesh DN, Surekha PS, Santosh P. Florid cemento-osseous dysplasia: Review and report of two cases. Indian J Dent Res 2006; 17(3): 131-4.
18. Schneider LC, Mesa ML. Differences between florid osseous dysplasia and chronic diffuse sclerosing osteomyelitis. Oral Surg Oral Med Oral Pathol 1990; 70: 308-12.

Yazışma Adresi

Dr. Semra KAYAALTI ÖZARSLAN
Atatürk Cad. Yücel Ege Apt. No29/6
ANTALYA/TÜRKİYE
e-mail: semraozarslan@hotmail.com
Tel: 0532 638 42 60

