

## A Rare Case of Increase in Seizure Frequency After COVID19

Nadir Bir Olgu: COVID19 Sonrası Nöbet Sıklığında Artış

İD Fatih Çatal İD Murat Özaraç İD Onur Karakayalı  
İD Yusuf Yürümez İD Nuray Aslan

Department of Emergency Medicine, Sakarya University Faculty of Medicine, Sakarya, Turkey

## ABSTRACT

*Tuberous sclerosis complex (TSC) is a rare genetic disease and affected individuals are usually characterized by the triad of cutaneous angiofibroma, mental retardation and epileptic seizures. Different clinical tables may occur due to the inflammatory response after COVID19. Apart from this, there is no article in the literature reporting that the frequency of seizures has increased as stated in the case example presented. A 30-year-old male patient was brought to our emergency room by his relatives with the complaint of epileptic seizures. Relatives of the patients stated that the frequency of seizures increased progressively after having COVID19 a month ago and that he had seizures 10 times in the last 24 hours. As seen in the case we presented, there may be an increase in the frequency of seizures in the late period after COVID19 in patients with epilepsy. For this reason, patients with an increased seizure frequency by emergency medicine physicians should also be evaluated for COVID19.*

## ÖZET

*Tüberoskleroz Kompleksi (TSK) nadir görülen bir genetik hastalıktır ve etkilenen bireyler genellikle epileptik nöbetler, mental retardasyon ve kutanöz anjiyofibroma üçlüsü ile karakterize edilir. COVID19 sonrası inflamatuvar yanıtı bağli olarak farklı klinik tablolar ortaya çıkabilir. Bunun dışında literatürde sunulan vaka örneğinde belirtildiği gibi nöbet sıklığının arttığını bildiren bir makale bulunmamaktadır. 30 yaşında erkek hasta epileptik nöbet şikayeti ile yakınları tarafından acil servisimize getirildi. Hasta yakınları, bir ay önce COVID19 geçirdikten sonra nöbet sıklığının giderek arttığını, son 24 saatte 10 kez nöbet geçirdiğini ifade etti. Bizim olgumuzda da görüldüğü gibi epilepsi tanılı hastalarda COVID19 sonrası geç dönemde nöbet sıklığında artış olabilir. Bu nedenle acil tıp hekimleri tarafından nöbet sıklığında artış tanımlayan hastaların COVID19'a yönelik değerlendirilmesi gerekmektedir.*

## Keywords:

Complications  
COVID19  
Drug resistant epilepsy  
Epileptic seizure  
Tuberous sclerosis complex

## Anahtar Kelimeler:

Komplikasyonlar  
COVID19  
İlacı dirençli epilepsi  
Epileptik nöbet  
Tüberoskleroz kompleksi

## INTRODUCTION

Tuberous sclerosis complex (TSC) is a rare hereditary disease that can affect almost all systems. Its prevalence has been reported to be between 1/6000 and 1/10 000 live births in recent studies (1). Affected individuals are usually characterized by the triad of cutaneous angiofibroma, mental retardation and epileptic seizures seen in the early stages of life; however, less than 30% of TSC patients have this triad while 6% have none of these features (2). Renal complications and seizure are the most common causes of increased morbidity and mortality in TSC patients compared to the normal population (3,4). It is indicated that seizures may develop in the acute infectious period in patients with a diagnosis of COVID19. However, only one case has been described of developing status epilepticus after having COVID19. The possible mechanism is thought to be triggered by refractory status epilepticus secondary to the postinfectious inflammatory response. Different clinical tables may occur due to the inflammatory response after COVID19. Isolated symptoms related to the affected organ system can be observed, especially due to systemic or local cytokine

increase. Apart from this, there is no article in the literature reporting that the frequency of seizures has increased as stated in the case example presented (5).

In this case report, a 30-year-old patient who had COVID19 a month ago and then presented to the emergency room with the complaint of an increase in the frequency of epileptic seizures and was diagnosed with TSC was evaluated.

## CASE REPORT

A 30-year-old male patient was brought to our emergency room by his relatives with the complaint of epileptic seizures which occurred approximately 10 times in the last twenty-four hours. His seizures were in a self-terminating form, lasting two to three minutes. It was learned that the patient had a history of epilepsy and mental retardation, used valproic acid and olanzapine regularly. Relatives of the patients stated that the frequency of seizures, which was once or twice a year, increased progressively to once or twice a day after having COVID-19 a month ago. There was no feature in his family history. His parents did not have a chronic disease or consanguineous marriage. There were no pathological symptoms in his vital signs.

**Correspondence:** Fatih Çatal, Dept. of Emergency Medicine, Sakarya University, Adapazari, Sakarya, Türkiye. E-mail: fatihcatal94@hotmail.com

**Cite as:** Çatal F, Özaraç M, Karakayalı O, Yürümez Y, Aslan N. A Rare Case of Increase in Seizure Frequency After COVID19. Phnx Med J. 2023;5(2):115-118.

**Received:** 07.11.2022

**Accepted:** 12.01.2023



On physical examination, he had confused consciousness, his cooperation and orientation were limited, pupils were isochoric, indirect and direct light reflexes were bilaterally positive, successful in localizing painful stimuli in all four extremities, and plantar reflexes were bilaterally flexor. In his dermatological examination, there were hypopigmented macules on the back and forehead; Plaques with raised skin, rough surface, and irregular edges, consistent with shagreen patch, in the 3rd-5th rib space on the left thorax and the left lumbar region (Image 1), tiny, erythematous, symmetrically located papules compatible with adenoma sebaceum, around the nose, cheeks, and chin (Image 2). Routine biochemistry and hemogram tests were normal in the laboratory examination. In contrast-enhanced brain magnetic resonance imaging (MRI), cortical and mild nodular T2 signal increases were observed at the level of high convexity, in the right frontal, parafalcine area, and lateral peripheral level, consistent with the cortical tuber, which is accepted as cortical dysplasia (Image 3). There was no pathological image in the brain computed tomography (CT) and chest CT. In the echocardiography performed by the cardiology specialist, an image compatible with rhabdomyoma, which is the cardiac involvement of the TSC, was not observed. In the urinary system ultrasonography performed by the radiology specialist, an image of angiomyolipoma, cyst, or mass, which is compatible with the renal involvement of TSC, was not observed. In the examination performed by an ophthalmologist, the anterior and posterior segments were assessed as normal. The patient was given phenytoin 750 mg intravenously at a previous hospital before being referred to our hospital. The patient was hospitalized with consultation with the neurology department. After seizure control was achieved, the patient was discharged with the recommendation to continue the same treatment.

#### DISCUSSION

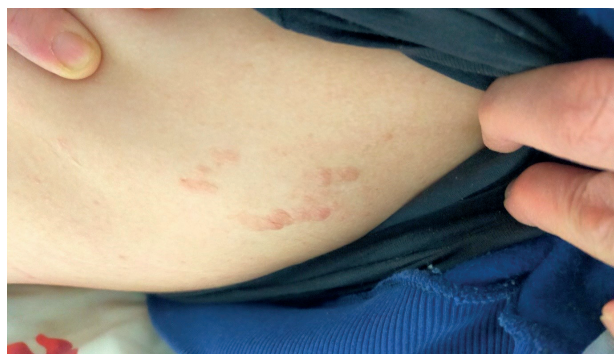Mutation in one of the TSC2 or TSC1 genes causes hyperactivation in the mTOR pathway results in the development of hamartomas or benign tumors in many organ systems, including the kidneys, heart, eyes, brain and skin (3, 6).

The criteria for clinical diagnosis of the disease were redefined in 2012 by the International TSC Consensus Group (Table 1) (1).

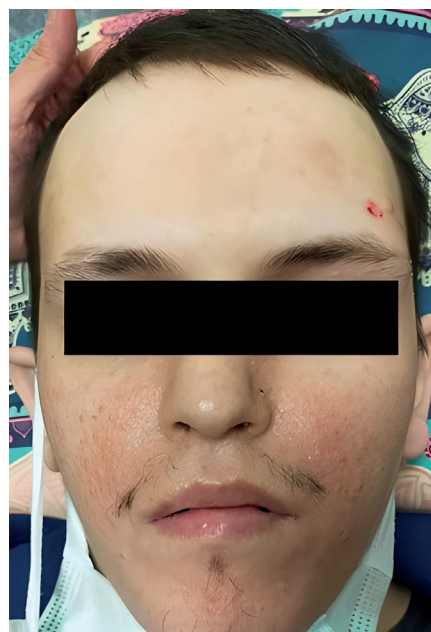Hypomelanotic macules are seen in approximately 66.7-97.2%, facial angiofibroma in approximately 57.3-74.5%, and shagreen patches in approximately 22.7-48.1% of patients which are the skin symptoms of TSC (3). While these symptoms were also present in our patient, other skin symptoms were not present.

One of the central nervous system symptoms of TSC, subependymal nodules are seen in approximately 78.2% of patients, while cortical tubers are seen in approximately 88.2% of patients (3). In our patient, there was no subependymal nodule while cortical tubers were present. While seizures affect approximately 62% to 93% of TSC patients, cortical dysplasias have been associated with these seizures and learning difficulties (4, 7).

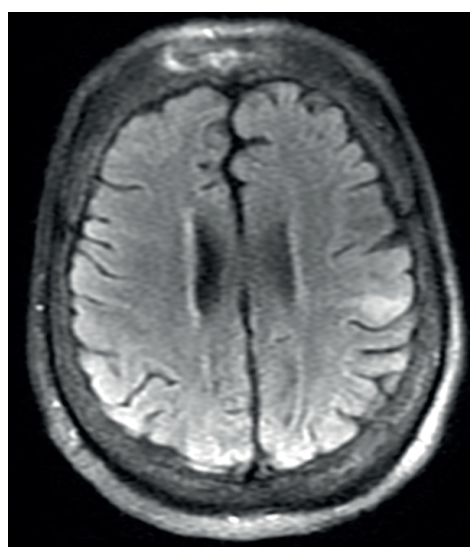
Our patient had 4 major symptoms including hypomelanotic macules, shagreen patches, angiofibroma, and cortical dysplasia, which are among the major diagnostic criteria,



**Figure 1:** Plaques with raised skin, rough surface, and irregular edges, consistent with shagreen patch (Written consent was obtained from the legal guardian of the patient)



**Figure 2:** Adenoma sebaceum, a type of angiofibroma, around the nose, cheeks, and chin (Written consent was obtained from the legal guardian of the patient)



**Figure 3:** Cortical tuber, which is accepted as cortical dysplasia

Table 1: Criteria for the clinical diagnosis of tuberous sclerosis complex

Major Symptoms	Minor Symptoms
1. Hypomelanotic macules ( $\geq 3$ ; at least 5 mm diameter)	1. Confetti skin lesions
2. Angiofibromatous ( $\geq 3$ ) or fibrous cephalic plaques	2. Numerous pits in tooth enamel
3. Ungual fibroma ( $\geq 2$ )	3. Intraoral fibroma
4. Shagreen patch	4. Hypopigmented patch on the retina
5. Multiple retinal hamartomas	5. Multiple kidney cysts
6. Cortical dysplasias	6. Extrarenal hamartoma
7. Subependymal nodules	7. Sclerotic bone lesions
8. Subependymal giant cell astrocytomas	
9. Rhabdomyoma of the heart	
10. Lymphangiomyomatosis (LAM)*	
11. Angiomyolipoma ( $\geq 2$ ) *	
Definitive Diagnosis: 2 major factors or 1 major and $\geq 2$ minor factor	
Possible Diagnosis: 1 major or $\geq 2$ minor factors	

\*The presence of lymphangiomyomatosis or angiomyolipoma alone is sufficient for a definitive diagnosis.

and he met the definitive diagnostic criteria.

Various treatment options are available for TSC-related epilepsy and infantile spasms such as antiepileptic drugs, hormone therapy, ketogenic diets, epilepsy surgery and vagus nerve stimulation (4). However, one-third of these patients become resistant to seizures treatments. Drug-Resistant Epilepsy (DRE) carries a significant cognitive, economic and social burden. Therefore, it is necessary to identify risk factors that increase the likelihood of drug-resistant seizures (8). In our case, the possible factor that increased the frequency of seizures and made them resistant was COVID19 infection.

In most studies, it is stated that DRE is proportional to the number of cortical tubers. The presence of epileptiform discharges in EEG increases the risk of resistant seizures. Most of the risk factors cannot be changed, but early recognition of refractory seizures and initiation of appropriate treatment before clinical seizures become more frequent reduces the risk of resistant seizures (8). Early and resistant seizures have been associated with poor neurological outcomes. Aggressive seizure control can reduce the harmful neurodevelopmental effects of

epilepsy. Antiepileptic drugs and steroids and classical can be used for treatment, and seizures can be ceased with everolimus, an mTOR inhibitor. It is stated that cannabinoids may be generally safe and effective for treatment-resistant seizures in children and adults with severe early-onset epilepsy (9).

#### CONCLUSION

Our case was newly diagnosed with TSC in the emergency department and the increase in seizure frequency was evaluated in relationship with COVID19 infection. For this reason, it is necessary to evaluate especially the dermatological symptoms of patients who apply to the emergency department with the complaint of epileptic seizures and have a history of mental retardation, and besides the diagnosis of TSC should be considered in the differential diagnosis by emergency medicine physicians. As seen in the case we presented, there may be an increase in the frequency of seizures in the late period after COVID19 in patients with epilepsy. For this reason, patients with an increased seizure frequency by emergency medicine physicians should also be evaluated for COVID19.

**Conflict of Interest:** No conflict of interest was declared by the authors.

**Ethics:** The patient informed consent form was obtained.

**Funding:** There is no financial support of any person or institution in this research.

**Approval of final manuscript:** All authors.

#### REFERENCES

- Northrup H, Aronow ME, Bebin EM, Bissler J, Darling TN, de Vries PJ, et al. Updated International Tuberous Sclerosis Complex Diagnostic Criteria and Surveillance and Management Recommendations. *Pediatr Neurol.* 2021; 123: 50-66. DOI: 10.1016/j.pediatrneurol.2021.07.011.
- Seibert D, Hong CH, Takeuchi F, Olsen C, Hathaway O, Moss J, et al. Recognition of tuberous sclerosis in adult women: delayed presentation with life-threatening consequences. *Ann Intern Med.* 2011; 154(12): 806-813. DOI: 10.7326/0003-4819-154-12-201106210-00008.
- Zöllner JP, Franz DN, Hertzberg C, Nabbout R, Rosenow F, Sauter M, et al. A systematic review on the burden of illness in individuals with tuberous sclerosis complex (TSC). *Orphanet J Rare Dis.* 2020; 15(1): 23. DOI: 10.1186/s13023-019-1258-3.
- Nabbout R, Belousova E, Benedik MP, Carter T, Cottin V, Curatolo P, et al. Epilepsy in tuberous sclerosis complex: Findings from the TOSCA Study. *Epilepsia Open.* 2018; 4(1): 73-84. DOI: 10.1002/epi4.12286.
- Carroll E, Neumann N, Aguero-Rosenfeld ME, Lighter J, Czeisler BM, Melmed K, et al. Post-COVID-19 inflammatory syndrome manifesting as refractory status epilepticus. *Epilepsia.* 2020; 61(10): e135-e139. DOI: 10.1111/epi.16683.
- Salussolia CL, Klonowska K, Kwiatkowski DJ, Sahin M. Genetic Etiologies, Diagnosis, and Treatment of Tuberous Sclerosis Complex. *Annu Rev Genomics Hum Genet.* 2019; 20: 217-240. DOI: 10.1146/annurev-genom-083118-015354.
- Northrup H, Krueger DA. Tuberous sclerosis complex diagnostic criteria update: recommendations of the 2012 International Tuberous Sclerosis Complex Consensus Conference. *Pediatr Neurol.* 2013; 49(4): 243-254. DOI: 10.1016/j.pediatrneurol.2013.08.001.

8. Miszewska D, Sugalska M, Józwiak S. Risk Factors Associated with Refractory Epilepsy in Patients with Tuberous Sclerosis Complex: A Systematic Review. *J Clin Med.* 2021; 10(23): 5495. DOI: 10.3390/jcm10235495.
9. Curatolo P, Nabbout R, Lagae L, Aronica E, Ferreira JC, Feucht M, et al. Management of Epilepsy Associated with Tuberous Sclerosis Complex: Updated Clinical Recommendations. *Eur J Paediatr Neurol.* 2018; 22(5): 738-748. DOI: 10.1016/j.ejpn.2018.05.006.