



## Surgically proven small bowel intussusception in children: Analysis of 36 cases

Hikmet Zeytun<sup>1</sup>, Erol Basuguy<sup>2</sup>, Serkan Arslan<sup>2</sup>, Bahattin Aydoğdu<sup>2</sup>, Mehmet Hanifi Okur<sup>2</sup>

*1 Gaziantep University, Faculty of Medicine, Department of Pediatric Surgery, 27070, Gaziantep, Turkey*

*2 Dicle University, Faculty of Medicine, Department of Pediatric Surgery, 21280, Diyarbakir, Turkey*

*Received: 04.07.2022; Revised: 27.10.2022; Accepted: 28.10.2022*

### Abstract

**Background:** Intussusception is one of the most common abdominal emergencies in children. While the majority of childhood intussusceptions are ileocolic and idiopathic, small bowel intussusceptions are rare and a pathological trigger is often blamed for the etiology. Ultrasonography is the most commonly used diagnostic tool in the diagnosis of intussusception.

**Objectives:** To determine auxiliary diagnostic criteria for ultrasonography in the differentiation of small bowel intussusceptions based on ultrasonography, reduction and surgical findings of surgically confirmed small bowel intussusceptions and to contribute to the diagnosis and treatment algorithm of small bowel intussusceptions based on our clinical experience.

**Methods:** The records of patients who underwent surgery for small bowel intussusception at the Faculty of Medicine, Department of Pediatric Surgery between January 2008 and December 2020 were retrospectively reviewed. Demographic characteristics, ultrasonographic findings, onset and duration of symptoms, treatment method, intraoperative findings and histopathological results of the patients were recorded.

**Results:** Thirty-six pediatric patients with small bowel intussusception were operated. The average age of these patients was  $59 \pm 49.7$  months and %78 was male. The location of the small bowel intussusception detected by ultrasound scan was the paraumbilical area and left quadrant in 19 (53%) patients and the right quadrant in 15 (42%) patients. In ultrasonography, the mean diameter of the invaginated segment was 3 (1.2-6.5) cm and the mean length was 6.7 (3-15) cm. Pathological lead points were detected in the etiology of nineteen (53%) patients. Thirteen (36%) patients underwent segmental resection and anastomosis due to necrosis.

**Conclusions:** Small bowel intussusceptions are often localized in the paraumbilical and left upper quadrant. However, it should be kept in mind that it may be localized in the right lower quadrant like ileocolic invaginations. Enema reduction can be used as an adjunctive diagnostic method to exclude ileocolic invaginations rather than treatment in these patients. The diameter and length of the invaginated segment may be decisive in the surgical decision of the small bowel intussusception.

**Keyword:** small bowel, enema reduction, intussusception, Meckel, children.

DOI: 10.5798/dicletip.1197193

**Correspondence / Yazışma Adresi:** Hikmet Zeytun, Gaziantep University, Faculty of Medicine, Department of Pediatric Surgery, 27070, Gaziantep, Turkey  
e-mail: hzeytun333@gmail.com

## Çocuklarda cerrahi olarak ispatlanmış ince bağırsak invaginasyonları: 36 vakanın analizi

### Öz

**Giriş:** İnvaginasyon, çocuklarda sık görülen abdominal acillerden birisidir. Çocukluk çağı invaginasyonlarının büyük çoğunluğu ilekolik seviyede ve idiopatik iken, ince barsak invaginasyonları daha nadir olup etyolojide sıklıkla bir patolojik tetikleyici suçlanmaktadır. Ultrasonografi invaginasyon tanısında en sık kullanılan tanı aracıdır.

**Amaç:** Cerrahi olarak kesinleşmiş ince barsak invaginasyonlarının ultrasonografi, redüksiyon ve cerrahi bulgularından yola çıkarak ince bağırsak invaginasyonlarında yardımcı tanı kriterleri belirlemek ve klinik deneyimlerimize dayanarak ince barsak invaginasyonlarının tanı ve tedavi algoritmasına katkıda bulunmak.

**Yöntemler:** Tıp Fakültesi Çocuk Cerrahisi Kliniğinde Ocak 2008 - Aralık 2020 yılları arasında ince bağırsak invaginasyonları nedeniyle cerrahi olan hastaların kayıtları retrospektif olarak incelendi. Hastaların demografik özellikleri, ultsonografik bulguları, semptomların başlangıcı ve süresi, tedavi yöntemi, intraoperatif bulguları ve patoloji sonuçları kaydedildi.

**Bulgular:** İnce bağırsak invaginasyonu olan 36 hasta cerrahi olarak tedavi edildi. Bu hastaların ortalama yaşı  $59 \pm 49,7$  ay ve %78'i erkek idi. Ultrasonografi ile saptanan invaginasyon segmentinin yeri 19 (%53) 'unda paraumbilikal alan ve sol kadran, 15(%42) 'inde sağ kadran idi. Ultrasonografide invagine segmentin ortalama çapı 3 (1,2-6,5) cm ve ortalama uzunluğu 6,7 (3-15) cm idi. Hastaların 19(%53)'unda etyolojide patolojik lead point tespit edildi. Onüç (%36) hastaya nekroz nedeniyle segmental rezeksiyon ve anastomoz uygulandı.

**Sonuçlar:** İnce barsak invaginasyonları sıklıkla paraumbilikal ve sol üst kadran lokalizasyonludur. Ancak ilekolik invaginasyonlar gibi sağ alt kadran lokalizasyonlu olabileceği de unutulmamalıdır. Enema redüksiyon, bu hastalarda tedaviden ziyade ilekolik invaginasyonların dışlanmasında yardımcı bir tanı yöntemi olarak kullanılabilir. SBI'nın cerrahi kararında, invajine segmentin çapı ve uzunluğu belirleyici olabilir

**Anahtar kelimeler:** İnce barsak, sıvı redüksiyon, invaginasyon, mekkel, çocuk.

## INTRODUCTION

Small bowel intussusceptions (SBI) account for the majority of adult intussusceptions, while SBI is less common in the pediatric age group than ileocolic intussusceptions with an incidence of 2.5%<sup>1,2</sup>. In addition, SBI in children is commonly seen together with a concomitant pathological lead point (PLP)<sup>2-7</sup>.

Ultrasound scan (USS) is the main diagnostic tool for intussusception with a sensitivity for ileocolic intussusception of 98%–100% and for SBI of 76%–84%<sup>2,4,6,9,11</sup>. The criteria for distinguishing between these two conditions, which differ in their treatment approaches, remain under debate but are related to the diameter and length of the invaginated segment as seen on USS<sup>6,12,13</sup>. We aimed to determine additional diagnostic criteria in this distinction based on the USS, enema reduction and surgical findings of the patients. However, while there is an accepted algorithm for the diagnosis and treatment of ileocolic intussusception<sup>14</sup>, this is

not the case for SBI<sup>1,9</sup>, in part because of the limited number of patients with surgically proven SBI and, thus, the lack of case series. In this paper, we present our experience in the diagnosis, treatment, and complications of surgically proven pediatric SBI. Our data will contribute to the creation of an algorithm for this disease.

## METHODS

The records of patients younger than 18 years of age who were followed up and treated for intussusception in Pediatric Surgery Clinic between January 2008 and December 2020 were reviewed retrospectively. Patients with surgically treated SBI were included in the study; those with colonic involvement in the intussusception were excluded. Demographic characteristics, radiological findings, onset and duration of symptoms, treatment method, intraoperative findings, and histopathological results were reviewed retrospectively.

Intraoperative findings, postoperative complications, histopathological findings, and mortality were recorded using Excel (Microsoft Corp., Redmond, WA, USA). The data were statistically analyzed using SPSS, version 18.0 (SPSS Inc., Chicago, IL, USA). A bivariate Pearson’s correlation test was used to analyze variability in the diameter and length of the invaginated segment according to the age of the patient and the duration of the symptoms.

Asymptomatic patients with intussusception who were diagnosed incidentally by USS were also followed up by USS, whereas symptomatic patients with a stable clinical presentation underwent enema reduction to treat ileocolic intussusceptions or to confirm the diagnosis of SBI. A control USS was performed 30 min after the enema reduction procedure. Patients without any intussusception in colonic level during enema reduction who had both persistent intussusceptions detected by USS and poor clinical progress were operated on based on a preliminary diagnosis of SBI. Patients with a poor medical status who had intussusceptions, underwent surgery following fluid and electrolyte replacement (Fig. 1). Ethics committee approval was obtained from the Local Ethics Committee. (No:163/09.06.2022).

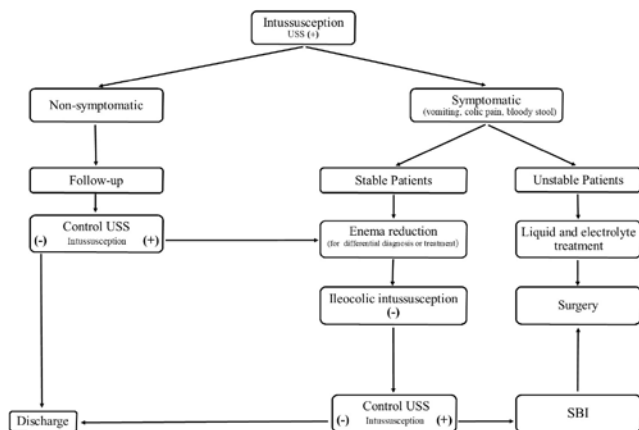
## RESULTS

SBI was detected in 36 patients who were treated surgically. Their mean age was  $59 \pm 49.7$  months, and 28 (78%) were males. Clinical symptoms included vomiting (86%), abdominal pain, discomfort (83%), and bloody stool (19%). The average period between the onset of symptoms and surgery was 12.5 (6–24) h.

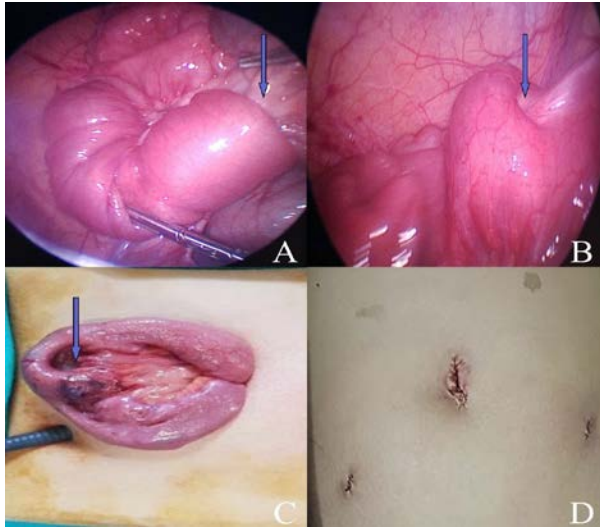
The invaginated segment had a mean diameter of 3 (1.2–6.5) cm and mean length of 6.7 (3–15) cm according to USS evaluation. The association between patient age and the diameter of the invaginated segment was statistically significant ( $P < 0.001$ ), as was the association between symptom duration and the length of the invaginated segment ( $P < 0.001$ ) (Fig. 3).

The location of the intussusception detected by USS was the paraumbilical area and the left quadrant in 19 (52%) patients and the right quadrant in 15 (42%) patients. Localization was not specified in two patients.

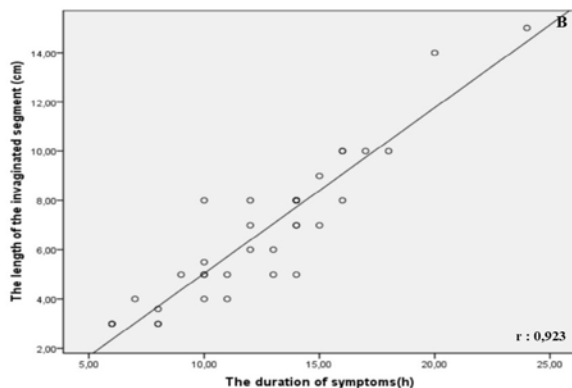
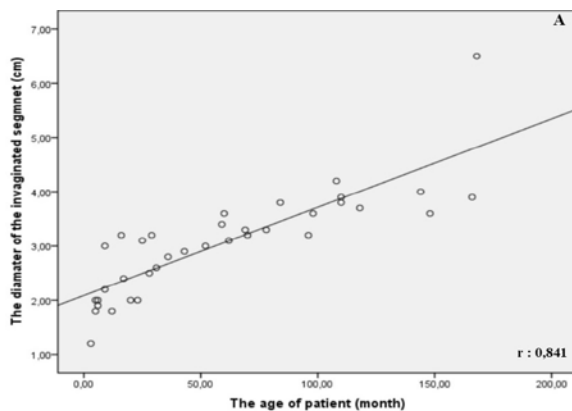
Of the 27 (75%) stable patients who received enema reduction, 25 (93%) were operated on because of a diagnosis of SBI due to persisting intussusception according to control USS, while only 2 (7%) patients presented normal USS findings. However, intussusception was detected in both in the USS performed when similar symptoms recurred during the follow-ups. Seven (19%) patients were unstable and, thus, were operated on following fluid and electrolyte replacement; this group included four (57%) patients diagnosed with SBI after trauma or a surgical procedure. The etiology was determined to be a PLP in 19 patients, 16 (84%) of whom were older than 1 year.



**Figure 1.** Diagnosis and treatment algorithm of patients with small bowel intussusception.



**Figure 2.** A. Laparoscopic reduction of invaginated intestinal segment B. The image after reduction C. Lead point meckel diverticulum and extracorporeal resection D. Postoperative image.



r, correlation coefficient

**Figure 3.** A. Correlation curve showing the relationship between the age of the patients and the diameter of invaginated segment B. Correlation curve showing the relationship between the duration of symptoms and the length of invaginated segment.

Laparotomy was performed in 26 (72%) patients and laparoscopy in 10 (28%) (Fig. 2). Thirteen (36%) patients underwent segmental resection due to necrosis; the PLP was excised in five (42%) patients who had segmental resection. Wedge resection for the PLP was performed in 14 (39%) patients, and 9 (25%) patients had surgical reduction only. The clinical and histopathological findings of the patients are summarized in Table 1.

**Table I:** Clinical data from patients with small bowel intussusception

	n (%)
Sex:	
Male	28 (78)
Female	8 (22)
Mean age(months):	59 ± 49.7
Symptoms:	
Vomiting	31 (86)
Abdominal pain	30 (83)
Bloody Stool	7 (19)
Size of invaginated segment (cm):	
Length	6,7 ± 3
Diameter	3,0 ± 1
Lead point:	
Meckel	14 (74)
Polyp	2 (10)
Lymphoma	2 (10)
Cavernous hemangioma	1 (6)
Operation procedure:	
Wedge resection for PLP	14 (39)
Segmental resection (5 with PLP)	13 (36)
Manuel reduction	9 (25)
Location (USS):	
PU/LU/LL/RU/RL	11;4;4;7;8
Mean hospital stays(days):	5,4 (3-10)

PU paraumbilical, LU left upper, LL left lower, RU right upper, RL right lower, USS ultrasound scan, PLP pathological lead point

## DISCUSSION

The majority of intussusception cases in children are ileocolic, whereas SBI is rare and patient series are, accordingly, very limited<sup>1</sup>. There are even fewer documented cases of surgically proven SBI<sup>2,4,6,9,10,15</sup>. The largest surgically proven SBI series to date was Ko et al.<sup>2</sup> with 19 patients. With this study, we present the largest series in the literature with 36

patients. This higher rate can be explained by the fact that our medical center is a third-stage regional hospital and the only center where enema reduction is performed.

The early diagnosis and treatment of SBI are critical, to reduce ischemic intestinal complications and to determine the surgical decision<sup>4</sup>. However, the clinical presentation of patients with SBI is usually nonspecific and includes abdominal symptoms such as vomiting and abdominal pain, which may appear in other acute abdominal diseases. Ko et al<sup>2</sup> reported that, among patients with SBI, 86% had vomiting, 86% had pain and crying, and 26% had bloody stool. The corresponding rates in the present study were 86%, 83%, and 19%, respectively. Because most patients with SBI present with nonspecific symptoms, they should be evaluated radiologically.

USS, as a noninvasive and inexpensive diagnostic tool, is readily available and, because of its high sensitivity and specificity, the preferred imaging method in patients with suspected SBI<sup>2,4,9,10,16</sup>. However, it may not be possible to distinguish SBIs from ileocolic intussusceptions by USS in all cases<sup>2,4,6,11,17,18</sup>. Zhang et al. 6 reported paraumbilical and left quadrant locations in 47% of the patients with surgically proven SBI. In our patient series, the invaginated segment was in the paraumbilical and left quadrant zones in 19 (56%) patients, which is in line with cases reported in the literature. Nonetheless, a right abdominal quadrant location, as occurs with ileocolic intussusception, may also be seen. As a matter of fact, this rate was % 44 in our study. Therefore, location of the invaginated segment may not be sufficient for the SBI.

In a previous study of the associations of the invaginated segment diameter and length in SBI using USS with the requirement for any surgical procedure, the rate of undergoing surgery in patients was significantly related to an invaginated segment length > 4.2 cm and

diameter > 2.1 cm 6. Similarly, in a study of 35 adult and pediatric patients, Munden et al.<sup>11</sup> concluded that a segment length of  $\geq 3.5$  cm is a strong indicator for surgical treatment. All of the patients enrolled in our study underwent surgery; the mean diameter and length of the invaginated segment were 3 ( $\pm 1$ ) cm and 6.7 ( $\pm 3$ ) cm, respectively. Additionally, a positive correlation was detected between patient age and the diameter of the invaginated segment, as well as between symptom duration and the length of the invaginated segment. As these parameters may affect differential diagnosis and surgical necessity, the age of the patient and the duration of symptoms should be considered during USS evaluation.

Contrary to the effectiveness of enema reduction in ileocolic intussusception, its effectiveness in patients with SBI is still controversial<sup>1,6,9</sup>. Although Saxena et al.<sup>1</sup> reported successful enema reduction in 75% (n=7) of patients in their series, Zhang et al. 6 reported successful enema reduction in one (20%) of five patients; that patient underwent surgery because of relapse. Koh et al. 9 reported that had failed in all patients. They suggest that failure may be caused by ileocecal valve resistance and distance of intussusception from the ileocecal valve. Enema reduction was performed in 27 patients in the present study, 2 (7%) of whom had successful. However, these two patients underwent surgery for similar reasons upon detection of an intussusceptions after 2 days, and the etiology was a PLP in both patients. Therefore, we think that enema reduction may be a helpful diagnostic tool in the exclusion of ileocolic invaginations rather than the treatment of SBIs.

An underlying pathological lead point should often be investigated in SBIs<sup>7,15</sup>. Koh et al.<sup>9</sup> detected a PLP in five (83%) of six patients with SBI, while Ko et al.<sup>2</sup> found a PLP in 8 (42%). In contrast, Kornecki et al.<sup>17</sup> did not detect a PLP, including in patients who underwent surgery. In

our study, PLP was detected in 19 (53%) patients, and Meckel's diverticulum was found in 74% of them. Of the patients with PLP, 84% were older than 1 year. Therefore, the presence of SBI and concomitant PLP should be kept in mind in patients older than 1 year.

Patients with SBI may experience severe bowel complications such as ischemia, necrosis and perforation, depending on the duration. As a matter of fact, Koh et al.<sup>9</sup> encountered such complications in 66% of the patients, whereas this rate was 42% in the series of Ko et al.<sup>2</sup> In our study, 13(36%) patients underwent resection anastomosis due to necrosis and perforation and 1 (3%) patient died due to sepsis. Therefore, we think that early diagnosis and treatment is very important in SBI.

While laparotomy was the previously preferred surgical treatment for SBI, in recent years, laparoscopy has been used for diagnostic and therapeutic purposes<sup>19,20</sup>. Apelt et al.<sup>21</sup> reviewed the literature on 276 patients in their assessment of the efficiency of laparoscopy in pediatric intussusception and reported successful treatment of 196 (71%) patients. However, the remaining 29% patients required open surgery because of unsuccessful reduction, existence of a lead point, and perforation. In the presented series, 10 patients were treated laparoscopically in the last period. Extracorporeal resection was performed in half of these patients due to the presence of PLP, but laparotomy was not required. These results suggest that laparoscopy may be used reliably and successfully in both the diagnosis and the treatment of pediatric SBI.

Our study had some limitations. There was no pediatric radiologist in our hospital. USS is performed by different radiologists under emergency conditions. Another limitation was that we did not make a comparison with ileocolic intussusception.

In conclusion, the location of the invaginated segment in the USS can guide the differential diagnosis of SBI. However, SBIs may also be localized in the right lower quadrant of the abdomen. Therefore, enema reduction with USG may be a helpful diagnostic tool to exclude ileocolic intussusceptions rather than treating SBIs. The length and diameter of the invaginated segment are decisive in the surgical decision of SBI. There is usually a PLP in the etiology of SBI, and the most common cause in our series was Meckel's diverticulum. Laparoscopy appears to be a less invasive and effective option for the surgical treatment of SBIs in children.

**Ethics Committee Approval:** Ethics committee approval was received from the Ethics Committee of Dicle University (Ethics Committee No:163/09.06.2022).

**Conflict of Interest:** The authors declared no conflicts of interest.

**Financial Disclosure:** The authors declared that this study has received no financial support.

## REFERENCES

1. Saxena AK, Seebacher U, Bernhardt C, et al. Small bowel intussusceptions: Issues and controversies related to pneumatic reduction and surgical approach. *Acta Paediatr.* 2007; 96: 1651–4.
2. Ko SF, Lee TY, Ng SH, et al. Small bowel intussusception in symptomatic pediatric patients: Experiences with 19 surgically proven cases. *World J Surg.* 2002; 26: 438–43.
3. Sivit CJ. Gastrointestinal emergencies in older infants and children. *Radiol Clin North Am.* 1997; 3: 865–77.
4. Tiao MM, Wan YL, Ng SH, et al. Sonographic features of small-bowel intussusception in pediatric patients. *Acad Emerg Med.* 2001; 8: 368–73.
5. Daneman, A. Alton D. Intussusception. Issues and controversies related to diagnosis and reduction. *Radiol Clin North Am.* 1996; 34: 743–56.

6. Zhang Y, Bai YZ, Li SX, et al. Sonographic findings predictive of the need for surgical management in pediatric patients with small bowel intussusceptions. *Langenbeck's Arch Surg.* 2011; 396: 1035–40.
7. Vafaeimanesh, J. (2019). Intussusception in pregnancy caused by Ascariasis; Report of a rare case. *Govaresh.* 2019; 24: 247-49.
8. Kocaman OH, Günendi T. Different clinical symptoms and surgical treatment of Meckel's diverticulum in children. *Dicle Med J.* 2022; 49: 21-28
9. Koh EPK, Chua JHY, Chui CH, et al. A report of 6 children with small bowel intussusception that required surgical intervention. *J Pediatr Surg.* 2006; 41: 817–20.
10. Rajagopal R, Mishra N, Yadav N, et al. Transient versus surgically managed small bowel intussusception in children: Role of ultrasound. *African J Paediatr Surg.* 2015; 12: 140–2.
11. Kim JH. US features of transient small bowel intussusception in pediatric patients. *Korean J Radiol.* 2004; 5: 178–84.
12. Munden MM, Bruzzi JF, Coley BD, et al. Sonography of pediatric small-bowel intussusception: Differentiating surgical from nonsurgical cases. *Am J Roentgenol.* 2007; 188: 275–9.
13. Wiersma F, Allema JH, Holscher HC. Ileoileal intussusception in children: Ultrasonographic differentiation from ileocolic intussusception. *Pediatr Radiol.* 2006; 36: 1177–81.
14. Flaum V, Schneider A, Ferreira GC, et al. Twenty years' experience for reduction of ileocolic intussusceptions by saline enema under sonography control. *J Pediatr Surg.* 2016; 51: 179–82.
15. Khasawneh R, El-Heis M, Al-Omari M, et al. The radiological characteristics of childhood intussusception including unusual features and rare pathological lead points. *Heliyon.* 2021; 7: e07231.
16. Del-Pozo G, Albillos JC, Tejedor D, et al. Intussusception in children: Current concepts in diagnosis and enema reduction. *Radiographics.* 1999; 19: 299–319.
17. Kornecki A, Daneman A, Navarro O, et al. Spontaneous reduction of intussusception: Clinical spectrum, management and outcome. *Pediatr Radiol.* 2000; 30: 58–63.
18. Zhang M, Zhou X, Hu Q, et al. Accurately distinguishing pediatric ileocolic intussusception from small-bowel intussusception using ultrasonography. *J Pediatr Surg.* 2021; 56: 721–6.
19. Sklar CM, Chan E, Nasr A. Laparoscopic versus open reduction of intussusception in children: A retrospective review and meta-analysis. *J Laparoendosc Adv Surg Tech.* 2014; 24: 518–22.
20. Li N, Bao Q, Yuan J, et al. Open transumbilical intussusception reduction in children: A prospective study. *J Pediatr Surg.* 2021; 56: 597–600.
21. Apelt N, Featherstone N, Giuliani S. Laparoscopic treatment of intussusception in children: a systematic review. *J Pediatr Surg.* 2013; 48: 1789–93.