

# COMPARING THE TRAJECTORY ACCURACY OF PEDICLE SCREWS PLACED WITH A FREE-HAND TECHNIQUE AND A THREE-DIMENSIONAL COMPUTED TOMOGRAPHY-ASSISTED NAVIGATION SYSTEM IN SPINE SURGERY: A RETROSPECTIVE STUDY

OMURGA CERRAHİSİNDE SERBEST EL TEKNİĞİ VE ÜÇ BOYUTLU BİLGİSAYARLI TOMOGRAFİ DESTEKLİ NAVİGASYON SİSTEMİYLE YERLEŞTİRİLEN PEDİKÜL VIDALARININ YÖNELİM DOĞRULUĞUNUN KARŞILAŞTIRILMASI: RETROSPEKTİF ÇALIŞMA

Eyyüp ÇETİNER<sup>1</sup> , Selcan AKESAN<sup>2</sup> , Yücel BİLGİN<sup>3</sup> , Cem ÖNDER<sup>4</sup> , Saltuk Buğra GÜLER<sup>3</sup> , Burak AKESAN<sup>3</sup> 

<sup>1</sup>Siirt Education and Research Hospital, Orthopedics and Traumatology Clinics, Siirt, Türkiye

<sup>2</sup>Bursa Uludağ University, Faculty of Medicine, Department of Anesthesiology and Reanimation, Bursa, Türkiye

<sup>3</sup>Bursa Uludağ University, Faculty of Medicine, Department of Orthopedics and Traumatology, Bursa, Türkiye

<sup>4</sup>Abdulkadir Yüksel State Hospital, Orthopedics and Traumatology Clinics,, Gaziantep, Türkiye

**ORCID IDs of the authors:** E.Ç. 0000-0002-0371-5461; S.A. 0000-0002-9518-541X; Y.B. 0000-0003-0433-1918; C.Ö. 0000-0002-8289-8867; S.B.G. 0000-0002-4324-4844; B.A. 0000-0002-8679-6008

**Cite this article as:** Cetiner E, Akesen S, Bilgin Y, Onder C, Guler SB, Akesen B. Comparing the trajectory accuracy of pedicle screws placed with a free-hand technique and a three-dimensional computed tomography-assisted navigation system in spine surgery: a retrospective study. J Ist Faculty Med 2023;86(2):138-144. doi: 10.26650/IUITFD.1198451

## ABSTRACT

**Objective:** We evaluated a free-hand technique and a three-dimensional computerized tomography (3D-CT)-assisted navigation technique, which are pedicle screw placement techniques used in spinal surgery, regarding screw placement and reliability.

**Materials and Methods:** A total of 1664 screws in 73 patients with spinal deformities who underwent spinal instrumentation using pedicle screws were evaluated in this study. Forty patients were in the free-hand technique group, and 33 patients were in the 3D-CT-assisted navigation technique group. The placement and reliability of pedicle screws in all patients were evaluated using the Gertzbein–Robbins classification using CT images taken in the postoperative period.

**Result:** There were no significant differences found regarding age, body mass index (BMI), sex (female or male), or deformity (scoliosis or kyphosis) ( $p>0.05$ ). When the pedicle screws were evaluated in terms of transverse penetration, the 3D-CT-assisted navigation technique was determined Grade A (89.6%), as was the free-hand technique (76.5%), but the 3D-CT-assisted navi-

## ÖZET

**Amaç:** Spinal cerrahide kullanılan pedikül vida yerleştirme tekniklerinden serbest el tekniği ve üç boyutlu bilgisayarlı tomografi (3D-BT) destekli navigasyon tekniği, vida yerleştirme ve güvenilirlik açısından karşılaştırıldı.

**Gereç ve Yöntem:** Pedikül vidası ile spinal enstrümantasyon uygulanan 73 spinal deformiteli hastanın toplam 1664 vidası çalışmada değerlendirildi. Serbest el tekniği grubunda 40 hasta ve 3D-BT destekli navigasyon tekniği grubunda 33 hasta vardı. Pedikül vidalarının tüm hastalarda yerleştirilmesi ve güvenilirliği, ameliyat sonrası dönemde çekilen BT görüntüleri kullanılarak Gertzbein-Robbins sınıflaması kullanılarak değerlendirildi.

**Bulgular:** Yaş, vücut kitle indeksi (VKİ), cinsiyet (kadın veya erkek) ve deformite (skolyoz veya kifoz) açısından gruplar arası anlamlı fark bulunmadı ( $p>0,05$ ). Pedikül vidaları transvers penetrasyon açısından değerlendirildiğinde, 3D-BT destekli navigasyon tekniğinde Grade A (%89,6), serbest el tekniğinde Grade A (%76,5) olarak belirlendi. 3D-BT destekli navigasyon tekniği trasvers penetrasyon açısından istatistiksel olarak daha güvenilir tespit edil-

**Corresponding author/İletişim kurulacak yazar:** Eyyüp ÇETİNER – dr\_eyyup@hotmail.com

**Submitted/Başvuru:** 03.11.2022 • **Revision Requested/Revizyon Talebi:** 22.11.2022 •

**Last Revision Received/Son Revizyon:** 23.02.2023 • **Accepted/Kabul:** 28.02.2023 • **Published Online/Online Yayın:** 28.03.2023



Content of this journal is licensed under a Creative Commons Attribution-NonCommercial 4.0 International License.

gation technique was statistically more reliable ( $p<0.001$ ). When the pedicle screws were evaluated in terms of anterior penetration, both the 3D-CT-assisted navigation technique (92.5%) and the free-hand technique (82.9%) were determined Grade A, but the 3D-CT-assisted navigation technique was statistically more reliable ( $p<0.001$ ).

**Conclusion:** According to our study's results, the 3D-CT-assisted navigation technique is more reliable than the free-hand technique in surgeries involving spine deformities for pedicle screw insertion.

**Keywords:** Spine deformity, navigation, posterior instrumentation

di ( $p<0,001$ ). Pedikül vidaları anterior penetrasyon açısından değerlendirildiğinde, hem 3D-BT yardımcı navigasyon tekniğinde Grade A (%92,5) ve serbest el tekniğine Grade A (%82,9) olarak belirlendi. 3D-BT yardımcı navigasyon tekniği anterior penetrasyon açısından istatistiksel olarak daha güvenilir tespit edildi ( $p<0,001$ ).

**Sonuç:** Çalışmamızın sonuçlarına göre, omurga deformitelerini içeren ameliyatlarda pedikül vidası yerleştirmede 3D-BT destekli navigasyon tekniği serbest el tekniği ile karşılaştırıldığında daha güvenilirirdir.

**Anahtar Kelimeler:** Omurga deformitesi, navigasyon, posterior enstrümantasyon

## INTRODUCTION

The first posterior spinal fusion surgery was performed by Hibbs in 1911 (1). In the 1950s, Harrington started a new period in posterior spinal instrumentation by developing a hook and rod system that could perform traction and compression (2). By the 1990s, pedicle screws were being used in posterior spinal instrumentation.

Pedicle screw placement techniques are divided into free-hand techniques and imaging-guided techniques. In the free-hand technique, pedicle screws are placed using the pedicle probe, taking into account the spine anatomy and various anatomical landmarks. The freehand technique requires detailed preoperative planning. This technique has a higher learning curve that can be achieved with higher practice (3). There are two types of imaging-guided techniques: fluoroscopy-guided and navigation-guided. In the fluoroscopy-guided technique, the most important advantages are the control of the screw entry site and the screw delivery axis. However, it is a disadvantage that the imaging can be done in 2 plans. 3D imaging and cross-sectional imaging provide additional advantages in the navigation-guided technique. Ughwanogho et al. evaluated the placement accuracy of 485 thoracic pedicle screws and found significantly less unsafe screw placement with the navigation technique compared to the free-hand technique (4).

In this study, we aimed to compare the accuracy of pedicle screw insertion using both a free-hand technique and an intraoperative 3D-CT-assisted navigation system in patients undergoing posterior spinal instrumentation due to deformity.

## MATERIALS and METHODS

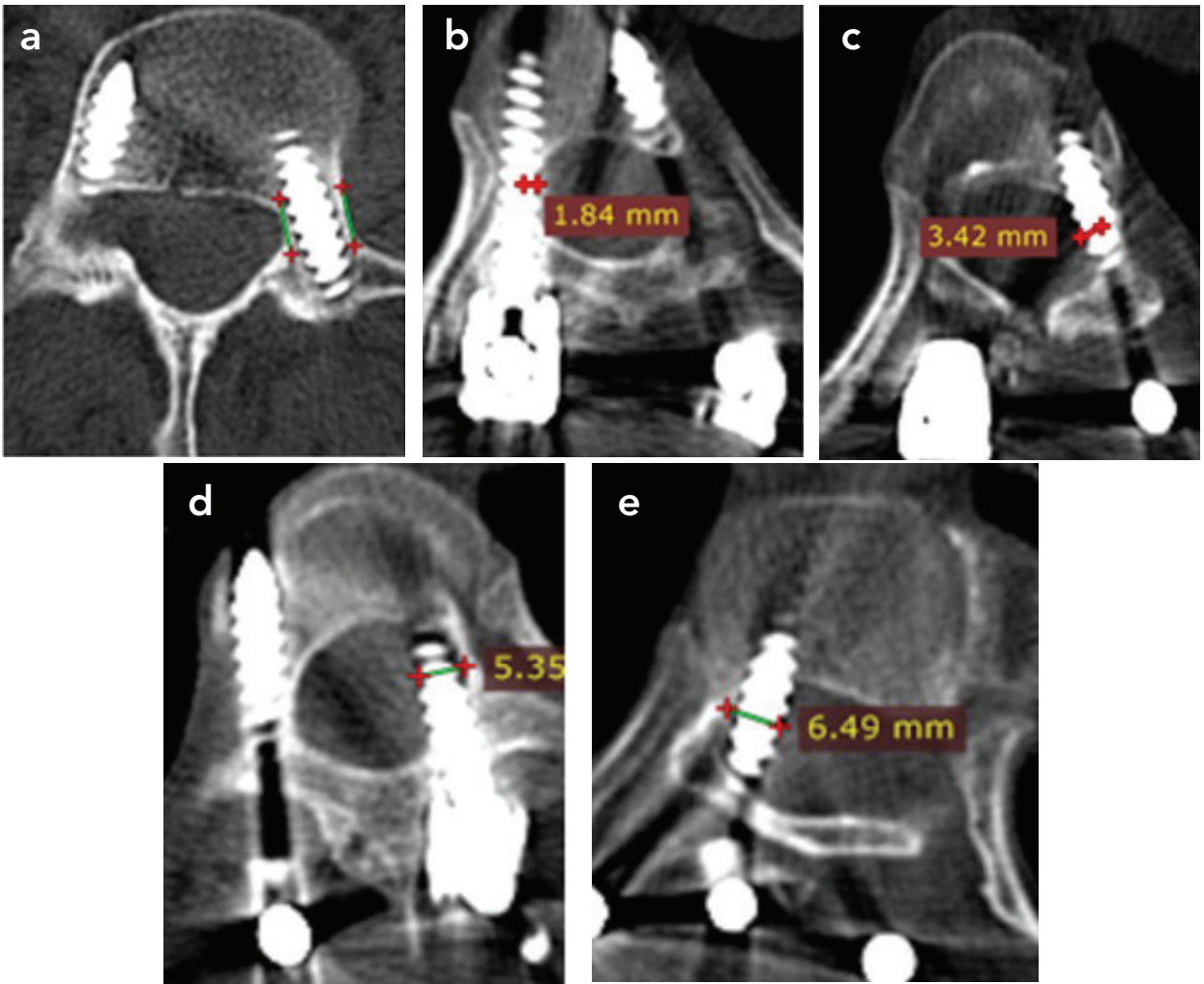
### Patient selection

In inclusion criteria for the study, it was determined that the patient had been operated on for scoliosis or kyphosis, the main curvature was 40 degrees and above in scoliosis patients, the Cobb angle was 70 degrees and above in

kyphosis patients, the patient had a CT scan taken for fusion control in the postoperative one year, and the patient consented to participate in the study. In exclusion criteria from the study, it was determined that the patient had been operated on with diagnoses other than kyphosis or scoliosis, surgeries performed for cosmetic purposes, and the patient did not consent to participate in the study. Seventy-three patients who underwent surgery in our clinic to correct a spinal deformity (scoliosis or kyphosis) between January 2017 and December 2018 were retrospectively included in the study. Informed consent was obtained from all participants. The ethics committee approved the study (Date:15.01.2019, No:2019-1/34), which was conducted as a thesis of specialization in medicine (Number: 536843). The patients were grouped according to their surgeries' pedicle screw placement technique: 33 patients were in the 3D-CT-assisted navigation technique group (the Nav group), and 40 patients were in the free-hand technique group (the F-H group). As an adjunct, all patients' sensory- and motor-evoked potentials were monitored.

### Methods

The patients' postoperative 1-year CT images were evaluated using a picture archiving and communication system (PACS). The evaluation was performed separately for cases of transverse penetration of the pedicle (medial or lateral) and penetration of the vertebral corpus (anterior). Screw penetration was graded according to the Gertzbein–Robbins classification (Figure 1a, b, c, d, e) (5-6). The thoracolumbar spine was divided into 4 regions: upper thoracic, mid-thoracic, lower thoracic, and lumbosacral regions. The thoracic spine was divided into three anatomical regions and examined. It was defined as the upper thoracic region between the T1-T4 vertebrae, the mid-thoracic region between the T5-T8 vertebrae, and the lower thoracic region between the T9-T12 vertebrae. All CT scan evaluations were performed by a single orthopedic surgeon. In addition, age, body mass index (BMI), and gender data were recorded from epidemiological data.



**Figure 1:** a) Gertzbein ve Robins classification Grade A: any penetration b) Gertzbein ve Robins classification Grade B: <2 mm. c) Gertzbein ve Robins classification Grade C: 2-4 mm d) Gertzbein ve Robins classification Grade D: 4-6 mm e) Gertzbein ve Robins classification Grade E>6 mm

### Surgical techniques

During spinal surgery, all patients lay in the prone position on radiolucent operating tables. Soft pads were placed under their chests and shoulders. All patients had undergone prophylaxes for infection and venous thromboembolism. Intravenous tranexamic acid and intracutaneous and subcutaneous epinephrine were used to reduce blood loss in patients without contraindication (7-8). A midline incision was used in all patients (8).

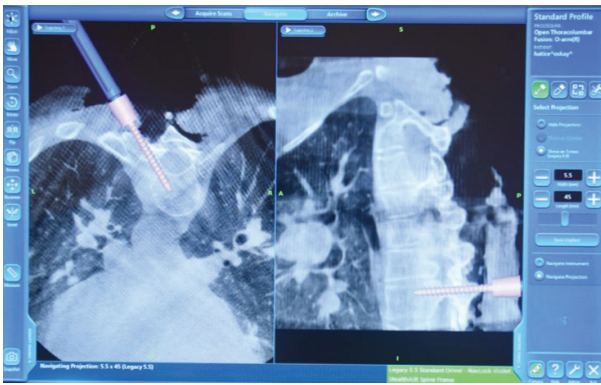
In the Nav group, a reference frame was placed in one of the spinous processes for spinal navigation after opening. Then, a CT scan was acquired, and intraoperative CT images were processed and transferred to the navigation system. Screw length, diameter, entry point, and trajectory were dictated by the navigation system. After the screw entry point was determined, it was pierced using a straight awl. With the assistance of navigation, pedicle

screws of appropriate length and diameter were inserted, the placement of which was checked on the navigation monitor (Figure 2).

In the F-H group, pedicle screw placement was performed according to Roy-Camille et al.'s technique (9). After the screw entry point was determined, it was pierced with a straight awl. The depth was checked using a probe. Then, pedicle screws of appropriate length and diameter were placed. After all screws had been inserted, fluoroscopy was used to adjust the position of the screws.

### Postoperative management

Respiratory physiotherapy was started immediately after surgery. On the 1<sup>st</sup> postoperative day, the drains of all patients were removed, the patients were mobilized, and physiotherapy was started. Antibiotic prophylaxis was administered to the patients for 24 hours postoperatively (Cefazolin sodium). Deep vein thrombosis prophylax-



**Figure 2:** The insertion of pedicle screw under the navigation guidance

is was applied to the patients for 21 days (Antibiotic stockings and enoxaparin sodium 4000IU 1x1). A dressing was applied to the patients every two days, and sutures were removed on the 14<sup>th</sup> postoperative day. The patients were followed up with x-rays on the 15<sup>th</sup> day, 1<sup>st</sup> month, 3<sup>rd</sup> month, 6<sup>th</sup> month, and 1<sup>st</sup> year, and a CT scan was performed for fusion control in all patients in the postoperative 1<sup>st</sup> year.

### Statistical analysis

Statistical analysis was performed using SPSS ver. 22.0 (IBM Corp., Armonk, NY). Number and percentage values from the descriptive data were used. Whether the data fit the normal distribution was checked with the Kolmogorov-Smirnov test. An independent sample T-test was used to compare parametric data. Pearson's chi-squared and Yate's corrected chi-squared tests were used to compare categorical data. The accepted degree of statistical significance was  $p < 0.05$ .

## RESULTS

The differences in characteristics between the two groups were compared. There were no significant differences found regarding age, body mass index (BMI), sex (female or male), or deformity (scoliosis or kyphosis) ( $p > 0.05$ ) (Table 1). No decrease in sensory- and motor-evoked potentials was observed in all patients in both groups on peroperative neuromonitoring.

At the T1–S1 vertebral level, 962 screws in the F-H group and 702 screws in the Nav group were inserted. Both groups used the least number of screws, 2, in T1. The largest number of screws inserted in one place was 56 in the F-H group (T3) and 72 in the Nav group (T12).

### Transverse penetration

According to the Gertzbein–Robbins classification for transverse penetration, 1365 screws were Grade A, and 299 were non-Grade A (Grade B, C, D, E) (Table 2). The Nav group showed more accuracy (Grade A: 89.6%) than the F-H group did (Grade A: 76.5%), a finding that was

statistically significant ( $p < 0.05$ ). There were 299 screws with transverse penetration (not Grade A): 179 were medial (59.9%), and 120 were lateral (40.1%). There were no significant differences found in either group regarding screw direction ( $p > 0.05$ ) (Table 3).

Three regions make up the thoracic vertebrae, depending on pedicle size: upper, mid, and lower. The Nav group showed more accuracy than the F-H group in each thoracic region, as well as the lumbosacral region ( $p < 0.05$ ). In the F-H group, screws placed in the lumbosacral region were the most accurate ( $p < 0.05$ ). In the Nav group, no significant differences were found ( $p > 0.05$ ) (Table 4).

### Anterior penetration

According to the Gertzbein–Robbins classification for anterior penetration, 1495 screws were Grade A, and 169 were non-Grade A (Grade B, C, D, E) (Table 5). The Nav group had more accuracy (Grade A: 92.5%) than the F-H group did (Grade A: 87.9%), a finding that was statistically significant ( $p < 0.05$ ). The Nav group showed more accuracy than the F-H group in the upper thoracic region, but there were no differences in the other regions ( $p < 0.05$ ). In the F-H group, screws placed in the lower thoracic region were the most accurate ( $p < 0.05$ ). In the Nav group, the lower thoracic and lumbosacral regions had more accurate placements than the other regions ( $p > 0.05$ ) (Table 6).

## DISCUSSION

Several studies in the literature have compared the 3D-CT-assisted navigation technique with various other techniques (fluoroscopy, 2D navigation, preop BT navigation, and robotics), while others have evaluated the penetration rates of this technique directly (5). Most of those involved in the research have been trauma patients, but some were patients with lumbar degeneration. Publications that compare free-hand and 3D-CT-assisted navigation techniques in patients with spinal deformities are limited; therefore, the difference between the two techniques is not clear (10).

Jin et al. compared screw placements performed with the free-hand and 3D-CT-assisted navigation techniques in patients with neurofibromatosis type I scoliosis at the apical regions of the deformity (11). Screw positions were evaluated according to the Gertzbein–Robbins classification. Penetration of Grades C, D, and E was accepted. In the free-hand group, transverse penetration was 32% (14% medial and 18% lateral), and anterior penetration was 1%. In the 3D-CT-assisted navigation group, transverse penetration was 18% (2% medial and 16% lateral), and anterior penetration was 3%. In our study, the anterior penetration rates were higher. Also, while Jin et al. documented more lateral than medial penetrations, we



**Table 1:** Group demographics and deformities

		F-H Group n (%)	Nav Group n (%)	p value
<b>Gender</b>	Male	19 (47.5)	12 (36.4)	0.471
	Female	21 (52.5)	21 (63.6)	
<b>Deformity</b>	Kyphosis	9 (22.5)	4 (12.1)	0.397
	Scoliosis	31 (77.5)	29 (87.9)	
<b>BMI</b>	<25 kg/m <sup>2</sup>	24 (60)	22 (66.7)	0.731
	>25 kg/m <sup>2</sup>	16 (40)	11 (33.3)	
<b>Age</b>	<18	19 (47.5)	19 (57.6)	0.534
	>18	21 (52.5)	14 (42.4)	

BMI: Body mass index, F-H: Free-hand, Nav: Navigation

**Table 2:** Quantity of screws with transverse penetration and penetration rates in each group

	F-H Group n (%)	Nav Group n (%)	p value
<b>A</b>	736 (76.5)	629 (89.6)	0.000
<b>B</b>	116 (12.1)	39 (5.6)	
<b>C</b>	59 (6.1)	14 (2)	
<b>D</b>	39 (4.1)	11 (1.6)	
<b>E</b>	12 (1.2)	9 (1.3)	
<b>Total</b>	<b>962</b>	<b>702</b>	

F-H: Free-hand, Nav: Navigation

**Table 3:** Quantity of screws with transverse penetration and penetration rates in each group, categorized by direction

	F-H Group n (%)	Nav Group n (%)	p value
<b>Medial</b>	134 (59.3)	45 (61.6)	0.722
<b>Lateral</b>	92 (40.7)	28 (38.4)	

F-H: Free-hand, Nav: Navigation

**Table 5:** Quantity of screws with anterior penetration and penetration rates in each group

	F-H Group n (%)	Nav Group n (%)	p value
<b>A</b>	846 (87.9)	649 (92.5)	0.000
<b>B</b>	89 (9.3)	21 (3.4)	
<b>C</b>	17 (1.8)	15 (2.1)	
<b>D</b>	6 (0.6)	7 (1)	
<b>E</b>	4 (0.4)	7 (1)	
<b>Total</b>	<b>962</b>	<b>702</b>	

F-H: Free-hand, Nav: Navigation

found no significant difference regarding penetration orientation in our study (11).

Although Zhao et al. used a different classification system when evaluating scoliosis patients' screw positions (i.e., Grade 0: no penetration, Grade 1: <1 mm penetration, Grade 2: 1–3 mm penetration, and Grade 3: >3 mm penetration), they did compare the free-hand and 3D-CT-assisted navigation techniques (12). Allowing Grades 2 and 3 to be accepted as penetration, the penetration rate

**Table 4:** Quantity of screws with transverse penetration and penetration rates, categorized by vertebral region

Region	Group	Grade A n (%)	Grade B,C,D,E n (%)	p value
<b>Upper Thoracic</b>	F-H Group	91 (71.1)	37 (28.9)	0.002
	Nav Group	122 (87)	18 (12.9)	
<b>Mid Thoracic</b>	F-H Group	179 (69.1)	80 (30.9)	0.000
	Nav Group	156 (87.2)	23 (12.8)	
<b>Lower Thoracic</b>	F-H Group	210 (76.6)	64 (23.4)	0.000
	Nav Group	160 (92)	14 (8)	
<b>Lumbosacral</b>	F-H Group	256 (85)	45 (15)	0.045
	Nav Group	191 (91.4)	18 (8.6)	

F-H: Free-hand, Nav: Navigation

**Table 6:** Quantity of screws with anterior penetration and penetration rates, categorized by vertebral region

Region	Group	Grade A n (%)	Grade B, C, D, E n (%)	p value
Upper Thoracic	F-H Group	90 (70.3)	38 (29.7)	0.002
	Nav Group	121 (86.4)	19 (13.6)	
Mid Thoracic	F-H Group	220 (84.9)	39 (15.1)	0.080
	Nav Group	163 (91.1)	16 (8.9)	
Lower Thoracic	F-H Group	260 (94.9)	14 (5.1)	0.763
	Nav Group	167 (96)	7 (4)	
Lumbosacral	F-H Group	276 (91.7)	25 (8.3)	0.116
	Nav Group	198 (95.7)	9 (4.3)	

F-H: Free-hand, Nav: Navigation

was 18.4% using the free-hand technique and 12.1% using 3D-CT-assisted navigation. Zhao et al. also reported that the rate of pulmonary effusion was higher in the free-hand technique group (12).

Qiao et al. compared free-hand and 3D-CT-assisted navigation techniques when placing screws in patients with scoliosis due to Marfan syndrome (13). Pedicle screw placements were categorized according to the Gertzbein–Robbins classification. Unlike our and others' studies, Qiao et al. reported that, regarding all screws, penetration rates in the thoracic vertebrae were lower than in the lumbar vertebrae (22.3% and 34.1%, respectively) (13). They hypothesized that this difference could be explained by the fact that those with Marfan syndrome have thinner pedicles in the lumbar vertebrae. When comparing surgical techniques, the study's results showed that 3D-CT-assisted navigation (11.4%) was more successful than free-hand (30.8%).

Urbanski et al. researched screw placement in patients with idiopathic scoliosis and found no significant difference between the penetration rates of the 3D-CT-assisted navigation technique group (17.97%) and the free-hand technique group (17.08%) (10). They also found that in both groups, the highest penetration rate was in the upper thoracic region.

Mobile CT device is used in 3D-CT-assisted navigation systems. These devices can never reach the resolutions of conventional CT devices. Therefore, mal-

positions can be seen even in pedicle screws placed with a 3D-CT-assisted navigation system. Therefore, in our study group, all patients were examined in terms of screw malposition using postoperative conventional CT methods. Screw malpositions that could not be detected in preoperative CT were detected with conventional CT.

There are some limitations to our study. First, a radiologist was not involved in the study; all radiological evaluations were performed by an orthopedic surgeon specializing in spine surgery. In addition, interobserver and intraobserver reliability were not evaluated in the study. Second, only anatomical evaluations were performed (i.e., the effects of the surgeries on the patients were not evaluated), and pedicle screw malposition does not always cause problems in the clinic. In addition, the small number of samples and the lack of power analysis are other limitations of the study.

## CONCLUSION

In our study, the 3D-CT-assisted navigation technique demonstrated lower transverse and anterior penetration rates compared to the free-hand technique at all levels. Also, no significant difference was found between medial and lateral transverse penetration orientations.

**Ethics Committee Approval:** This study was approved by Uludag University Faculty of Medicine Clinical Research Ethics Committee (Date:15.01.2019, No:2019-1/34).

**Peer Review:** Externally peer-reviewed.

**Author Contributions:** Conception/Design of Study- E.Ç., B.A.; Data Acquisition- E.Ç., C.Ö., S.B.G., B.A.; Data Analysis/Interpretation- E.Ç., S.A., Y.B., B.A.; Drafting Manuscript- E.Ç., C.Ö., S.B.G.; Critical Revision of Manuscript- S.A., Y.B., B.A.; Final Approval and Accountability- E.Ç., S.A., Y.B., C.Ö., S.B.G., B.A.;

**Conflict of Interest:** The authors have no conflict of interest to declare.

**Financial Disclosure:** The authors declared that this study has received no financial support.

## REFERENCES

- Serhan H, Kuhn M. The history of spinal deformity. *Ann Orthop Rheumatol* 2016;4(3):1072. [CrossRef]
- Harrington PR. Treatment of scoliosis. Correction and internal fixation by spinal instrumentation, *J Bone Joint Surg Am* 1962;44-A:591-610. [CrossRef]
- Perna F, Borghi R, Pilla F, Stefanini N, Mazzotti A, Chehrassan M. Pedicle screw insertion techniques: an update and review of the literature. *Musculoskelet Surg* 2016;100(3):165-9. [CrossRef]
- Ughwanogho E, Patel NM, Baldwin KD, Sampson NR, Flynn

- JM. Computed tomography-guided navigation of thoracic pedicle screws for adolescent idiopathic scoliosis results in more accurate placement and less screw removal. *Spine (Phila Pa 1976)* 2012;37(8):E473-8. [\[CrossRef\]](#)
5. Kosmopoulos V, Schizas C. Pedicle screw placement accuracy: a meta-analysis. *Spine (Phila Pa 1976)* 2007;32(3):E111-20. [\[CrossRef\]](#)
  6. Gertzbein SD, Robbins SE. Accuracy of pedicular screw placement in vivo. *Spine (Phila Pa 1976)* 1990;15(1):11-4. [\[CrossRef\]](#)
  7. Farrokhi MR, Kazemi AP, Eftekharian HR, Akbari K. Efficacy of prophylactic low dose of tranexamic acid in spinal fixation surgery: a randomized clinical trial. *J Neurosurg Anesthesiol* 2011;23(4):290-6. [\[CrossRef\]](#)
  8. Barney LF. Scoliosis and kyphosis. In: Canale ST, Beaty JH, editors. *Campbell's Operative Orthopaedics* 11. Edition, Philadelphia: Mosby 2008, p1944-5.
  9. Roy-Camille R, Saillant G, Mazel C. Internal fixation of the lumbar spine with pedicle screw plating. *Clin Orthop Relat Res* 1986;(203):7-17. [\[CrossRef\]](#)
  10. Urbanski W, Jurasz W, Wolanczyk M, Kulej M, Morasiewicz P, Dragan SL, et al. Increased radiation but no benefits in pedicle screw accuracy with navigation versus a freehand technique in scoliosis surgery. *Clin Orthop* 2018;476(5):1020-27. [\[CrossRef\]](#)
  11. Jin M, Liu Z, Liu X, Yan H, Han X, Qiu Y, et al. Does intraoperative navigation improve the accuracy of pedicle screw placement in the apical region of dystrophic scoliosis secondary to neurofibromatosis type I: comparison between O-arm navigation and free-hand technique. *Eur Spine J* 2016;25(6):1729-37. [\[CrossRef\]](#)
  12. Zhao Z, Liu Z, Hu Z, Tseng C, Li J, Pan W, et al. Improved accuracy of screw implantation could decrease the incidence of post-operative hydrothorax? O-arm navigation vs. free-hand in thoracic spinal deformity correction surgery. *Int Orthop* 2018;42(9):2141-6. [\[CrossRef\]](#)
  13. Qiao J, Zhu F, Xu L, Liu Z, Sun X, Qian B, et al. Accuracy of pedicle screw placement in patients with Marfan syndrome. *BMC Musculoskelet Disord* 2017;18(1):123. [\[CrossRef\]](#)