

# Comparison of diagnostic methods in onychomycosis

✉ Ece Altun<sup>1</sup>, ✉ Elif Kuzucular<sup>2</sup>, ✉ Ayşe İstanbullu Tosun<sup>3</sup>

<sup>1</sup>Department of Dermatology and Venereology, School of Medicine, İstanbul Medipol University, İstanbul, Turkey

<sup>2</sup>Department of Medical Pathology, School of Medicine, İstanbul Medipol University, İstanbul, Turkey

<sup>3</sup>Department of Medical Microbiology, School of Medicine, İstanbul Medipol University, İstanbul, Turkey

**Cite this article as:** Altun E, Kuzucular E, İstanbullu Tosun A. Comparison of diagnostic methods in onychomycosis. J Health Sci Med 2023; 6(2): 353-358.

## ABSTRACT

**Aim:** Onychomycosis is a chronic fungal infection of the nail bed, plate, or matrix. This study aimed to compare the sensitivity of three diagnostic methods in the diagnosis of onychomycosis.

**Material and Method:** This study included 39 patients with a clinical diagnosis of onychomycosis of the toenails, who presented to Medipol Mega University Hospital between May 2019 and August 2022. Using the nail samples taken from the patients, the results of the direct microscopic examination with standard potassium hydroxide (KOH), histopathological examination performed with periodic acid-Schiff (PAS) staining, and fungal agents that grew in fungal culture were noted.

**Results:** Eleven (28.2%) patients were female, and 28 (71.8%) were male, with the mean age being 43.1±13.9 years. Of the patients, 53.8% had distal subungual onychomycosis and 46.2% had total subungual onychomycosis. The mean disease duration was 38.8±24.5 (12-120) months. Fungal infection was detected on direct microscopic examination with standard KOH in 66.7% of the patients, culture growth in 38.5%, and PAS staining on histopathological examination in 71.8%, and the sensitivities of these methods were determined as 74.3%, 49.2%, and 80%, respectively, with the negative predictive values being 30.8%, 16.7%, and 36.4%, respectively.

**Conclusion:** Among the investigated methods, histopathological examination with PAS staining was found to have the highest sensitivity and negative predictive value in the diagnosis of onychomycosis.

**Keywords:** Onychomycosis, potassium hydroxide examination, periodic acid-Schiff staining, fungal culture

## INTRODUCTION

Onychomycosis is a fungal infection of the nail that causes the thickening and discoloration of the affected nail plate (1). According to recently published studies, the global prevalence of onychomycosis approximately 5.5% in the general population (2,3). Onychomycosis accounts for 50% of all nail diseases and is the most common disorder affecting the nail unit (1). Predisposing factors for this fungal infection include diabetes, human immunodeficiency virus, immunosuppression, diabetes, obesity, smoking, trauma, tinea pedis, psoriasis, and older age (4). Onychomycosis most commonly involves the toenails, usually affecting the first (great) toenail. It typically presents as the white or yellow-brown discoloration of the nail and often causes the hyperkeratosis of the nail bed, which results in varying degrees of onycholysis (1,4). Organisms that cause onychomycosis include dermatophytes, non-dermatophyte molds (NDMs), and yeasts. Dermatophytes, particularly *Trichophyton mentagrophytes* and *Trichophyton rubrum*, are responsible for approximately 90% of toenail onychomycosis cases,

and the remaining dermatophyte infections are caused by *Epidermophyton floccosum*, *Microsporum* species, *Trichophyton verrucosum*, *Trichophyton tonsurans*, *Trichophyton violaceum*, *Trichophyton soudanense*, *Trichophyton krajdennii*, *Trichophyton equinum*, and *Arthroderma* species (1,5,6). The most common NDM organisms associated with onychomycosis are *Aspergillus* spp., *Scopulariopsis brevicaulis*, *Fusarium* spp., *Acremonium* spp., *Neoscytalidium* spp., and *Syncephalastrum* spp. (7,8). Yeast-induced onychomycosis is rare. *Candida albicans* accounts for approximately 70% of yeast-induced onychomycosis cases (9). There is a need for effective and sensitive diagnostic tests that can confirm the diagnosis of onychomycosis before initiating systemic antifungal therapy. Currently, the main diagnostic methods for onychomycosis are direct microscopic examination, histological examination, and culture analysis (10). However, direct microscopic examination with potassium hydroxide (KOH) and histological examination with periodic acid-Schiff (PAS) staining cannot identify fungal species. Therefore, despite the disadvantage of being the slowest

method, culture analysis has the benefit of identifying the species causing onychomycosis (11). The current study aimed to compare the diagnostic value of direct microscopic examination, histopathological examination, and fungal culture analysis in the clinical diagnosis of onychomycosis.

**MATERIAL AND METHOD**

The study was carried out with the permission of İstanbul Medipol University Clinical Researches Ethics Committee (Date: 26/08/2022, Decision No: E-10840098-772.02-4808). All procedures were carried out in accordance with the ethical rules and the principles of the Declaration of Helsinki.

This study included 39 patients with onychomycosis who presented to the dermatology outpatient clinic of Medipol Mega University Hospital between May 2019 and August 2022. The patients’ age, gender, comorbidities, disease duration, and examination findings were recorded from their files. The results of the direct microscopic examination with KOH, histopathological examination with PAS staining, and fungal agents that grew in culture were noted.

**Direct Microscopic Examination**

For this examination, a 10-20% KOH solution was utilized as the most commonly used material (10). The sample taken from the suspicious nail was placed on a slide, one or two drops of this solution were dropped onto the slide, which was then covered with a coverslip. The slide was left in a petri dish with moist blotting paper for 30-60 minutes and examined under a light microscope.

**Histopathological Examination**

Sections of 3-µm thickness were taken from paraffin blocks, placed on positively charged slides, and kept in an oven at 60 °C for 30 minutes. Histochemical staining was automatically performed with the Ventana Benchmark® Special Stain device (Ventana, Roche, USA) using the PAS staining kit, BSS deparaffinization, BSS liquid cover slip, and BSS wash solutions. This device has a two-stage operating system, in which the deparaffinization process is performed in the first stage and in the second. PAS, background staining (hematoxylin), and bluing were performed. After the staining was completed, the sections were passed through an increasing alcohol series (80%, 90%, and 96%) and left in xylene for two minutes to remove chemicals. The samples were covered with a film using an automatic closure device (Tissue Single Film, Sakura, Japan). The preparations were analyzed under a light microscope (Eclipse Ni, Nikon, Japan).

**Fungal Culture**

Specimens were inoculated to Sabouraud agar (Becton Dickenson, USA) and dermatophyte agar (Becton Dickenson, USA) and incubated at 25 °C for 28 days (12). Media were monitored every 24 hours in terms of

colony growth. When visible colonies were formed, the microscopic examination was performed. Identification was made based on the presence and shape of microconidia and macroconidia, as well as the shape of the colonies.

**Statistical Analysis**

SPSS 15.0 for Windows (SPSS Inc., Chicago, Illinois, USA) was used for statistical analyses. As descriptive statistics, numbers and percentages were used for categorical variables, and mean, standard deviation, minimum, and maximum values for numerical variables. Differences between the screening tests were examined with the McNemar test. Taking any test positivity as the gold standard, the effectiveness of each screening test was evaluated based on sensitivity defined as the test’s ability to produce a positive result in individuals that truly had the disease, selectivity as the negative test rate among the individuals without the disease, positive predictive value as the probability that the individuals with a positive test truly have the disease, negative predictive value as the probability that the individuals with a negative test do not have the disease, accuracy as the rate of correct identification of the individuals with and without the disease, and negative likelihood ratio as the ratio of the probability of an individual with the disease testing negative to the probability of an individual without the disease testing negative. The statistical alpha significance level was accepted as  $p < 0.05$ .

**RESULTS**

The study included a total of 39 patients with a diagnosis of onychomycosis, 11 (28.2%) female and 28 (71.8%) male, with a mean age of  $43.1 \pm 13.9$  years. Distal subungual onychomycosis was present in 53.8% of the patients and total dystrophic onychomycosis in 46.2%. The mean disease duration was  $38.8 \pm 24.5$  months, with a minimum value of 12 and a maximum value of 120 months. **Table 1** summarizes the characteristics of the patients participating in the study.

Table 1. General characteristics of the patients	
Age, mean±SD (min-max/median)	43.1±13.9 (19-75/41)
Gender, n (%)	
Female	11 (28.2%)
Male	28 (71.8%)
Distal subungual onychomycosis, n (%)	21 (53.8%)
Total dystrophic onychomycosis, n (%)	18 (46.2%)
Disease duration (month), mean±SD (min-max/median)	38.8±24.5 (12-120/36)
SD: Standard deviation	

Of the patients, 66.7% tested positive in the direct microscopic examination with KOH, 71.8% in the histopathological examination with PAS staining, and 38.5% in the culture analysis. The rate of positivity detected

in the culture analysis was lower compared to the remaining diagnostic methods. The rates negative test results were 33.3%, 28.2%, and 61.5% for KOH examination, PAS staining, and culture analysis, respectively. **Table 2** presents the rates of positive and negative test results of the cases according to the diagnostic methods.

**Table 2. Positivity and negativity rates of the diagnostic methods**

Onychomycosis	KOH examination		Culture		PAS staining	
	N	%	n	%	n	%
Positive	26	66.7	15	38.5	28	71.8
Negative	13	33.3	24	61.5	11	28.2

KOH vs. culture, p = 0.02; KOH vs PAS, p = 0.774; culture vs PAS, p = 0.011, KOH: Potassium hydroxide; PAS: Periodic acid-Schiff

The histopathological examination with PAS staining was the method with the highest sensitivity (80%) and negative

predictive value (36.4%). The sensitivity of the direct microscopic examination with KOH was 74.3%, and that of the culture analysis was 49.2%. The negative predictive values of the KOH examination and culture analysis were found to be 30.8% and 16.7%, respectively (**Table 3**).

The distribution of the fungal agents that grew in culture was as follows: *Trichophyton* spp. in nine cases, *Aspergillus* spp. in three, *Penicillium* spp. in one, and *Candida* spp. in one. The study data are summarized in **Table 4**.

**Table 3. Sensitivity percentages obtained as a result of analyses performed with the diagnostic methods**

	Sensitivity %	Specificity %	Positive predictive value %	Negative predictive value %	Accuracy %
KOH	74.3	100%	100%	30.8	76.9
Culture	49.2	100%	100%	16.7	48.7
PAS	80.0	100%	100%	36.4	82.1

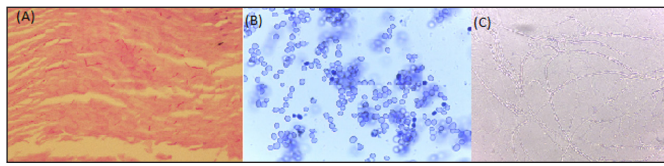
KOH: Potassium hydroxide; PAS: Periodic acid-Schiff

**Table 4. Summary of the study data**

Patient number	Age	Gender	DSO	TDO	Disease duration (month)	KOH	PAS	Culture	
1	70	M	+	-	24	+	+	+	Trichophyton
2	61	M	-	+	60	-	+	-	-
3	29	M	+	-	24	-	-	+	Aspergillus
4	31	M	-	+	60	+	+	-	-
5	48	M	-	+	12	+	+	-	-
6	40	M	-	+	48	+	+	-	-
7	44	M	-	+	48	+	+	-	-
8	26	M	+	-	12	+	+	+	Trichophyton
9	39	F	+	-	36	+	+	-	-
10	34	F	-	+	24	+	+	-	-
11	40	M	-	+	24	+	+	+	Trichophyton
12	19	M	+	-	36	+	+	-	-
13	64	F	-	+	24	+	+	-	-
14	31	M	+	-	24	-	+	-	-
15	46	M	+	-	60	+	+	-	-
16	59	M	+	-	72	+	-	-	-
17	28	M	+	-	12	-	-	+	Candida
18	55	F	+	-	60	-	+	-	-
19	41	M	-	+	36	+	+	-	-
20	30	F	-	+	48	-	-	-	-
21	43	F	-	+	12	-	-	-	-
22	72	M	+	-	60	+	+	-	-
23	27	F	+	-	72	-	-	-	-
24	51	F	+	-	60	+	+	-	-
25	35	M	+	-	24	+	+	-	-
26	25	M	+	-	24	+	-	-	-
27	47	F	+	-	24	-	+	+	Aspergillus
28	75	M	-	+	36	+	+	+	Penicillium
29	22	F	-	+	12	-	+	+	Trichophyton
30	40	M	-	+	60	+	+	-	-
31	31	F	+	-	60	+	-	+	Trichophyton
32	50	M	-	+	12	+	+	+	Trichophyton
33	45	M	+	-	24	+	-	+	Trichophyton
34	47	M	-	+	12	-	-	-	-
35	57	M	+	-	12	-	+	+	Aspergillus
36	46	M	-	+	60	-	+	-	-
37	51	M	+	-	72	+	-	+	Trichophyton
38	41	M	-	+	120	+	+	+	Trichophyton
39	40	M	+	-	12	+	+	+	Penicillium

KOH: Potassium hydroxide; PAS: Periodic acid-Schiff; F, Female; M, Male; +: Positive result; -: Negative result; DSO: Distal subungual onychomycosis; TDO: Total dystrophic onychomycosis

The microscopic images of fungal hyphae and yeast visualized using the three diagnostic techniques are summarized in **Figure 1**.



**Figure 1.** Microscopic images. A: Histochemical examination of fungal hyphae with periodic acid-Schiff staining (x200); B: *Candida* yeast cells stained with methylene blue (x40); C: Direct microscopic examination of fungal hyphae with potassium hydroxide

## DISCUSSION

Onychomycosis is one of the most common fungal diseases. Direct microscopic examination with KOH is a fast and inexpensive diagnostic method for onychomycosis. However, when using this method, false negative results may be obtained due to the examination of the infected nail not containing any fungal hyphae, the poor quality of the KOH solution, the presence of a history of topical and systemic treatments, and the insufficient experience of the clinician (13-16). Furthermore, secondary contamination and air bubbles mimicking fungal structures can produce false positive results. In the literature, the positivity rates of the direct microscopic examination with KOH in onychomycosis vary between 32 and 96% (17-22). In many studies, the positivity rate of this diagnostic method was found to be lower compared to the histopathological examination with PAS staining and higher compared to the culture analysis (17,18,23-25); however, there are also researchers reporting that the direct microscopic examination with KOH had the lowest positivity rate (19,20). In contrast, in two studies conducted in Turkey, Aydingöz et al. (21) and Ceren et al. (22) determined the KOH method to have the highest positivity at 96% and 85%, respectively. In onychomycosis, the sensitivity of this test varies in a wide range from 44 to 92% (17-20,22,26-29). It was found to be the most sensitive method in the diagnosis of onychomycosis by Ceren et al. (22) (92%) and Hsiao et al. (27) (87%). However, Wilsmann-Theis et al. (26) determined that the KOH method had the lowest sensitivity with a rate of 48%. In the current study, the positivity and sensitivity rates of the direct microscopic examination with KOH were 66.7% and 74.3%, respectively. These rates were lower than the histopathological examination with PAS staining and higher than the culture analysis.

In the literature, the positivity and sensitivity rates of the culture analysis are generally found to be lower compared to the histopathological examination with PAS staining and direct microscopic examination with KOH. The culture positivity rate as reported to be low (19%) by Ceren et al. (22), higher (52%) by

Gianni et al. (30) and vary between 19 and 52% in other studies (17,21,23-25,28). However, the absence of growth in culture does not exclude the diagnosis of onychomycosis. Among the reasons for negative results are insufficient analysis material, the incorrect placement of samples in the culture medium, material being kept in the culture medium longer than required, contamination with or growth of secondary pathogens, removal of nail material from the distal portion that does not contain live fungi, and the use of topical or systemic antifungals. Therefore, positivity increases in repeat culture analyses. In a study by Gupta (31), when the culture analysis was performed once, the positivity rate was 44.5%, but when it was performed four times, the positivity rate increased to 63.7%. Test results are affected by differences in the sampling and handling of clinical specimens in centers, skill levels, or clinical samples (11). In the literature, the sensitivity of the culture analysis varies between 20 and 70% (17-20,22,26-29). In a study on onychomycosis, Jeelani et al. (19) found the sensitivity of the culture analysis to be as high as 70%; however, this rate was lower compared to other diagnostic methods. Consistent with the literature, in the current study, the positivity and sensitivity rates of the culture analysis were 38.5% and 49.2%, respectively, but it had the lowest sensitivity among the three diagnostic methods. Although this analysis allows for the fungal agent to be classified as a dermatophyte, non-dermatophyte mold, or yeast, it does not provide information on whether the growing agent is a true pathogen or there is any contamination (21,31). Grover et al. (23) detected fungi in 44% of 120 cases, and 70.2% of these positive cases were identified to have *Trichophyton* spp. Hajar et al. (32) identified *Trichophyton* spp. in 80% of positive cultures. In another study, *Trichophyton* spp. were also shown to be the most isolated organisms (33). In the current study, *Trichophyton* spp. grew in 60% of the positive cultures.

In the literature, it has been shown that the most sensitive method in the diagnosis of onychomycosis is the histopathological examination with PAS staining. In previous studies, the positivity of this test varied between 47 and 90%, and its sensitivity ranged from 80 to 92% (13,19-26,28-30,33). The PAS method was reported to have a high sensitivity rate of 80% by Karimzadegan-Nia et al. (29), 82% by Wilsmann-Theis et al. (26), 90% by Shenoy et al. (18), 91.6% by Jeelani et al. (19), and 92% by Weinberg et al. (20). However, in other studies, despite the high sensitivity rates of this test (80, 81, and 90%), this method still had lower sensitivity values compared to the direct microscopic examination with KOH (21,22,27). In the current study, the histopathological examination with PAS staining had the highest positivity (71.8%) and sensitivity (80%).



The rates of negative predictive values of the direct microscopic examination with KOH, histopathological examination with PAS staining, and culture analysis were previously reported as 53%, 42%, and 10%, respectively by Ceren et al. (22), 58%, 77%, and 43%, respectively by Weinberg et al. (20), and 50%, 40%, and 28%, respectively by Hsiao et al. (27). In the current study, the negative predictive value was 30.8% for the KOH method, 36.4% for the PAS method, and 16.7% for the culture analysis. The histopathological examination with PAS staining had the highest negative predictive value.

## CONCLUSION

This study investigated the sensitivity of the direct microscopic examination with KOH, histopathological examination with PAS staining, and culture analysis in the diagnosis of onychomycosis. The histopathological examination with PAS was found to be superior to the remaining two methods in the diagnosis of onychomycosis, with a high negative predictive value and sensitivity. The culture analysis had the lowest sensitivity and negative predictive value.

## ETHICAL DECLARATIONS

**Ethics Committee Approval:** The study was carried out with the permission of İstanbul Medipol University Clinical Researches Ethics Committee (Date: 26/08/2022, Decision No: E-10840098-772.02-4808).

**Informed Consent:** Written informed consent was obtained from all participants who participated in this study.

**Referee Evaluation Process:** Externally peer-reviewed.

**Conflict of Interest Statement:** The authors have no conflicts of interest to declare.

**Financial Disclosure:** The authors declared that this study has received no financial support.

**Author Contributions:** All of the authors declare that they have all participated in the design, execution, and analysis of the paper, and that they have approved the final version.

## REFERENCES

- Gupta AK, Stec N, Summerbell RC, et al. Onychomycosis: a review. *J Eur Acad Dermatol Venereol* 2020; 34: 1972-90.
- Gupta AK, Versteeg SG, Shear NH. Onychomycosis in the 21st century: an update on diagnosis, epidemiology, and treatment. *J Cutan Med Surg* 2017; 21: 525-39.
- Maraki S, Mavromanolaki VE. Epidemiology of onychomycosis in Crete, Greece: a 12-year study. *Mycoses* 2016; 59: 798-802.
- Leung AKC, Lam JM, Leong KF, et al. Onychomycosis: an updated review. *Recent Pat Inflamm Allergy Drug Discov* 2020; 14: 32-45.
- Lipner SR, Scher RK. Onychomycosis: clinical overview and diagnosis. *J Am Acad Dermatol* 2019; 80: 835-51.
- Pang SM, Pang JYY, Fook-Chong S, Tan AL. Tinea unguium onychomycosis caused by dermatophytes: a ten-year (2005-2014) retrospective study in a tertiary hospital in Singapore. *Singapore Med J* 2018; 59: 524-7.
- Summerbell RC, Gueidan C, Guarro J, et al. The protean *Acremonium*. A. sclerotigenum/egyptiacum: revision, food contaminant, and human disease. *Microorganisms* 2018; 6: 88.
- Bongomin F, Batac CR, Richardson MD, Denning DW. A review of onychomycosis due to *Aspergillus* species. *Mycopathologia* 2018; 183: 485-93.
- Subramanya SH, Subedi S, Metok Y, Kumar A, Prakash PY, Nayak N. Distal and lateral subungual onychomycosis of the finger nail in a neonate: a rare case. *BMC Pediatr* 2019; 19: 168.
- Ghannoum M, Mukherjee P, Isham N, Markinson B, Rosso JD, Leal L. Evaluating the importance of laboratory and diagnostic testing when treating and diagnosing onychomycosis. *Int J Dermatol* 2018; 57: 131-8.
- Karaman BFO, Açıklan A, Ünal İ, Aksungur VL. Diagnostic values of KOH examination, histological examination, and culture for onychomycosis: a latent class analysis. *Int J Dermatol* 2019; 58: 319-24.
- Murray P, Rosenthal K, Pfaller M (editors). In: *Medical microbiology*. Eighth ed., Elsevier; 2015: 585-94.
- Reisberger EM, Abels C, Landthaler M, Szeimies RM. Histopathological diagnosis of onychomycosis by periodic acid-Schiff-stained nail clippings. *Br J Dermatol* 2003; 148: 749-54.
- Shemer A, Trau H, Davidovici B, Grunwald MH, Amichai B. Collection of fungi samples from nails: comparative study of curettage and drilling techniques. *J Eur Acad Dermatol Venereol* 2008; 22: 182-5.
- Fletcher CL, Hay JR, Smeeton NC. Onychomycosis: The development of a clinical diagnostic aid for toenail disease: Part I. Establishing discriminating historical and clinical features. *Br J Dermatol* 2004; 150: 701-5.
- Daniel CR 3rd, Elewski BE. The diagnosis of nail fungus infection revisited. *Arch Dermatol* 2000; 136: 1162-4.
- Borkowski P, Williams M, Holewinski J, Bakotic B. Onychomycosis: an analysis of 50 cases and a comparison of diagnostic techniques. *J Am Podiatr Med Assoc* 2001; 91: 351-5.
- Shenoy MM, Teerthanath S, Karnaker VK, Girisha BS, Krishna Prasad MS, Pinto J. Comparison of potassium hydroxide mount and mycological culture with histopathologic examination using periodic acid-Schiff staining of the nail clippings in the diagnosis of onychomycosis. *Indian J Dermatol Venereol Leprol* 2008; 74: 226-9.
- Jeelani S, Ahmed QM, Lanker AM, Hassan I, Jeelani N, Fazili T. Histopathological examination of nail clippings using PAS staining (HPE-PAS): gold standard in diagnosis of onychomycosis. *Mycoses* 2015; 58: 27-32.
- Weinberg JM, Koestenblatt EK, Tutrone WD, Tishler HR, Najarian L. Comparison of diagnostic methods in the evaluation of onychomycosis. *J Am Acad Dermatol* 2003; 49: 193-7.
- Aydingöz İE, Akkaya AD, Aker F, Adaleti R. Comparison of methods for the diagnosis of onychomycosis in a series of 50 cases. *Türkderm* 2006; 40: 20-2.
- Ceren E, Ekmekci TR, Sakız D, Köşlü A, Bayraktar B. Comparison of the methods for the diagnosis of onychomycosis. *Türkderm* 2008; 42: 91-3.
- Grover C, Reddy BSN, Chaturvedi KU. Onychomycosis and the diagnostic significance of nail biopsy. *J Dermatol* 2003; 30: 116-22.
- Erkan F, Kaçar SD, Özüğüz P, Aşık G, Tokyol Ç, Karaca Ş. Comparison of the efficacy and cost-effectiveness of five different diagnostic methods in the evaluation of onychomycosis. *Türkderm* 2014; 48: 21-5.

25. Arca E, Saracli MA, Akar A, Yildiran ST, Kurumlu Z, Gur AR. Polymerase chain reaction in the diagnosis of onychomycosis. *Eur J Dermatol* 2004; 14: 52-5.
26. Wilsmann-Theis D, Sareika F, Bieber T, Schmid-Wendtner M-H, Wenzel J. New reasons for histopathological nail-clipping examination in the diagnosis of onychomycosis. *J Eur Acad Dermatol Venereol* 2011; 25: 235-7.
27. Hsiao Y-P, Lin H-S, Wu T-W, et al. A comparative study of KOH test, PAS staining and fungal culture in diagnosis of onychomycosis in Taiwan. *J Dermatol Sci* 2007; 45: 138-40.
28. Yurtoğlu F, Yıldız L, Şentürk N, et al. Comparison of diagnostic methods for onychomycosis: a controlled, prospective study. *Turk J Dermatol* 2011; 5: 48-52.
29. Karimzadegan-Nia M, Mir-Amin-Mohammadi A, Bouzari N, Firooz A. Comparison of direct smear, culture and histology for the diagnosis of onychomycosis. *Australas J Dermatol* 2007; 48: 18-21.
30. Gianni C, Morelli V, Cerri A, et al. Usefulness of histological examination for the diagnosis of onychomycosis. *Dermatology* 2001; 202: 283-8.
31. Gupta A. The incremental diagnostic yield of successive recultures in patients with a clinical diagnosis of onychomycosis. *J Am Acad Dermatol* 2005; 52: 129.
32. Hajar T, Fernández-Martínez R, Moreno-Coutiño G, Vázquez Del Mercado E, Arenas R. Modified PAS stain: a new diagnostic method for onychomycosis. *Rev Iberoam Micol* 2016; 33: 34-7.
33. Jung MY, Shim JH, Lee JH, et al. Comparison of diagnostic methods for onychomycosis, and proposal of a diagnostic algorithm. *Clin Exp Dermatol* 2015; 40: 479-84.