

## THE RADIOGRAPHIC LOCATION OF IMPACTED MAXILLARY CANINES

Prof. Dr. Erdoğan TURGUT\*

### SUMMARY

In this article, it is emphasized that the use of the lateral shift (Shift-sketch) or Clark's technique) and the vertex occlusal (cross-section) methods can be valuable in diagnosis the position of the impacted maxillary canines.

The lateral shift method is easily applied and gives sufficient information to be of practical value, the vertex occlusal method of localization remains the most accurate method available at the present time.

After the third molar, the maxillary canine is the tooth that is most frequently impacted with a reported prevalence of 0.9 % to 2 %.<sup>1</sup> Among impacted maxillary canines, 76 % to 93 % are positioned palatally or within the dental arch and the remainder are displaced labially.<sup>2</sup> Labially displaced maxillary canines can be treated interceptively with a good prognosis, whereas palatally impacted maxillary canines have the least tendency to erupt. According to Cranin and Cranin<sup>3</sup> and Lind<sup>4</sup> the mesioangular position is seen most frequently. Marsh<sup>5</sup> came to a conclusion that displacement towards a horizontal position, observed in 32 % might be a result of the root.

Panoramic radiography is a technique which in recent years has become increasingly popular in dental practices. The advantage of panoramic radiography is that it provides an image of the entire dentition on a single film. Although panoramic radiographs confirm the presence of an impacted tooth, it is not possible to determine whether the impacted tooth is lying in a palatal, lingual or labial position (Fig 1).

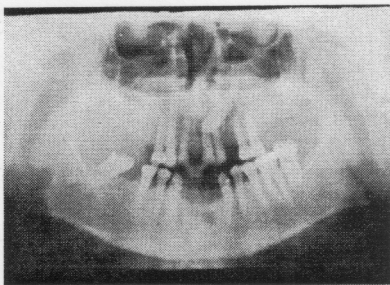


Figure 1. Visualising the impacted maxillary left canine in a panoramic radiograph.

Failure to diagnose and intercept the impacted canines often leads to serious malpositions that require extensive mechanical therapy alignment and food function. It is important to determine before an orthodontic or a surgical procedure (autotransplantation) whether the impacted maxillary canine is in a palatal or labial position.

If the patient lacks a canine bulge buccally or palatally, radiographs should be taken for diagnosing the position of impacted upper canine.

### LOCALIZATION

One method of localizing impacted teeth employs the buccal object rule. This rule states that the image of any buccally oriented object appears to move in the opposite direction from a moving X-ray source. Conversely, the image of any lingually oriented object appears to move in the same direction as a moving X-ray source.

This method could be used to localize foreign bodies, broken needles, broken instruments, filling materials in the alveolar process, retained roots, calculi in a salivary gland or duct and intraosseous tumors

### LOCALIZATION OF IMPACTED MAXILLARY CANINE

#### 1. Lateral shift method (shift-sketch method, Clark's Technique)

The method is as follows: The patient's head is positioned so that the sagittal plane is perpendicular to the floor. An intraoral periapical film is positioned in the patient's mouth behind the canine area but with less than 1/8 inch of the film extending below the cusps of neighbouring teeth. The film is held in position by the patient with the thumb of the opposite hand and exposed (orthoradial radiograph) (Fig 2-A). A second film is placed in the mouth in the same position as the first film, and the patient's head position remains the same. The vertical angulation should be the same for each exposure. However, the horizontal angle is shifted either anteriorly or posteriorly for the second view. The second film is then exposed (Horizontally eccentric radiograph) (Fig 2-B).

\* Professor of OD/Rad. Department, H U Faculty of Dentistry

Fig 2-A shows an impacted maxillary canine. The shadow of this tooth is superimposed over the roots of central and lateral incisors. When the horizontal angle of the X-ray tube is shifted posteriorly, the impacted canine seems to move posteriorly too. In Fig 2-B note that the image of the crown of the canine is no longer superimposed over the roots of the central and lateral incisors. If the buccal object rule is applied, it can be seen that the impacted canine is palatally oriented to the erupted teeth.

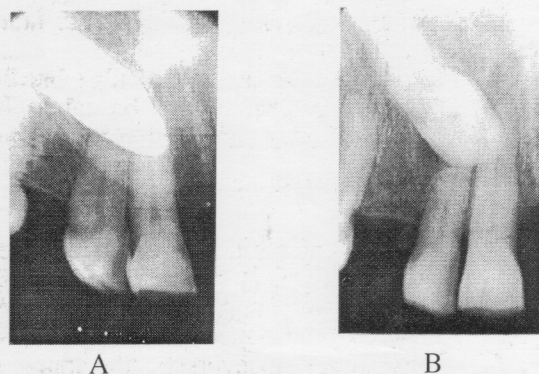


Figure 2. **A:** Shadows of the maxillary left canine is superimposed over the roots of the central and lateral incisors.

**B:** When the horizontal angle of the X-Ray tube is shifted posteriorly, the impacted canine appears to move posteriorly too, therefore the canine is palatally placed.

## 2. The vertex occlusal (cross-section method):

This is another localization technique which demonstrates the labiopalatal relationship of the maxillary canine. To obtain this view of the maxilla, the patient's sagittal plane is perpendicular to the floor and the occlusal plane of the upper teeth is parallel to the plane of the floor. In other words, the line from the tragus of the ear to ala of the nose is parallel with the floor.

The intraoral cassette (2.25 x 3 inches) is used with the super-speed screen film for this view of the maxilla. Use of this kind of cassette and film decreases the exposure time and the chance of movement of the patient.

The occlusal cassette is placed horizontally with the short axis coincident with the sagittal plane, and as far back in the mouth as to cover the third molar region. The cassette is held between teeth with edge-to-edge closure. The central ray is directed perpendicular to the cassette or parallel with the long axis of the anterior teeth. Exposure time is about 2 seconds.

The standard midline occlusal view of the upper jaw (Topographic occlusal) is not convenient for localization of the impacted maxillary canine. Because impacted maxillary being high off the cassette, will be projected in a backward direction and will therefore always appear to be palatally placed.

Whereas the lateral shift method will determine whether an impacted maxillary canine is lying labially or palatally, the vertex occlusal view will show to what extent it lies labially or palatally<sup>6</sup> (Fig 3).

A correct radiographic location of impacted maxillary canines would be a prerequisite for the achievement of an optimal clinical result. The surgical and orthodontic procedures are facilitated by accurate evaluation of the position of impacted maxillary canines.

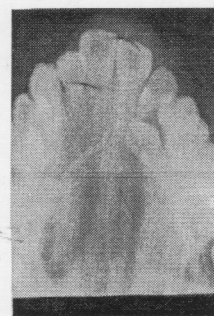


Figure 3. The vertex (cross-section) occlusal view demonstrating the palatal position of the impacted left maxillary canine.

## REFERENCES

1. Rayne JO. The unerupted maxillary canine. Dent Pract 1969; 19: 194-204.
2. Bass TP. Observations on the misplaced upper canine tooth. Dent Pract 1967; 18: 25-33.
3. Cramm AN, Cranin SL. Aiding of maxillary cuspids. Dent Radiogr. Photogr. 1968; 41: 27-34.
4. Lind V. Overkashortendens eruption problem Tandlakartindigen. 1977; 69: 1066-1074.
5. March W. Aberrant canines. Dent Pract Dent Rec 1965; 16: 124-126.
6. Bird PD. The radiographic location of unerupted maxillary teeth with the vertex occlusal view. Dent Pract 1960; 8: 181-183.