

Frequency of Sphenoid Sinus Pneumatization in Panoramic Radiographs

Melike Yurttaş^{id}, Mustafa Kiranatlı^{id}

Kütahya Health Science University, Faculty of Dentistry, Department of Dentomaxillofacial Radiology, Kütahya, Türkiye.

Correspondence Author: Melike Yurttaş

E-mail: basarannm@gmail.com

Received: 27.11.2022

Accepted: 03.06.2023

ABSTRACT

Objective: Sphenoid sinus is an irregular cavity in the skull and sphenoid sinus pneumatization (SSP) is a variation of the sphenoid sinus that can observe on the radiographs when it reaches large sizes. It is aimed to evaluate the prevalence of SSP in panoramic radiographs in this study.

Methods: Panoramic radiographs of 500 patients were performed in this study. The patients who applied to our department with miscellaneous dental complaints were over the age of 14. The gender and age of the patients were recorded and the right, left, or bilateral visibility of SSP was examined. The study subjects were classified into four age categories and SSP prevalence was evaluated with gender, age, and visibility by statistical analyses.

Results: Female patients were more than males (78%, and 22% respectively). SSP was found in approximately one-third of the patients (33%) in the panoramic radiographs. Of these, 69 (41.8%) were on the right only, 40 (24.2%) on the left only, and 56 (33.9%) were bilateral. SSP was more common in women (24.2%) and was mostly detected in group 2 (14.4%). Any significant difference was not found in terms of right, left, and bilateral SSP, gender, and age groups. ($p > .05$).

Conclusion: SSP can be superposed in the zygomatic arch as a radiolucency that can be misdiagnosed as a cyst. SSP was observed in approximately one-third of patients in this study so dentists should be aware of superimposed surrounding structures of the maxillofacial region for accurate diagnosis.

Keywords: Sphenoid sinus, Pneumatization, Panoramic radiography, Dentistry

1. INTRODUCTION

The sphenoid sinus is seated centrally and posteriorly within the sphenoid bone. It is an irregular cavity that is adjacent to many important anatomic structures, such as the cavernous sinuses, internal carotid artery, and optic nerve (1,2). The sphenoid sinus is a potential cavity at birth and develops postnatally, reaching its original size usually during adolescence (3,4).

The sphenoid sinus pneumatization (SSP) is variable and its degree varies from absent to wide (2,5). The pneumatization extends into the pterygoid process, lesser and greater wings of the sphenoid bone, anterior and posterior clinoid processes, vomer, ethmoid bones, occipital bone, and the clivus (5).

In some cases, if the sphenoid sinus is extensive, the dentists can incidentally observe the SSP on the zygomatic arch in the panoramic radiography. Although SSP can be observed in some cases, diagnosing SSP can be difficult with conventional radiographic images because of its adjacent relationship with intracranial structures and deep location. The SSP can appear on the panoramic radiograph in three ways: a radiolucency

superimposed on part of the zygomatic arch; an image with an aspect similar to the pterygomaxillary fissure or when the image is loculated, similar to a cystic lesion (5).

Panoramic radiography is a useful two-dimensional imaging modality in dentistry for providing a general impression of the jaws and surrounding structures in a single projection. Moreover, it is a simple, low-dose, and cheap method to examine the jaws, maxillary sinus, zygomatic arch, and adjacent anatomic structures. Misinterpretation in the dental radiographic examination may occur due to distortion and superimposition of anatomic structures and a limited two-dimensional view in the panoramic images. When SSP appears in the panoramic radiograph, it may be misdiagnosed as a cyst by dentists (6). SSP can be evaluated by various imaging methods e.g. computed tomography, and cone-beam computed tomography (CBCT) in the previous studies (2,4,7). Only a few cases of SSP had reported in the panoramic radiograph. Therefore, in this study, the frequency of SSP was investigated on panoramic images and it was aimed to raise awareness about SSP in the dental radiographic examination.

2. METHODS

This retrospective study was performed on panoramic radiographs of 500 patients. The patients who applied to our department with miscellaneous dental complaints were over the age of 14. Necessary permissions were obtained from the non-invasive ethics department of the university (decision number: 2020/12-16). All images were obtained from the same panoramic machine J. Morita Veraviewepocs 2D (J.Morita Mfg. Corp Kyoto/Japan, 14.8 seconds at 65 kV 5-7.5 mA). The patients who had craniofacial anomalies and maxillofacial trauma and the panoramic images that were not evaluated clearly were excluded from the study. A dentomaxillofacial radiologist (M.K.) who had 4 years experienced evaluated the images. On the panoramic radiography, well-defined, unilocular, or multilocular radiolucencies superimposed on the zygomatic arch were accepted as SSP (Figures 1 and 2). The gender and age of the patients were recorded and the right, left, or bilateral visibility of SSP was examined. The age ranges of the patients were divided into 4 different groups: Group 1; 14-30 age, group 2; 31-50 age, group 3; 51-65 age, group 4; 65 years and older. The power test analysis determined that the study's power value was 96% with an effect size 0.17, a Z alpha of 0.05, and 500 sample sizes. The collected data were evaluated in the Statistical Package for the Social Sciences (ver.22; IBM Corporation, Armonk, NY, USA) program. Data analysis was performed with the Pearson chi-square test and results with a p-value less than .05 were considered statistically significant.

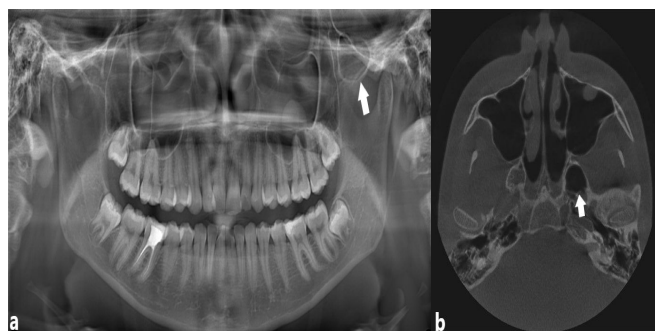


Figure 1. Sphenoid sinus pneumatization (SSP) on the left zygomatic arch in the panoramic image (a) and axial cone-beam computed tomography image (b).

Table 2. Distribution of sphenoid sinus pneumatization by gender and age groups.

	Gender			Age Groups				Total (n %)
	Female (n %)	Male (n %)	Total (n %)	Group 1 (n %)	Group 2 (n %)	Group 3 (n %)	Group 4 (n %)	
Right	47 (68.1)	22 (31.9)	69 (100)	25 (36.2)	31 (44.9)	11 (15.9)	2 (2.9)	69 (100)
p-value	.033			.472				
Left	31 (77.5)	9 (22.5)	40 (100)	15 (37.5)	16 (40)	7 (17.5)	2 (5)	40 (100)
p-value	.937			.878				
Bilateral	43 (76.8)	13 (23.2)	56 (100)	20 (35.7)	25 (44.6)	5 (8.9)	6 (10.7)	56 (100)
p-value	.816			.342				

Chi-square test $p > .05$

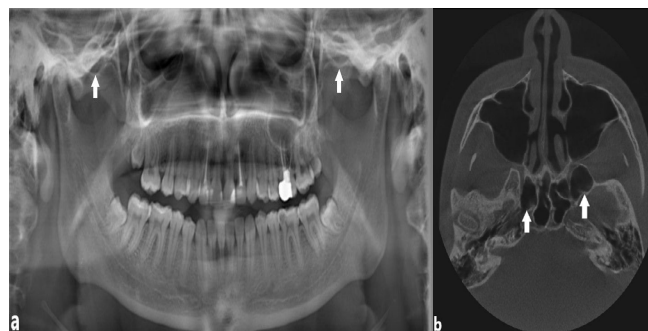


Figure 2. Bilateral sphenoid sinus pneumatization (SSP) on the right and left zygomatic arch in the panoramic image (a) and axial cone-beam computed tomography image (b).

3. RESULTS

A total of 500 patients' panoramic radiographs were evaluated, whose ages were ranging from 14 to 88 years with a mean of 39.95 ± 15.34 . Female patients (78%) were more than male patients (22%) (Table 1). In terms of age groups, most patients were in group 2 followed by group 1 (Table 1). SSP was found in 33% of all patients, of these 41.8% were on the right, 24.2% on the left, and 33.9% were bilateral. While 24.2% of female patients (n=121) had SSP, 8.8% of male patients (n=44) had SSP on the panoramic images. SSP was most common female patients, right side and group 2 (Table 2). The presence of SSP in female and male patients is as in table 3 ($p > .05$). Any significant difference was not found in gender, age groups, right, left, and bilateral SSP.

Table 1. The frequency of the patient's age groups and gender.

	Frequency (n)	Percentage (%)
Age groups		
Group 1 (14-30 aged)	166	33.2
Group 2 (31-50 aged)	214	42.8
Group 3 (51-65 aged)	83	16.6
Group 4 (65 aged and above)	37	7.4
Sex		
Female	390	78
Male	110	22

Table 3. Distribution of sphenoid sinus pneumatization prevalence according to gender and age groups.

	Gender			p value	Age Groups					p value
	Female (n %)	Male (n %)	Total (n %)		Group 1 (n %)	Group 2 (n %)	Group 3 (n %)	Group 4 (n %)	Total (n %)	
Present	121 (24.2)	44 (8.8)	165 (33)	.85	60 (12)	72 (14.4)	23 (4.6)	10 (2)	165 (33)	.48
Absent	269 (53.8)	66 (13.2)	335 (67)		106 (21.2)	142 (28.4)	60 (12)	27 (5.4)	335 (67)	
Total	390 (78)	110 (22)	500 (100)		166 (33.2)	214 (42.8)	83 (16.6)	37 (7.4)	500 (100)	

Chi-square test $p > .05$

4. DISCUSSION

The anatomical variations of the sphenoid sinus are highly variable, it was found that be remarkably common in the various population. SSP is of variations of sphenoid sinus and large sizes of SSP including surrounding structures optic nerve, internal carotid artery, cavernous sinus, maxillary and the cranial nerves III, IV, and VI, and some of these structures may protrude or also be involved by the sphenoid sinus (2,5). Due to its proximity to anatomical structures, the degree and size of SSP have an important role in surgical planning for endoscopic skull base cases.

SSP occurs toward various adjacent anatomical structures but the pterygoid process and anterior clinoid process pneumatization of sphenoid sinus was determined frequently in the previous studies (2,8,9). Pterygoid process pneumatization (PP) is defined if it extends beyond a horizontal plane crossing the vidian canal (2). Considering the anatomical regions of PP in line with the literature and confirmed with CBCT images' the patients, detected SSPs of the study were thought to be suitable for PP.

Development of the sphenoid sinus begins in the intrauterine period and continues until after puberty. For this reason, patients who were aged over 14 were included in this study, and no significant relationship was found between age and the incidence of SSP.

A radiographic assessment is a part of the dental examination routine which is a key role for diagnose, decisive differential and final diagnosis, and treatment plan of several pathological conditions of the maxillofacial region. Panoramic radiography is used commonly by dentists for this purpose. It is a valuable, easy-to-implement, cheap diagnostic tool used in dentistry. However, the panoramic image is a two-dimensional projection of the maxillofacial region with multiple distortions and superimpositions (6). Due to this may lead to misinterpretation of certain pathological conditions like SSP, dentists should have knowledge of the jaws, maxillary sinus, and zygomatic processes and their adjacent structures for correct diagnosis. In case reports with SSP on the panoramic radiographs, SSP was observed as a well-defined, unilocular, or multilocular radiolucent image with a corticated border in the region of the pterygoid process (5,10,11). In this study, SSP was accepted as a well-defined radiolucency with a sclerotic margin superposed on the region of the pterygoid process. Also, for the patients with SSP who had both panoramic and

CBCT images, radiolucency in the region of the pterygoid process on the panoramic radiograph was confirmed by CBCT images (Figures 1 and 2).

SSP has been evaluated in computed tomography, CBCT, or magnetic resonance images (4,12,13). The prevalence of pterygoid plate pneumatization of sphenoid sinus varies between 15% and 37% in the CT studies (12,13), and 38.9% in CBCT studies (8). SSP was found in approximately one-third of the (33%) dental patients' panoramic radiographs, which is consistent with the literature.

Generally, the SSP is symptomless and no treatment is required. Although swelling and eye proptosis due to excessive pneumatization were reported in a few studies that were not new, any symptoms were not stated in recent case reports of SSP (5,10,11). On the one hand, excessive sphenoid sinus is an advantage in accessing the lesions involving the middle cranial fossa, foramen magnum, and retroclival region, on the other hand, protrusion and dehiscence of vital surrounding structures (e.g. vidian canal, optic nerve, internal carotid artery) may occur due to the existing large pneumatization of the sphenoid sinus (2,7).

The male patients' size was the limitation of this study. The predominance of female patients in the sample may have influenced the statistical results. Besides, this study was carried out with the participation of Turkish dental patients. Further studies with much larger sample sizes and different nationalities can contribute to improving the literature.

5. CONCLUSION

SSP that one of the variations of the sphenoid sinus is relatively common in the population. In dentistry, SSP can be superposed on the panoramic radiographs as a radiolucent lesion that can be misdiagnosed as a cyst or other pathologies. Dentists should be aware of superimposed anatomic surrounding structures of the maxillofacial region and an existing suspected lesion in the panoramic images' diagnosis should be affirmed by the advanced imaging modalities (e.g. cone-beam computed tomography).

Acknowledgement: Thank you for supporting the participants in this study.

Funding: The author(s) received no financial support for the research.

Conflicts of interest: The authors declare that they have no conflict of interest.

Ethics Committee Approval: This study was approved by Ethics Committee of Kütahya Health Science University, (approval date 2021 and number 01-24)

Peer-review: Externally peer-reviewed.

Author Contributions:

Research idea: MY.

Design of the study: MY, MK.

Acquisition of data for the study: MK.

Analysis of data for the study: MY, MK.

Interpretation of data for the study: MY, MK.

Drafting the manuscript: MY, MK.

Revising it critically for important intellectual content: MY.

Final approval of the version to be published: MY, MK

REFERENCES

- [1] Cappello ZJ, Minutello K, Dublin AB. Anatomy, Head and Neck, Nose Paranasal Sinuses. 2021 In: StatPearls [Internet]. Treasure Island (FL): StatPearls Publishing; 2022.
- [2] Hewaidi G, Omami G. Anatomic Variation of Sphenoid Sinus and Related Structures in Libyan Population: CT Scan Study. Libyan J Med. 2008;1(3):128-133. DOI:10.4176/080307
- [3] Wiebracht ND, Zimmer LA. Complex anatomy of the sphenoid sinus: A radiographic study and literature review. J Neurol Surg B Skull Base 2014;75(6):378-382. DOI:10.1055/s-0034.137.6195
- [4] Sevinc O, Iş M, Barut C, Erdogan AR. Anatomic variations of sphenoid sinus pneumatization in a sample of Turkish population: MRI Study. International Journal of Morphology 2014;32:1140-1143. DOI:10.4067/S0717.950.2201400.040.0003
- [5] Terra ER, Guedes FR, Manzi FR, Bóscolo FN. Pneumatization of the sphenoid sinus. Dentomaxillofac Radiol. 2006;35(1):47-49. DOI: 10.1259/dmfr/55048928
- [6] Perschbacher S. Interpretation of panoramic radiographs. Aust Dent J. 2012;57(Suppl 1):40-45. DOI: 10.1111/j.1834-7819.2011.01655
- [7] Hiremath SB, Gautam AA, Sheeja K, Benjamin G. Assessment of variations in sphenoid sinus pneumatization in Indian population: A multidetector computed tomography study. Indian J Radiol Imaging 2018;28(3):273-279. DOI: 10.4103/ijri.IJRI_70_18
- [8] Rahmati A, Ghafari R, AnjomShoa M. Normal variations of sphenoid sinus and the adjacent structures detected in cone beam computed tomography. J Dent (Shiraz). 2016;17(1):32-37. Corpus ID: 5474706.
- [9] Silidiroglu O, Sivrioglu A, Kara K, Salihoglu M, Sonmez G., Ozturk E, Cuce F, Saglam M, Mutlu H. Variations of the sphenoid sinus in Turkish population and importance in surgical planning: A CT study. Gulhane Medical Journal 2015;57:339-342. DOI: 10.5455/gulhane.187255
- [10] Sutthiprapaporn P, Rattana-arpha P. Pneumatization of the sphenoid sinus on a panoramic radiograph. CU Dent J. 2016;39:75-80.
- [11] Kusch A, Ruiz E. Giant pneumatization of sphenoid sinus: Report of four cases and review of literature. Revista Medica Herediana 2019;30:45-49. DOI: 10.20453/rmh.v30i1.3472
- [12] Degaga TK, Zenebe AM, Wirtu AT, Woldehawariat TD, Dellie ST, Gemechu JM. Anatomographic variants of sphenoid sinus in ethiopian population. diagnostics (Basel). 2020 ;10(11):970. DOI: 10.3390/diagnostics10110970
- [13] Erdoğan S, Keskin G, Topdağ M, Sarı F, Öztürk M, İşeri M. Bilgisayarlı tomografide sfenoid sinüs anatomik varyasyonları. Süleyman Demirel Üniversitesi Sağlık Bilimleri Dergisi 2015; 6(2): 55 – 58. (Turkish) DOI: 10.22312-sbed.39121-196067

How to cite this article: Yurttaş M, Kiranatlı M. Frequency of Sphenoid Sinus Pneumatization in Panoramic Radiographs. Clin Exp Health Sci 2023; 13: 760-763. DOI: 10.33808/clinexphealthsci.1210787