



Pulmonary Parasitic Embolization Caused by Micro Ruptured Hydatid Cyst: An Autopsy Case

Mikrorüptüre Kist Hidatik Kaynaklı Pulmoner Parazitik Embolizasyon: Bir Otopsi Olgusu


Uğur ATA¹

 0000-0002-8400-293X


Derya ÇAĞLAYAN²

 0000-0002-9088-5097


Cemil ÇELİK¹

 0000-0002-8103-459X

Erhan KARTAL³

 0000-0003-2459-7756

Arzu AKÇAY⁴

 0000-0001-8343-1153

¹Council of Forensic Medicine,
İstanbul, Türkiye

²Department of Epidemiology,
Department of Public Health, Dokuz
Eylül University Faculty of Medicine,
İzmir, Türkiye

³Department of Forensic Medicine,
Van Yüzüncü Yıl University Faculty
of Medicine, Van, Türkiye

⁴Department of Pathology, Yeniüyüzlü
University and Atakent Hospital,
Acıbadem University, İstanbul,
Türkiye

Corresponding Author
Sorumlu Yazar
Uğur ATA
dr.ata52@hotmail.com

Received / Geliş Tarihi : 15.12.2022
Accepted / Kabul Tarihi : 20.02.2023
Available Online /
Çevrimiçi Yayın Tarihi : 16.03.2023

ABSTRACT

Echinococcosis generally remains asymptomatic for many years, but it can also be fatal if complications like cyst rupture or superinfection occur. It is highly uncommon for a macroscopically non-ruptured cyst to cause death, and its exact mechanism is unknown. In the literature, there are several cases with identical characteristics diagnosed by autopsy. This autopsy case has illustrated the death due to a micro ruptured hydatid cyst. The deceased's lung underwent microscopic inspection, and it revealed broad intraalveolar hemorrhage, edema, severe hyperemia, neutrophil stasis in the interstitial capillary lumens, and a large number of parasites in the capillary lumen. Anaphylaxis against cyst contents that leaked into the bloodstream from liver cysts and non-thrombotic pulmonary embolization were shown to be the causes of mortality. In countries where echinococcosis is endemic, echinococcosis should be considered in all cases of anaphylaxis and sudden death.

Keywords: Anaphylaxis; echinococcus; liver; parasitemia; sudden death.

ÖZ

Ekinokokkoz genellikle uzun yıllar boyunca asemptomatik kalmakla birlikte kist rüptürü, süperenfeksiyon gibi komplikasyonlar nedeniyle ölüme de neden olabilmektedir. Makroskopik olarak non-rüptüre kiste bağlı ölüm oldukça nadir olup mekanizması tam olarak bilinmemektedir. Literatürde otopsi ile tanı konulan benzer özellikte birkaç olgu bildirilmektedir. Bu otopsi olgusunda hidatik kist mikrorüptürüne bağlı olduğu değerlendirilen ölüm sunulmaktadır. Karaciğerinde rüptüre olmayan kist saptanan cesetin akciğerinin mikroskopik incelemesinde yaygın intraalveolar kanama, ödem, ağır hiperemi, interstisyel kapiller lümenlerinde nötrofil stazi, kapiller lümeninde çok sayıda parazit varlığı saptandı. Ölüm nedeninin intakt karaciğer kistlerinden kan dolaşımına sızan kist içeriğine karşı gelişen anafilaksi ve nontrombotik akciğer embolizasyonu sonucu geliştiği düşünülmüştür. Ekinokokkozun endemik olduğu ülkelerde tüm anafilaksi ve ani ölüm olgularında ayrırcı tanıda ekinokokkoz düşünülmesi gerekmektedir.

Anahtar kelimeler: Anafilaksi; ekinokokkoz; karaciğer; parazitemi; ani ölüm.

INTRODUCTION

A serious global problem, cystic echinococcosis (CE), which is brought on by the genus Echinococcus, is endemic in the Middle East, Central Asia, South America, North and East Africa (1). It is transmitted either directly through contact with dogs and dog feces or indirectly through contaminated foods; it also causes disease in people over the years. It can be located almost everywhere in the human body. The liver is where it is most frequently found, followed by the lung. Although it is usually

Presented orally at 10th EKMUD International Scientific Congress (May 25-29, 2022; Antalya, Türkiye).

asymptomatic, depending on the location and size of the cyst in the body, it might result in symptoms such as coughing, fever, chest pain, dyspnea, abdominal masses, ascites, hepatomegaly, and splenomegaly; in severe circumstances, it may even be a fatal condition (1-3).

The clinical picture of the hydatid pulmonary embolism is nonspecific and it can range from asymptomatic or general clinical indications of a pulmonary embolism due to obstruction of pulmonary artery branches (4). Hydatid pulmonary embolism is a rare but potentially life-threatening complication due to the risk of acute fatal complications such as anaphylactic shock (5).

It is reported that the incidence of sudden death due to hydatid cyst is around 1.1-1.3% (6,7). It is difficult to explain the involvement of a hydatid cyst in the death mechanism, particularly if it is seen intact and discovered at autopsy (8).

The presented case shares traits with those of patients who died from parasite pulmonary embolization and anaphylaxis from a ruptured hydatid cyst in the liver. However, it differs in that no macroscopically ruptured cysts have been observed. This case seeks to critically discuss postmortem approaches and causes of death for the evaluation of cases with hydatid cyst during an autopsy, in the light of the literature.

CASE REPORT

The following sequence of events was described in the account provided by witnesses to the 20-year-old male case who was 180 cm tall and weighed 95 kg before the incident: jogging uphill after overeating, followed by a sudden fainting spell, followed by uncontrollable contractions on the floor that resembled epilepsy, which ultimately resulted in death. There was no trauma story. Since the relatives of the deceased were unreachable, his medical history was unknown. Since the cause of sudden death was undetermined, a forensic autopsy was performed by a specialized medical doctor. The postmortem computerized tomography (CT) examination of the case provides the following overview: according to the GHARBI Liver Hydatid Cyst Classification, Type IV cysts measuring 7.93x11.64 cm (Figure 1) and Type II cysts measuring 5.52x5.09 cm (Figure 2) were found in the liver segment 7 and segment 6, respectively. In the abdomen, there was no free fluid to be seen. No significant rupture was observed in the cysts. Contrast-enhanced postmortem CT examination could not be performed.

During the case's external examination, it was noted that the auricles and nail bed were cyanosed in addition to the fact that bloody fluid was leaking from the nose. As far as the macroscopic findings of the internal examination are concerned; petechiae under the scalp, bloody foamy fluid in the form of smearing in the trachea and both main bronchi, mild edema, and hyperemia (Figure 3) in the larynx were all noticed.

The liver weighed 1510 g. Loose, fluid-filled cysts in the superior posterior of the right lobe and white, spherical, harder cysts in the inferior of the right lobe were detected. The cyst walls were macroscopically intact (Figure 4). The right lung weighed 350 g and the left lung 300 g. Mild congestion was noticed in the lungs. A macroscopic embolism was not observed in the main pulmonary arteries. Manual palpation revealed that the main bronchi

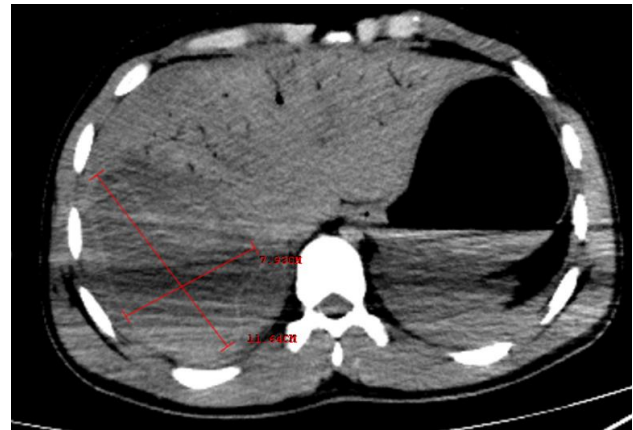


Figure 1. Type IV cyst (7.93x11.64 cm) in liver segment 7

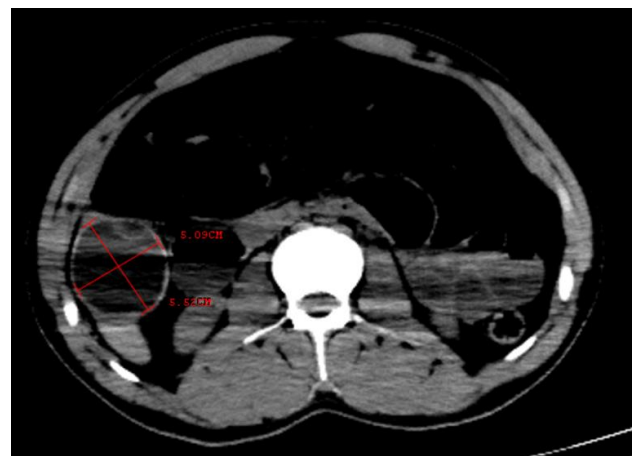


Figure 2. Type II cyst (5.52x5.09 cm) in liver segment 6

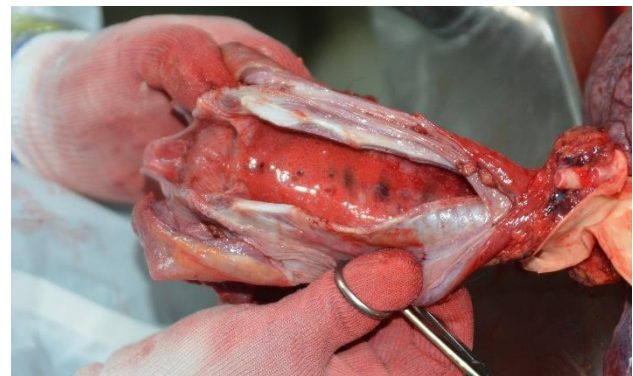

Figure 3. Hyperemia and mild edema in the larynx

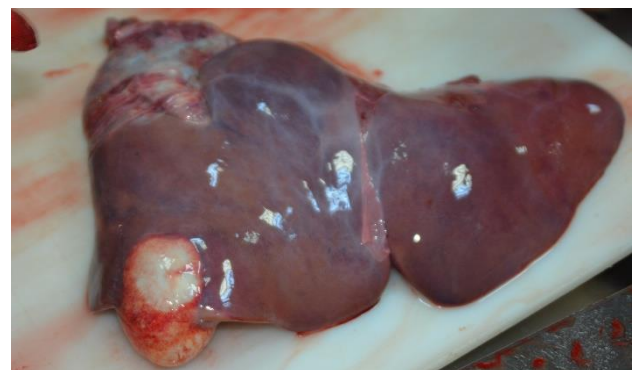

Figure 4. A cystic structure in the liver's right lobe

of the lung were emitting a bloody and foamy discharge. In the heart, brain, and other organs, macroscopically abnormal characteristics were not found, with the exception of hyperemic appearance. Any macroscopic pathological feature was not observed in the examination of the other systems. A toxic substance was not found in the toxicological analysis.

Samples of tissue were collected from the brain, spleen, kidney, lung, and liver. On the histopathological examination of liver tissue; the wall of an echinococcal cyst, germinative membrane, and multiple daughter sacs were detected. On the histopathological examination of lung tissue; diffuse intraalveolar hemorrhage, edema, severe hyperemia, neutrophil stasis in interstitial capillary lumens, and the presence of many parasites (presence of Echinococcosis) in capillary lumens were detected. As a result, it was determined that the person's death occurred due to parasitemia brought on by micro rupture in the echinococcal cyst located in the liver, along with a potential concomitant anaphylactic reaction.

DISCUSSION

Echinococcosis typically goes unnoticed for many years, but occasionally, it manifests itself at autopsy as a sudden, unexpected death brought on by an undiagnosed hydatid cyst (9). According to Ben Jomaa et al. (8), hydatid cysts were reportedly found in 0.33% (n=26) of the 7808 autopsy cases, and only 15 of these 26 instances had hydatid cysts as a contributing factor to mortality (12 anaphylaxis, 1 hydatid pulmonary embolism, 1 cardiac arrhythmia, and 1 hemothorax). The main causes of death are either complications of hepatic and pulmonary echinococcosis or cardiac hydatid cyst disease. Anaphylaxis, cardiac outflow blockage, pulmonary and cerebral embolism, pulmonary hypertension, and peritonitis are a few of the causes connected to sudden death (9).

Pulmonary artery involvement develops primarily due to the rupture of the right heart cysts. A cyst's contents draining into the venous or arterial system can lead to pulmonary or systemic embolism, chronic pulmonary hypertension, anaphylaxis, or sudden death. The rupture of the cyst inside of the hepatic vein or vena cava related to hepatic focus is among the rare causes of pulmonary embolism (2,10,11). This case fits the definition of an embolism since the cyst's contents travel down the vena cava to the right side of the heart and the pulmonary artery. An important observation for understanding how this process works is the presence of ruptured cyst content in hepatic vascular structures. The most dangerous complication in cases of hydatid cysts in the liver is the opening of the cyst to the blood vessels, which can cause anaphylactic shock and death. Rupture of the cyst and discharge into the bile duct is also a frequent complication. It is also stated that anaphylactic shock, which develops due to the intravascular spread of the cyst content due to minor abdominal trauma, can cause death without a macroscopically visible cyst rupture (3).

According to their examination, Şahpaz et al. (12) concluded that in cases of non-thrombotic pulmonary embolism due to liver hydatid cyst, the cyst was macroscopically well-defined but ruptured due to fresh hemorrhage around the cyst wall and the daughter vesicles inside the hepatic vascular structures. It is highly likely

that micro ruptures have occurred in an unruptured cyst if its contents mix with blood and move to the lung. Especially, when no other cause of death can be noticed, it is suggested that CE plays a part in the etiology and is acknowledged as the mechanism of death (8).

Although anaphylactic reactions often occur due to post-traumatic cyst rupture, recurrent anaphylaxis cases due to unruptured cysts are also rarely reported (13,14). There are very few case reports of patients with an intact hepatic hydatid cyst dying suddenly from anaphylactic shock (3,15). Concerning these cases, researchers have most often pointed to the leakage of intense antigenic cyst content into the blood circulation. While the cyst wall is intact, the cause of this leakage is considered high-intracystic pressure (15,16). According to the literature, a hydatid cyst-induced pulmonary embolism can occur in two ways: either by rupturing in the right atrium or ventricle or by hematogenous dissemination originating from a hepatic focal point. The suggested mechanism behind the latter is the micro rupturing of the cyst inside the inferior vena cava and the subsequent content dissemination into the pulmonary arteries. The research phase for postmortem contrast-enhanced CT examination is now underway. While not being utilized much in practice, it seems to be reliable for identifying cardiovascular causes of death (17). When cysts are not macroscopically ruptured, it can be helpful to demonstrate micro ruptures.

In our case, we concluded that parasite embolization from the intact liver cyst to the lungs and anaphylactic reaction were the causes of death. Especially, exercise and overeating, which will increase intra-abdominal pressure in the patient's history, may account for the formation of micro ruptures due to mechanical effects on the cyst wall. The most common autopsy findings related to anaphylaxis due to cyst hydatid constitute pulmonary congestion, alveolar hemorrhage, bronchial hypersecretion, and laryngeal and/or pharyngeal edema (9). Anaphylaxis is a macroscopically difficult diagnosis to make at autopsy. The most typical signs of anaphylaxis at autopsy are pulmonary congestion, alveolar hemorrhage, upper airway edema, bronchial hypersecretion, and laryngeal and/or pharyngeal edema. As in all cases of suspected fatal anaphylaxis, measurements of serum-specific IgE, serum tryptase and chymase levels can be helpful in cases of suspected anaphylaxis due to cyst rupture (9,18,19). In our autopsy case, serum-specific IgE, serum tryptase and chymase measurements could not be performed. In our case, every additional anaphylaxis-related finding that may be seen during an autopsy was present. Premortem epilepsy-like involuntary contractions expressed by the witnesses of our case could be related to abruptly decreased cerebral blood flow secondary to anaphylaxis as reported by Meyer et al. (20).

CONCLUSION

To conclude, undiagnosed hydatid cysts should be considered in the differential diagnosis in all cases of anaphylaxis and sudden death in regions where echinococcosis is endemic. In cases where cysts are incidentally noticed in any organ, if there is no pathology to explain death macroscopically at autopsy, anaphylaxis, and systemic embolism due to echinococcosis should be considered the causes of death.

Informed Consent: Not applicable because the study is an autopsy case. Permission was obtained from The Council of Forensic Medicine (21.06.2021, 758).

Conflict of Interest: None declared by the authors.

Financial Disclosure: None declared by the authors.

Acknowledgments: None declared by the authors.

We would like to thank for their contribution to the Council of Forensic Medicine.

Author Contributions: Idea/Concept: UA, DÇ, CÇ; Design: UA; Data Collection/Processing: DÇ, CÇ; Analysis/Interpretation: EK, AA; Literature Review: UA, DÇ, CÇ; Drafting/Writing: DÇ, CÇ; Critical Review: UA, EK, AA.

REFERENCES

- Galeh TM, Spotin A, Mahami-Oskouei M, Carmena D, Rahimi MT, Barac A, et al. The seroprevalence rate and population genetic structure of human cystic echinococcosis in the Middle East: A systematic review and meta-analysis. *Int J Surg*. 2018;51:39-48.
- Georgiou GK, Lianos GD, Lazaros A, Harissis HV, Mangano A, Dionigi G, et al. Surgical management of hydatid liver disease. *Int J Surg*. 2015;20:118-22.
- Büyük Y, Turan AA, Uzün I, Aybar Y, Cin O, Kurnaz G. Non-ruptured hydatid cyst can lead to death by spread of cyst content into bloodstream: an autopsy case. *Eur J Gastroenterol Hepatol*. 2005;17(6):671-3.
- Zaimi S, Bellamlih H, Nassar I. Hydatid pulmonary embolism: An exceptional complication of hydatid disease. *Radiol Case Rep*. 2020;15(5):545-7.
- Thameur H, Abdelmoula S, Chenik S, Bey M, Ziadi M, Mestiri T, et al. Cardiopericardial hydatid cysts. *World J Surg*. 2001;25(1):58-67.
- Ben Khelil M, Allouche M, Banasr A, Gloulou F, Benzarti A, Zhioua M, et al. Sudden death due to hydatid disease: a six-year study in the northern part of Tunisia. *J Forensic Sci*. 2013;58(5):1163-70.
- Jedidi M, Mlayeh S, Masmoudi T, Souguir MK, Zemni M. Sudden death due to hydatid cyst: thirty-four medicolegal autopsy cases. *Am J Forensic Med Pathol*. 2014;35(1):29-33.
- Ben Jomaa S, Haj Salem N, Hmila I, Saadi S, Aissaoui A, Belhadj M, et al. Sudden death and hydatid cyst: A medicolegal study. *Leg Med (Tokyo)*. 2019;40:17-21.
- Byard RW. An analysis of possible mechanisms of unexpected death occurring in hydatid disease (echinococcosis). *J Forensic Sci*. 2009;54(4):919-22.
- Dursun M, Terzibasoglu E, Yilmaz R, Cekrezi B, Olgar S, Nisli K, et al. Cardiac hydatid disease: CT and MRI findings. *AJR Am J Roentgenol*. 2008;190(1):226-32.
- Unal E, Balci S, Atceken Z, Akpinar E, Ariyurek OM. Nonthrombotic pulmonary artery embolism: imaging findings and review of the literature. *AJR Am J Roentgenol*. 2017;208(3):505-16.
- Şahpaz A, İrez A, Gülbeyaz H, Şener MT, Kök AN. Non-thrombotic pulmonary embolism due to liver hydatid cyst: a case report. *Balkan Med J*. 2017;34(3):275-7.
- Gelincik A, Özşeker F, Büyüköztürk S, Colakoğlu B, Dal M, Alper A. Recurrent anaphylaxis due to non-ruptured hepatic hydatid cysts. *Int Arch Allergy Immunol*. 2007;143(4):296-8.
- Kıraç CO, Uçar R, Arslan Ş, Taşcı Hİ, Çalışkaner AZ. Recurrent anaphylaxis: an unruptured splenic hydatid cyst as an unusual cause. *Asthma Allergy Immunol*. 2016;14(2):103-6.
- Hosseini M, Hedjazi A, Bahrami R. Sudden death due to anaphylactic shock in a patient with an intact hepatic hydatid cyst. *Am J Forensic Med Pathol*. 2014;35(4):256-7.
- Sanei B, Hashemi SM, Mahmoudieh M. Anaphylactic shock caused by nonruptured hydatid cyst of the liver. *J Gastrointest Surg*. 2008;12(12):2243-5.
- Apitzsch JC, Westphal S, Penzkofer T, Kuhl CK, Knüchel R, Mahnken AH. The use of contrast-enhanced post Mortem CT in the detection of cardiovascular deaths. *PLoS One*. 2014;9(4):e93101.
- Nishio H, Takai S, Miyazaki M, Horiuchi H, Osawa M, Uemura K, et al. Usefulness of serum mast cell-specific chymase levels for postmortem diagnosis of anaphylaxis. *Int J Legal Med*. 2005;119(6):331-4.
- Trani N, Bonetti LR, Gualandri G, Barbolini G. Immediate anaphylactic death following antibiotics injection: splenic eosinophilia easily revealed by pagoda red stain. *Forensic Sci Int*. 2008;181(1-3):21-5.
- Meyer PG, Bonneville C, Orliaguet GA, Dessemme P, Blakime P, Carli PA, et al. Grand mal seizures: an unusual and puzzling primary presentation of ruptured hepatic hydatid cyst. *Paediatr Anaesth*. 2006;16(6):676-9.