



## RESEARCH

# The effect of astaxanthin on amiodarone induced cardiac tissue damage in rat

Astaksantinın sıçanda amiodarona bağlı kardiyak doku hasarı üzerine etkisi

Özlem Kara<sup>1</sup>, Asuman Kilitçi<sup>2</sup>

<sup>1</sup>Kirsehir Ahi Evran University School of Medicine, Department of Histology and Embryology, Kirsehir, Turkey

<sup>2</sup>Duzce University School of Medicine, Department of Pathology, Duzce, Turkey

### Abstract

**Purpose:** The aim of this study was to evaluate the effect of astaxanthin on amiodarone induced cardiac tissue damage.

**Materials and Methods:** 3 groups were formed using 30 Wistar albino rats. In group 1 (control group) (n=10), neither any drugs were given nor anything was performed. In group 2 (amiodarone group) (n=10), 100 mg/kg amiodarone was given for 7 days. In group 3 (amiodarone+astaxanthin group) (n=10), 100 mg/kg amiodarone and 25 mg/kg astaxanthin were given for 7 days. Hearts were surgically extirpated in all groups. Blood malondialdehyde (MDA) levels and activities of catalase (CAT) and superoxide dismutase (SOD) were measured. Also, toxicity markers such as edema, hemorrhage, fibrosis, inflammatory cell infiltration were assessed by examining the slides prepared from cardiac tissue with microscopy.

**Results:** The MDA levels were significantly higher and the activities of SOD, and CAT were lower in group 2 than group 3. Tissue damage was significantly higher in group 2 than group 3.

**Conclusion:** According to our short term findings, astaxanthin reversed the toxicity of amiodarone on cardiac tissue. In the light of these promising results, we suggest that astaxanthin usage should be thought to protect the cardiac damage due to amiodarone.

**Keywords:** Amiodarone, astaxanthin, rat, cardiac tissue, toxicity

### Öz

**Amaç:** BU çalışmada astaksantinın amiodaron kaynaklı kalp dokusu hasarı üzerindeki etkisinin değerlendirilmesi amaçlanmıştır.

**Gereç ve Yöntem:** 30 adet Wistar albino rat kullanılarak 3 grup oluşturuldu. Grup 1'de (kontrol grubu) (n=10) herhangi bir ilaç verilmedi ve herhangi bir işlem yapılmadı. Grup 2'de (amiodaron grubu) (n=10) 7 gün boyunca 100 mg/kg amiodaron verildi. Grup 3'te (amiodaron+astaksantin grubu) (n=10) 7 gün boyunca 100 mg/kg amiodaron ve 25 mg/kg astaksantin verildi. Kalp tüm gruplarda cerrahi olarak ekstirpe edildi. Kan malondialdehid (MDA) seviyeleri ve katalaz (CAT) ve süperoksit dismutaz (SOD) aktiviteleri ölçüldü. Ayrıca kalp dokusundan hazırlanan preparatlar mikroskopla incelenerek ödem, hemoraji, fibrozis, inflamatuvar hücre infiltrasyonu gibi toksisite belirtileri değerlendirildi.

**Bulgular:** Grup 2'de grup 3'e göre MDA düzeyleri anlamlı olarak yüksek, SOD ve CAT aktiviteleri daha düşüktü. Doku hasarı grup 2'de grup 3'e göre anlamlı olarak daha yüksekti.

**Sonuç:** Kısa dönem bulgularımıza göre astaksantin, amiodaronun kalp dokusu üzerindeki toksisitesini tersine çevirdi. Bu ümit verici sonuçların ışığında, biz amiodarona bağlı kardiyak hasardan korunmak için astaksantin kullanılmasının düşünülmesini öneriyoruz.

**Anahtar kelimeler:** Amiodaron, astaksantin, sıçan, kalp dokusu, toksisite

## INTRODUCTION

Amiodarone, an iodine-rich benzofuranic derivative, is currently used as an antiarrhythmic agent in the treatment of arrhythmias such as

ventricular arrhythmias, paroxysmal supraventricular tachycardia, and atrial fibrillation<sup>1</sup>. The high iodine content of amiodarone limits its use and causes adverse effects on the thyroid and other tissues<sup>2</sup>.

Address for Correspondence: Özlem Kara, Kirsehir Ahi Evran University School of Medicine, Department of Histology and Embryology, Kirsehir, Turkey E mail: ozlemozturk34@hotmail.com

Received: 27.12.2022 Accepted: 12.02.2023

Amiodarone exhibits significant side effects such as hypothyroidism, pulmonary toxicity, hypersensitivity, hepatic injury and optic neuropathy<sup>3-5</sup>. Samarendra et al reported that amiodarone could cause prolonged QT interval and torsade de pointes<sup>6</sup>. Harb et al designed a study to assess the the effect of amiodarone on cardiac injury during status epilepticus and they reported that amiodarone treatment prevented the cardiac tissue damage due to epilepsy<sup>7</sup>. However, there is still conflict about the protective effect of amiodarone on cardiac tissue. When given for longer than 1 month, amiodarone causes a number of histological changes, including intertubular leukocyte infiltration, degeneration of the renal tubules, and glomerular atrophy<sup>8</sup>. Amiodarone inhibits the liposomal phospholipase enzyme. Also, it increases phospholipid and free radical levels, which causes cell death<sup>9</sup>.

Astaxanthin is an important xanthophyll carotenoid pigment which is found in microalgae, mushrooms, seafood, flamingos and quails and used in the food, cosmetics and feed industries<sup>10</sup>. In addition to the very strong antioxidant properties of astaxanthin; it is thought to have many properties such as protective effect against UV light photo-oxidation, anti-inflammatory, anticancer, antidiabetic, anti-ulcer effects due to *Helicobacter pylori*. Also, astaxanthin is an immunomodulatory molecule and contains a healing effect on liver, heart, eye, joint and prostate<sup>11, 12</sup>. In a study in which a diabetic retinopathy model was created, astaxanthin increased the level of oxygenase 1 enzyme and restored homeostasis in the cell<sup>13</sup>. It is known that astaxanthin has been used successfully in the treatment of many pathologies such as Alzheimer's disease, Parkinson's disease, Huntington's disease, Amyotrophic Lateral Sclerosis, and especially neurological disorders<sup>14, 15</sup>. Therefore, we thought that an antioxidant

chemical such as astaxanthin could be useful to improve the negative effects due to amiodarone. The aim of this study was to reverse the cardiac damage in rats given amiodarone with astaxanthin.

## MATERIALS AND METHODS

In this study, it was investigated whether astaxanthin was effective in cardiac tissue damage due to amiodarone in Wistar Albino rats. The amiodarone and astaxanthin used in the study were obtained from a local pharmacy.

### Study design

A total of 30 adult Wistar albino rats weighing 150-220 g were included in the study. Smaller and larger rats were not included in the study. Animals were obtained from Erciyes University Animal Experiments Department. The study was conducted at Erciyes University School of Medicine, Department of Histology and Embryology. Ethical approval of the study was received from Erciyes University Animal Experiments Local Ethics Committee. The date and number of the document of ethical approval was 07.12.2022 and 22/278, respectively. Rats were fed ad libitum feeding method with free access to water and food and were exposed to 20-22° C temperature and 12-hour light/dark periods.

The groups and given drugs are shown in Table 1. The amiodarone and astaxanthin used in the study were administered 100 mg/kg and 25 mg/kg dosages, respectively<sup>16</sup>. Ketamine hydrochloride (50 mg/kg, Ketalar, Eczacıbaşı, İstanbul, Turkey) and xylazine hydrochloride (5 mg/kg, Rompun, Bayer, Leverkusen, Germany) were administered intraperitoneally for anesthesia. Blood was collected from rats by cardiac puncture. Then, the cardiac tissues were surgically removed and the animals were sacrificed by cervical dislocation.

**Table 1. Experimental groups and given drugs.**

Number of the groups	Groups	The numbers of rats	The substance
1	Control group	10	None
2	Amiodarone group	10	amiodarone (100 mg/kg/day) 7 days
3	Amiodarone+astaxanthin group	10	amiodarone (100 mg/kg/day 7 days+ astaxanthin 25 mg/kg/day (350 µl dissolved in olive oil, oral) 7 day

### Histopathology

Tissues were fixed in formaldehyde solution and then embedded in paraffin. Sections of 5 µm in diameter were taken. Sections were stained with hematoxylin-eosin stain. In addition, staining with bcl 2 was performed immunohistochemically. Samples were examined with a light microscope (Olympus® Co. CX41 Tokyo, Japan). Damage to cardiac tissue was evaluated using the modified scoring system. Histopathological scoring was made according to the highest area. By semi-quantitative analysis; Four categories were determined (0: Absent 1: Minimal 2: Mild 3: Moderate 4: Severe) and parameters were scored accordingly<sup>17</sup>. The parameters of edema, hemorrhage, fibrosis, inflammatory cell infiltration were used to determine the degree of histopathological damage.

### Immunohistochemistry

Bcl 2 expression levels were graded using the 0-3+ range. (bcl 2; 0: no staining, 1: less than 10% nuclear staining in the heart parenchyma, 2: nuclear staining of 10-30% in the heart parenchyma, 3: more than 30% nuclear staining in the heart parenchyma).

### Biochemistry

Malondialdehyde (MDA) levels and superoxide dismutase (SOD) and catalase (CAT) activities were measured by calculating absorbance in a

spectrophotometer (Shimadzu UV 1800, Kyoto, Japan). The thiobarbituric acid test was used to calculate MDA levels<sup>18</sup>. SOD enzyme activity was determined by Marklund et al. It was calculated according to the method reported by<sup>19</sup>. CAT activity was measured as stated by Aebi et al<sup>20</sup>.

### Statistical analysis

Statistical Package for the Social Sciences (22.00 SPSS Inc., Chicago, IL) was used for statistical analysis. Power analysis was used and the sample size was calculated as at least 8 for each group with 80% accuracy. Chi-square for categorical variables and independent t-test for numerical values were used. One-way ANOVA test was used for levels of blood MDA, and activities of SOD and CAT. Tissue damage scores were compared by nonparametric chi square test. P value < 0.05 was considered statistically significant.

## RESULTS

Blood MDA levels and SOD and CAT enzyme activity levels are shown in Table 2. MDA levels in the amiodarone group were significantly higher than those in the amiodarone + astaxanthin group ( $p < 0.05$ ). When the SOD and CAT enzyme activities were compared, the values in the amiodarone group were lower than the amiodarone + astaxanthin group, the difference was statistically significant ( $p < 0.05$ ).

**Table 2. Comparison of malondialdehyde (MDA), superoxide dismutase (SOD) and catalase (CAT) levels according to groups.**

Groups (n = 10)	MDA (nmol/mg)	SOD (U/mg)	CAT (U/mg)
Control group	11.52 ± 2.93	49.78 ± 8.06	88.34 ± 14.76
Amiodarone group	27.02 ± 6.71*	17.82 ± 4.33*	32.86 ± 9.25*
Amiodarone+astaxanthin group	17.43 ± 4.10*	36.54 ± 6.27*	56.70 ± 11.31*

MDA: malondialdehyde, SOD: superoxide dismutase, CAT: catalase

Data were expressed as ± standard deviation

\* Significant difference between groups 2 and 3 ( $p < 0.05$ )

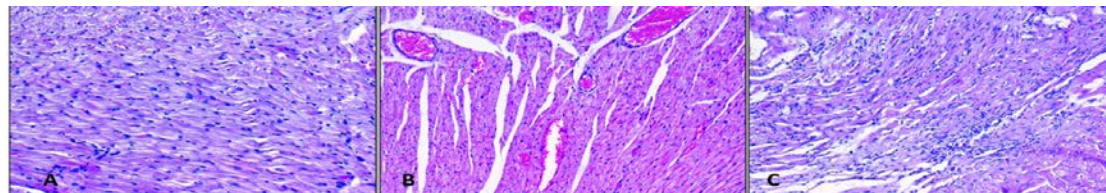
There was no difference between the groups in terms of the macroscopic appearance of the tissues. When the damage to the cardiac tissue was scored, the histopathological damage in the amiodarone group was significantly higher than the amiodarone + astaxanthin group ( $p < 0.05$ ). Damage levels in tissues are shown in Table 3.

**Table 3. Distribution of histopathological findings according to groups**

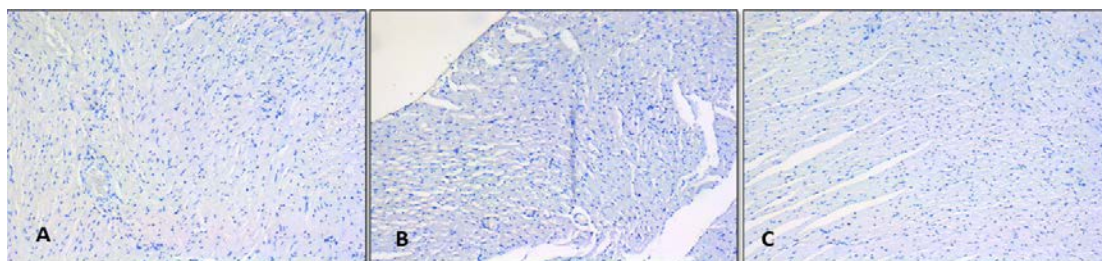
Groups (n = 10)	Edema	Hemorrhage	Fibrosis	Inflammatory cell infiltration
Control group	0	0	0	0
Amiodarone group	2*	1	2*	2*
Amiodarone+astaxanthin group	1*	1	1*	1*

\* Significant difference between groups 2 and 3 ( $p < 0.05$ ).

The highest area was determined and histopathological scoring was performed. Four categories (0: Absent 1: Minimal 2: Mild 3: Moderate 4: Severe) were determined by semi-quantitative analysis and the parameters were scored accordingly.



**Figure 1. Evaluation of the cardiac tissue with light microscopy. (A) Cardiac parenchyma view of rats in the control group (H&E, x200). (B) Cardiac parenchyma view of rats in the amiodarone group. Significant hemorrhage and inflammatory cell infiltration were observed (H&E, x200). (C) Cardiac parenchyma view of rats in the amiodarone+astaxanthin group. Local inflammatory cell infiltration and hemorrhage were observed (H&E, x200).**



**Figure 2. Evaluation of cardiac tissue with bcl 2 immunostain. (A) Cardiac parenchyma view of rats in the control group (x200). (B) Cardiac parenchyma view of rats in the amiodarone group. (x200). (C) Cardiac parenchyma view of rats in the amiodarone+astaxanthin group. (x200).**

In the control group, the parenchyma structure in the heart tissue appeared normal and the cellular architecture was intact (Figure 1A). Edema, hemorrhage, inflammatory cell infiltration and fibrosis were observed in the amiodarone group (Figure 1B). Minimal parenchymal damage was observed in the amiodarone + astaxanthin group (Figure 1C). When the preparations stained with Bcl 2 were examined, it was determined that the parenchymal destruction caused by amiodarone was reversed with astaxanthin (Figure 2A, B, C).

## DISCUSSION

In this randomized controlled experimental study, the effect of astaxanthin on the cardiac toxicity of amiodarone was investigated. To our present knowledge, this is the first study to investigate the protective effect of astaxanthin against amiodarone-induced cardiac injury. Short-term findings show that MDA levels in the amiodarone group were significantly higher than those in the amiodarone + astaxanthin group, while SOD and CAT enzyme activities were significantly lower ( $p < 0.05$ ). In addition, it was observed that tissue damage, which was more pronounced in the amiodarone group, regressed with the administration of astaxanthin. Our results were consistent with the thesis that cardiac damage and structural changes secondary to amiodarone can be reduced by administering an antioxidant.

Amiodarone, a class 3 antiarrhythmic, has many side effects such as acute liver failure, nephrotoxicity, cardiac arrest, adult respiratory distress syndrome and hypotension<sup>21</sup>. Serviddio et al. suggested that amiodarone increases mitochondrial hydrogen peroxide synthesis, resulting in increased lipid peroxidation and cell damage<sup>22</sup>. Other theories regarding the pathogenesis of amiodarone-induced toxicity include oxidative stress, free radical increase, phospholipase inhibition, membrane destabilization<sup>23</sup>.

Since oxidative stress plays an important role in the pathogenesis of amiodarone toxicity, antioxidants can be used to reduce these side

effects. Astaxanthin, which is a pigment in many plants, is a natural component that contains antioxidant, antiproliferative, anti-inflammatory properties and is also called carotenoid<sup>24</sup>. Astaxanthin, which is also obtained from algae such as *Haematococcus pluvialis* or fungi such as *Phaffia rhodozyma* and is in red, has been touted as a unique antioxidant that prevents cell and tissue damage caused by oxidative stress<sup>12</sup>. The importance of a natural and antioxidant substance, lycopene, was demonstrated to protect the damage due to oxidative stress in a previous study<sup>25</sup>. Kara et al reported that an antioxidant molecule, resveratrol, could reverse the adverse effects of oxidative stress<sup>26</sup>. Therefore, we thought that the astaxanthin molecule, which has strong antioxidant properties, may be effective in preventing amiodarone-induced cardiac toxicity.

In this study, subsequent addition of astaxanthin to rats given amiodarone resulted in a decrease in MDA levels and an increase in SOD and CAT enzyme activities. The protective effect of the astaxanthin molecule has also been confirmed histopathologically. When the parameters indicating damage were scored, the score in the amiodarone+astaxanthin group was found to be lower than that in the amiodarone group. Limitations of the study are the difficulty in adapting the findings in rats to humans and the relatively small sample size.

Astaxanthin was found to be effective in preventing amiodarone-induced cardiac damage. Our findings were promising to plan and design for new studies. In conclusion, large randomized and controlled clinical trials are necessary to evaluate the protective effect of astaxanthin on amiodarone-induced cardiac damage.

**Yazar Katkıları:** Çalışma konsepti/Tasarımı: ÖK; Veri toplama: ÖK; Veri analizi ve yorumlama: AK; Yazı taslağı: ÖK; İçeriğin eleştirel incelenmesi: ÖK, AK; Son onay ve sorumluluk: ÖK, AK; Teknik ve malzeme desteği: AK; Süpervizyon: ÖK, AK; Fon sağlama (mevcut ise): yok.

**Etik Onay:** Bu çalışma için Erciyes Üniversitesi Hayvan Deneyleri Yerel Etik Kurulundan 07.12.2022 tarih ve 22/278 sayılı kararı ile etik onay alınmıştır.

**Hakem Değerlendirmesi:** Dış bağımsız.

**Çıkar Çatışması:** Yazarlar çıkar çatışması beyan etmemişlerdir.

**Finansal Destek:** Yazarlar finansal destek beyan etmemişlerdir.

**Yazarın Notu:** Çalışmayı hazırlamamıza ve değerlendirmemize yardımcı olduğu için Prof. Dr. Mustafa Kara'ya minnettanız.

**Author Contributions:** Concept/Design : ÖK; Data acquisition: ÖK; Data analysis and interpretation: AK; Drafting manuscript: ÖK; Critical revision of manuscript: ÖK, AK; Final approval and accountability: ÖK, AK; Technical or material support: AK; Supervision: ÖK, AK; Securing funding (if available): n/a.

**Ethical Approval:** Ethical approval was obtained from the Local Ethics Committee of Animal Experiments of Erciyes University with the decision dated 07.12.2022 and numbered 22/278 for this study.

**Peer-review:** Externally peer-reviewed.

**Conflict of Interest:** Authors declared no conflict of interest.

**Financial Disclosure:** Authors declared no financial support

**Acknowledgement:** We are grateful to Prof. Dr. Mustafa KARA for helping us to prepare and evaluate the study.

## REFERENCES

- Nuttall SL, Routledge HC, Kendall MJ. A comparison of the beta1-selectivity of three beta1-selective beta-blockers. *J Clin Pharm Ther.* 2003;28:179-86.
- Ruch RJ, Bandyopadhyay S, Somani P, Klaunig JE. Evaluation of amiodarone free radical toxicity in rat hepatocytes. *Toxicol Lett.* 1991;56:117-26.
- Raeder EA, Podrid PJ, Lown B. Side effects and complications of amiodarone therapy. *Am Heart J.* 1985;109:975-83.
- Zhong B, Wang Y, Zhang G, Wang Z. Environmental iodine content, female sex and age are associated with new-onset amiodarone-induced hypothyroidism: a systematic review and meta-analysis of adverse reactions of amiodarone on the thyroid. *Cardiology.* 2016;134:366-71.
- Johnson LN, Krohel GB, Thomas ER. The clinical spectrum of amiodarone-associated optic neuropathy. *J Natl Med Assoc.* 2004;96:1477-91.
- Samarendra P, Kumari S, Evans SJ, Sacchi TJ, Navarro V. QT prolongation associated with azithromycin/amiodarone combination. *Pacing Clin Electrophysiol.* 2001;24:1572-4.
- Harb IA, Ashour H, Mostafa A, El Hanbuli HM, Nadwa EH. Cardioprotective effects of amiodarone in a rat model of epilepsy-induced cardiac dysfunction. *Clin Exp Pharmacol Physiol.* 2022;49:406-18.
- Sakr SA, El-Gamal EM. Effect of grapefruit juice on amiodarone induced nephrotoxicity in albino rats. *Toxicol Ind Health.* 2016;32:68-75.
- Somani P, Bandyopadhyay S, Klaunig JE, Gross SA. Amiodarone- and desethylamiodarone-induced myelinoid inclusion bodies and toxicity in cultured rat hepatocytes. *Hepatology.* 1990;11:81-92.
- Pan S, Chenkai Z. Biological and neurological activities of astaxanthin (Review). *Mol Med Rep.* 2022;26:300.
- Zheng YF, Bae SH, Kwon MJ, Park JB, Choi HD, Shin WG. Inhibitory effects of astaxanthin,  $\beta$ -cryptoxanthin, canthaxanthin, lutein, and zeaxanthin on cytochrome P450 enzyme activities. *Food Chem Toxicol.* 2013;59:78-85.
- Guerin M, Huntley ME, Olaizola M. Haematococcus astaxanthin: applications for human health and nutrition. *Trends Biotechnol.* 2003;21:210-6.
- Baccouche B, Benlarbi M, Barber AJ. Short-term administration of astaxanthin attenuates retinal changes in diet-induced diabetic psammomys obesus. *Curr Eye Res.* 2018;43:1177-89.
- Wu H, Niu H, Shao A, Wu C, Dixon BJ, Zhang J. Astaxanthin as a potential neuroprotective agent for neurological diseases. *Mar Drugs.* 2015;13:5750-66.
- Grimmig B, Kim SH, Nash K, Bickford PC, Shytle RD. Neuroprotective mechanisms of astaxanthin: A potential therapeutic role in preserving cognitive function in age and neurodegeneration. *Geroscience.* 2017;39:19-32.
- Bas SS, Turkyilmaz IB, Bolkent S, Yanardag R. The influence of vitamin U supplementation on liver injury of amiodarone-administered rats. *IUFS J Biol.* 2016;75:1-10.
- Kara O, Kilitci A. The protective effect of resveratrol on cisplatin induced damage in rat liver. *Med Bull Haseki.* 2022;60:392-6.
- Ohkawa H, Ohishi N, Yagi K. Assay for lipid peroxides in animal tissues by thiobarbituric acid reaction. *Anal Biochem.* 1979;95:351-358.
- Marklund S, Marklund G. Involvement of superoxide anion radical in the autoxidation of pyrogallol and a convenient assay for superoxide dismutase. *Eur J Biochem.* 1974;47:469-74.
- Aebi H. Catalase in vitro. *Methods Enzymol.* 1984;105:121-6.
- Campbell N, Agarwal K, Alidoost M, Miskoff JA, Hossain M. Acute fulminant hepatic failure and renal failure induced by oral amiodarone: a case report and literature review. *Cureus.* 2020;12:e8311.
- Serviddio G, Bellanti F, Giudetti AM, Gnoni GV, Capitanio N, Tamborra R. Mitochondrial oxidative stress and respiratory chain dysfunction account for liver toxicity during amiodarone but not dronedarone administration. *Free Radic Biol Med.* 2011;51:2234-42.
- Ray S, Bagchi D, Lim PM, Bagchi M, Gross SM, Kothari SC. Acute and long-term safety evaluation of a novel IH636 grape seed proanthocyanidin extract. *Res Commun Mol Pathol Pharmacol.* 2001;109:165-97.
- Mularczyk M, Michalak I, Marycz K. Astaxanthin and other nutrients from haematococcus pluvialis-multifunctional applications. *Mar Drugs.* 2020;18:459.
- Kirmizi DA, Baser E, Okan A, Kara M, Yalvac ES, Doganyigit Z. The effect of a natural molecule in ovary ischemia reperfusion damage: does lycopene protect ovary? *Exp Anim.* 2021;70:37-44.
- Kara O, Kilitci A, Daglioglu G. Protective effect of resveratrol on cisplatin induced damage in rat kidney. *Cukurova Med J.* 2022;47:990-5.