

**RESEARCH
ARTICLE**

Berin Tugtag Demir¹
Dilara Patat¹

¹ Department of Anatomy, Faculty of
Medicine, Ankara Medipol University,
Ankara, Türkiye

Corresponding Author:

Berin Tugtag Demir

mail: berin.tugtag@ankaramedipol.edu.tr

Received: 04.01.2023
Acceptance: 01.03.2023
DOI: 10.18521/kt.1229112

This study was presented at the
3rd International Congress on
Sports, Anthropology, Nutrition,
Anatomy and Radiology
(SANAR2022), 6-8 October 2022.

Konuralp Medical Journal
e-ISSN1309-3878
konuralptipdergi@duzce.edu.tr
konuralptipdergisi@gmail.com
www.konuralptipdergi.duzce.edu.tr

Morphological and Morphometric Analysis of Hypoglossal Canal and Its Importance in Cranial Base Surgery: A Skull Study

ABSTRACT

Objective: This study aims to analyze the morphological and morphometric features of the hypoglossal canal (HC) and its topographical relationship with the occipital condyle (OC) and to present guiding information to the relevant field experts.

Method: This research was carried out with 33 adult Turkish skulls of unknown gender. Typing definitions of the skulls without damage to the posterior cranial fossa were made with the parameters related to a standard caliper and a protractor.

Results: The distance of the extracranial opening of the HC to the posterior end of the OC was 14.37±1.76 mm on the right side and 16.37±1.76 mm on the left ($p<0.05$), while the intracranial opening was determined to be greater than that of the OC and its distance to the posterior end was calculated as 8.95±1.00 mm on the right side and 10.41±1.24 mm on the left side ($p<0.05$). The angle between the extracranial opening of the HC/pharyngeal tubercle was 45.97±2.06 degrees on the right side and 48.05±2.97 degrees on the left side ($p<0.05$). It was determined that Type I was observed most frequently on the right side with a rate of 42.42% and on the left side with a rate of 18.18%. Bilaterally, only Type I and Type II b were detected.

Conclusion: We believe that our research will guide surgeons, anatomists, and anthropologists in terms of making transcondylar, supracondylar, and lateral suboccipital approaches and examining the canal differences in Turkish society.

Keywords: Supracondylar Approach, Hypoglossal Canal, Occipital Condyle, Osteotic Variations.

Canalis Nervi Hypoglossi'nin Morfolojik/Morfometrik Analizi ve Kranial Taban Ameliyatlarında Önemi: Kuru Kafatası Çalışması

ÖZET

Amaç: Bu çalışmanın amacı canalis nervi hypoglossi'nin morfolojik ve morfometrik özelliklerini ve condylus occipitalis ile topografik ilişkisini analiz ederek ilgili alan uzmanlarına yön gösterici bilgileri sunmaktır.

Gereç ve Yöntem: Bu araştırma cinsiyeti bilinmeyen 33 yetişkin Türk kafatası ile yapılmıştır. Fossa cranii posterior hasarı olmayan kafataslarının standart kumpas ve bir açı ölçer ile ölçülerek ilgili parametreler ile tiplendirme tanımlamaları yapıldı.

Bulgular: Canalis nervi hypoglossi'nin ekstrakraniyal açıklığının condylus occipitalis'in arka ucuna olan mesafesi sağ tarafta 14,37±1,76 mm, sol tarafta ise 16,37±1,76 mm ($p<0,05$) olarak belirlenirken intrakraniyal açıklığın condylus occipitalis'in arka ucuna olan mesafesi ise sağ tarafta 8,95±1,00 mm, sol tarafta 10,41±1,24 mm ($p<0,05$) olarak hesaplanmıştır. Tuberculum pharyngeum-canalıs nervi hypoglossi'nin ekstrakraniyal açıklığı arasındaki açının sağ tarafta 45,97±2,06 derece, sol tarafta ise 48,05±2,97 derece olduğu belirlenmiştir ($p<0,05$). En fazla Tip I'in sağ tarafta %42,42, sol tarafta ise %18,18 oranında gözleendiği belirlendi. Bilateral olarak sadece Tip I ile Tip II b tespit edilmiştir.

Sonuç: Canalis nervi hypoglossi'nin osteotik varyasyonları, içinden geçen hassas nörovasküler yapılar açısından klinik olarak önemlidir. Literatürde yer alan farklı ırklardaki dış açıklığın canalis nervi hypoglossi'nin midsagittal düzleme olan sağ ve sol eğim açısı daha fazla iken araştırmamızda Türk toplumuna ait kafataslarındaki bu açıların daha az olduğu ve canalis nervi hypoglossi ile condylus occipitalis arasındaki mesafelerin diğer popülasyonlara oranla daha kısa olduğu tespit edilmiştir. Dolayısı ile araştırmamızın transkondiler, suprakondiler ve lateral subokspital yaklaşım yapmak ve Türk toplumuna ait kanal farklılıklarını incelemek açısından cerrahlar, anatomistler ve antropologlara yol gösterici olacağı kanaatindeyiz.

Anahtar Kelimeler: Suprakondiler Yaklaşım, Canalis Nervi Hypoglossi, Condylus Occipitalis, Osteotik Varyasyonlar

INTRODUCTION

Hypoglossal canal (HC), is a narrow canal located in the anterolateral of the foramen magnum (FM), in front of the occipital condyle (OC) and inferomedial of the jugular foramen, through which the meningeal branch of the pharyngeal artery, small vein plexuses and hypoglossal nerve pass (1-3). Since HC is adjacent to the occipital lobe, cerebellum and brain stem in terms of location and morphology, it has the feature of a land-marker for surgical intervention in skull base variations and pathologies in this region (tumors, aneurysms, congenital or acquired malformations and trauma). Therefore, it is clinically very important to know the anatomy of the HC located in the posterior cranial fossa in order to determine the appropriate surgical approach (4,5).

Lesions of HC are usually benign and rare. They include hypoglossal posterior cranial fossa meningiomas, schwannomas, and jugular-tympanic paragangliomas. The outcome of surgically curing these lesions is linked to the size and type of tumor and the anatomical variations of HC. Therefore, knowing the morphometric details of HC and its relationship with neighboring structures provides wider access and a better surgical angle for safe and successful surgery (6). The distant lateral transcondylar approach and its modifications require extensive vertebral artery dissection, HC exposure, and removal of OCs and the jugular tubercle. Random manipulations during condylectomy may damage the jugular vein, vertebral artery and bulb (6), also may cause craniocervical instability by damaging the lower cranial nerves (4). In addition, the supracondylar approach, which is part of the distant lateral transcondylar approach, provides access to the medial area of the HC and the jugular tubercle. During this procedure, the meningeal branches of ascending pharyngeal artery and the hypoglossal nerve in the HC may be damaged (7). It is important to know the anatomy of this region in order to prevent damage during the surgical intervention (6-15).

When the literature was examined; it has been observed that there is not enough data on osteotic variations in HC and its relationship with PT and OC in Turkish population. Therefore, the aim of this study is to analyze the morphological and morphometric features of HC. In briefly, knowing the morphometry of this region well can provide a safe surgical procedure for supracondylar, transcondylar and lateral suboccipital approaches. Preoperative morphometric analysis of HC will support the surgeon in selecting the most suitable surgical practice and approach to be used.

MATERIAL AND METHODS

Study Design: This research was carried out with 33 adult craniums of unknown gender found in the Anatomy laboratories of Ankara Medipol University and Erciyes University Faculty of

Medicine. Approval was obtained from the Ethics Committee of Ankara Medipol University Faculty of Medicine in order to conduct the study (19.09.2022/161).

Inclusion Criteria: Skulls with preserved bone integrity and no structural defect were included in the study.

Exclusion Criteria: Bones with fractured right-left hypoglossal canal were excluded from the study.

Morphological

Measurements:

Measurements were made by selecting craniums that were not damaged in the posterior cranial fossa. All measurements were performed using Berin's protocols of Kumar et al. (16), Muthukumar et al. (17), and Naderi et al. (18)

The Determined Parameters on the External Skull Base:

- The distance of the extracranial opening of the HC from the posterior end of the occipital condyle (OC)
- Distance of the intracranial opening of the HC from the posterior end of the OC
- Distance between HC-intracranial opening - Opisthion (mm)
- Distance between HC-extracranial opening - Opisthion (mm)
- Distance between HC-intracranial opening - Basion (mm)
- Distance between HC-extracranial opening - Basion (mm)
- Distance of HC from the anterior edge of the intracranial opening to the OC (mm)
- Diameter of the intracranial opening of the HC (mm²)
- Diameter of the extracranial opening of the HC (mm²)
- Length of the hypoglossal canal
- The distance of the HC from the intracranial opening to the jugular foramen (JF)
- The distance of the extracranial opening of the HC to the JF (mm)
- Angle of inclination of HC to the midsagittal plane (in degree)*
- Angle between pharyngeal tubercle and extracranial opening of HC (in degree)*
- Angle where two HCs intersect each other in the posterior (in degree)*
- Angle between the pharyngeal tubercle and the extracranial openings of two opposite HCs (in degree)*

In addition, the morphological variability of HC due to the presence of spurs, incomplete and complete septa was examined in the study. These morphological variations of HC were defined on the axis of typing described by Kumar et al. (16) Classification of morphological variations in the HC into different types

***Type I** - No evidence of bony spur or septum

***Type II** - Spur HC

- A. Spur present near external opening of HC
- B. Spur present near internal opening of HC
- C. Spur present in the middle part of HC

***Type III** - Incomplete septa dividing a portion of HC into two parts

- A. Septa present near external opening dividing it into double external opening
- B. Septa present near internal opening dividing it into double internal opening
- C. Septa present in the middle part dividing a portion of HC into two

***Type IV** - Complete septa dividing whole HC into two parts

Statistical Analysis: The statistical analysis was performed using SPSS version 22.00. Right and left sides were investigated with student's t-test. The relationship between the variables was

analyzed with the pearson's correlation test. A significance level of was assumed as $p < 0.05$.

RESULTS

Morphological measurements of HC are given in Table 1. The mean distance of the extracranial opening of the HC to the posterior end of the OC was 14.37 ± 1.76 mm on the right side and 16.37 ± 1.76 mm on the left side. The mean distance of the intracranial opening to the posterior end of the OC was determined as 8.95 ± 1.00 mm on the right side and 10.41 ± 1.24 mm on the left side. It was observed that both measurements were statistically significantly higher on the left side. Measurements related to the extracranial and intracranial openings of HC are given in Table 1 and statistical significance was not found between the right and left sides.

Table 1. Morphological measurements of HC

	Right (mm)		Left (mm)		<i>p</i>
	Range	Mean	Range	Mean	
The distance of the extracranial opening of the HC from the posterior end of OC (mm)	11.9-18.9	14.37 ± 1.76	9.14-18.21	16.37 ± 1.76	.021
Distance of the intracranial opening of the HC from the posterior end of the OC (mm)	7.01-11.10	8.95 ± 1.00	7.41-12.13	10.41 ± 1.24	.041
Distance between HC-intracranial opening - Opisthion (mm)	9.72-37.24	29.42 ± 4.81	20.22-34.78	29.61 ± 3.01	.420
Distance between HC-extracranial opening-Opisthion (mm)	23.41-43.02	38.70 ± 3.57	22.43-43.37	39.05 ± 3.78	.797
Distance between HC-intracranial opening-basion (mm)	9.29-17.49	12.83 ± 1.87	9.87-17.39	12.88 ± 1.68	.471
Distance between HC-extracranial opening - basion (mm)	14.48-40.21	17.52 ± 4.33	13.85-42.33	17.96 ± 4.65	.915
Distance of HC from the anterior edge of the intracranial opening to the OC (mm)	6.66-12.32	9.28 ± 1.31	7.02-77.81	11.86 ± 11.94	.125
Diameter of the intracranial opening of the HC (mm ²)	1.15-7.29	4.68 ± 1.27	1.23-2.95	4.35 ± 2.12	.238
Diameter of the extracranial opening of the HC (mm ²)	1.67-5.81	3.78 ± 1.17	1.37-8.15	4.17 ± 1.51	.695
Length of hypoglossal canal (mm)	5.38-15.03	11.24 ± 2.24	6.00-14.51	11.11 ± 2.09	.700
The distance of the HC from the intracranial opening to the JF (mm)	4.13-12.31	7.85 ± 1.90	1.68-14.38	8.12 ± 2.77	.342
The distance of the extracranial opening of the HC to the JF (mm)	7.21-15.23	10.86 ± 2.04	7.99-13.25	10.82 ± 1.43	.061

HC: Hypoglossal canal, OC: Occipital condyle, JF: Jugular foramen

The distance between the right and left hypoglossal canal was determined as 24.39 ± 4.93 mm from the inner rim and 32.25 ± 2.48 mm from the outer rim, and it was determined that there was statistical significance between the inner and outer rims. HC showed an angulation of 26.64 ± 2.97 degrees on the right and 26.03 ± 2.97 degrees on the left in the midsagittal plane; The angle formed

when two opposing HCs merged in the pharyngeal tubercle was found to be 84.90 ± 6.89 degrees (Table 2). It was determined that the angle between the extracranial opening of the pharyngeal tubercle (TP)-HC was 45.97 ± 2.06 degrees on the right side and 48.05 ± 2.97 degrees on the left side, and the difference was statistically significant ($p < 0.05$, Table 2, Figure 1).

Table 2. Angular measurements of HC

	Right	Left	p
Angle of inclination of HC to midsagittal plane (in degree)*	26.64±2.97	26.03±2.97	0.53
Angle between pharyngeal tubercle and extracranial opening of HC (in degree)*	45.97±2.06	48.05±2.97	0.043
Angle where two HCs intersect each other in the posterior (in degree)*		51.04±4.28	
Angle between the pharyngeal tubercle and the extracranial orifices of two opposite HCs (in degree)*		84.90±6.89	

HC: Hypoglossal canal

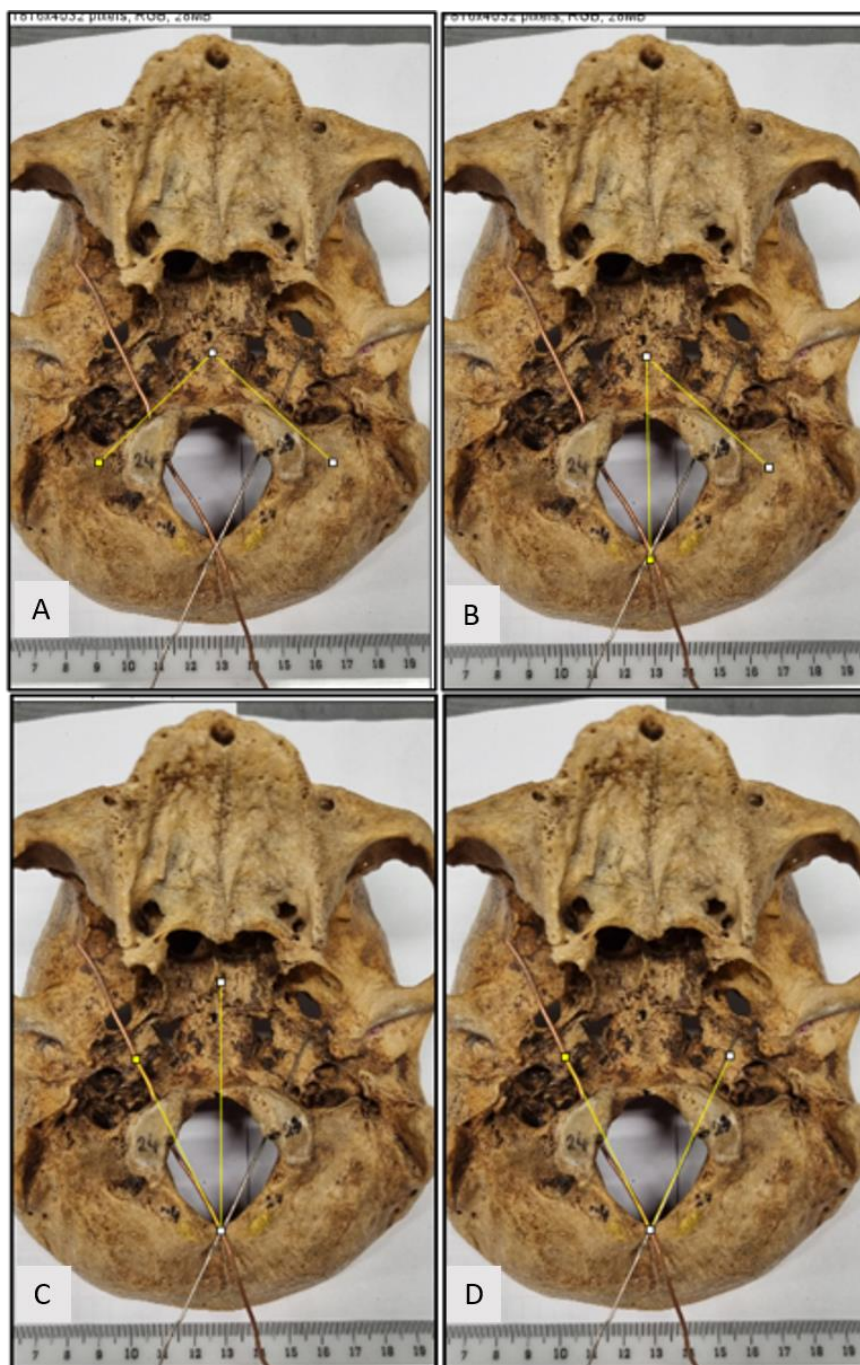


Figure 1. A: Pharyngeal tubercle-angle between the extracranial openings of two opposite HCs, B: Angle between pharyngeal tubercle-extracranial openings of HC C: Angle of inclination of HC to midsagittal plane (in degree), D: Angle where two HCs intersect each other in the posterior

The incidence rates of variations of HC are given in Table 3. Accordingly, it was determined that Type I was the most common, with a rate of 42.42% on the right side and 18.18% on the left side. It was determined that Type II B, which is the

second most common type, was observed with a rate of 12.12% on the right side and 21.21% on the left side. Bilaterally, only Type I and Type II b were detected (Table 3, Figure 2,3).

Table 3. Morphological parameters of HC- Frequency of osteotic variations in HC and its distribution in 33 dry skulls.

Side	Type	Right		Left		
		N	%	N	%	
Unilateral	Tip I	14	42.42	6	18.18	
	Tip II	A	1	3.03	1	3.03
		B	4	12.12	7	21.21
		C	-	-	2	6.06
	Tip III	A	1	3.03	1	3.03
		B	1	3.03	5	15.15
		C	1	3.03	1	3.03
Bilateral	Tip IV	1	3.03	-	-	
	Tip I	8	24.24	8	24.24	
	Tip II B	2	6.06	2	6.06	
	Toplam	33	100	33	100	

* Significant $p < 0.05$. **in case of double internal opening of HC (type 3). anterior opening was considered along with the single internal opening of the HC (Type1 and Type 2). *** in case of double internal opening of HC (type 3). posterior opening was considered
 HC: Hypoglossal canal

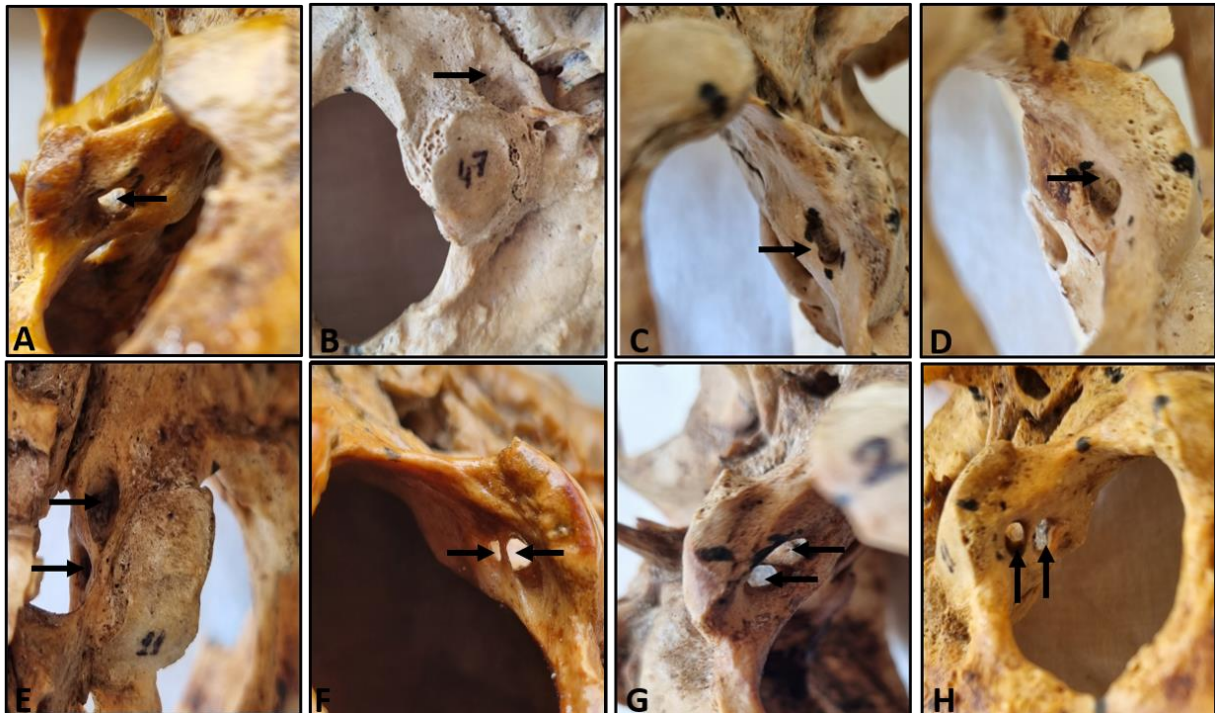


Figure 2. Image of hypoglossal canal variations A: TypeI, B: TypeIIA, C: TypeIIB, D: TypeIIC, E: TypeIIIA, F: TypeIIIB, G: TypeIIIC, H: TypeIV

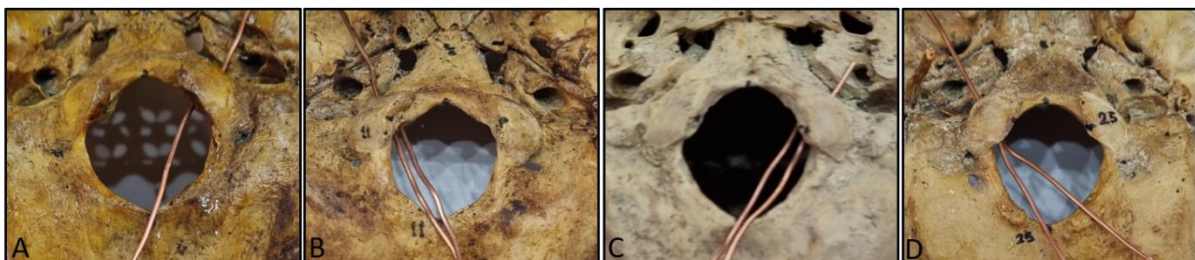


Figure 3. Canal view according to internal and external canal openings A: Single canal opening in both sections, B: Two canal openings in the internal section and one canal opening in the external section for the right hypoglossal canal, C: Two canal openings in the internal and external section for the left hypoglossal canal one duct opening, D: Two duct openings in both sections

DISCUSSION

To understand the skull base morphology in detail and to know the regional variations is a prerequisite for surgical interventions to the skull base, especially the distant lateral approach (11,19,20). It has been reported in many studies that high mortality and morbidity are observed in skull base surgery when the surgical procedure is started without detailed morphological analysis (21,22). Therefore, defining the localization of HC is extremely important both for its proximity to environment structures and for remove of tumors located near or within the canal (23-26). Therefore, we think that the current anatomy should be evaluated by making a detailed analysis in order to improve surgical techniques and facilitate safe surgical to the cranial base. This research was

conducted to investigate the morphometric and morphological analysis of HC from an anatomical and clinical perspective.

In this study, the mean length of the HC was 11.24 ± 2.24 mm on the right side and 11.11 ± 2.09 mm on the left side, while the mean intracranial diameter of the canal was 4.68 ± 1.27 mm² on the right side and 4.35 ± 2.12 mm² on the left side. The mean extracranial diameter was calculated as 3.78 ± 1.17 mm² on the right side and 4.17 ± 1.51 mm² on the left side. In a study conducted with the Greek population, the intra and extracranial diameters were 5.93 mm² and 5.03 mm²; respectively (26). In another study conducted on Americans and Egyptians, the intracranial diameter was calculated as 5.65 mm² and the extracranial diameter was calculated as 5.15 mm² (Table 4) (22).

Table 4. Comparison of the incidence of spur and septa. length. Internal/external diameter and in the HC with previous studies.

Researchers	Year	Population	HC length	Extracranial Diameter (mm ²)	Intracranial Diameter (mm ²)	Spur	Incomplete septa		Complete septa
							Intracranial opening	Extracranial opening	
Our study	2022	Turkish	11.18	3.98	4.52	%22.73	%9.1	%3.03	%1.52
Kumar et al.	2017	North Indian	-	-	-	%28	%26	%4	-
Peraskavas et al.	2009	Greek	9.58	5.03	5.93	%18.9	%19.8	-	%1.7
Katsuta T et al.	2000	US and Indian	8.95	5.15	5.65	%10	-	-	-
Bastianini A et al.	1985	Sieneese	-	-	-	%35	-	-	-

HC: Hypoglossal canal

The fact that the canal diameter of the Turkish population was found to be smaller in our study compared to other populations suggests that surgeons should pay attention to the diameters of the openings when determining the range of motion in tumor removal operations.

Tumors such as jugulo-tympanic paragangliomas, posterior cranial fossa meningiomas, hypoglossal nerve schwannomas and are frequently seen in HC (24). Vascular lesions of the vertebral artery, dural tumors and congenital lesions are among the commonly encountered lesions around the FM and the caudal surface of the superior cervical spine, lower clivus, which are closely related to HC. Therefore, any osteotic variation in HC will further complicate the pathological conditions mentioned and force surgeons to increase their awareness of these variations (25). Osteotic variations of HC are clinically important for the delicate neurovascular structures that pass through them. The spurs and partitions in the channel will divide the channel into compartments that can compress these structures. In our study, both spur and septa were more common on the left side, while Paraskevas GK et al. (26) observed more frequent variation on the right side in the Greek population. While the incidence of spurs was reported as 18.96% by Paraskevas et al., 35% by Bastianini et al. and 28% by Kumar et al., it was determined as 22.73% in our study.

In the study of Kumar et al., it was observed that incomplete septa formation was more common in the HC internal aperture (26%) than in the external aperture (4%) of the North Indian population (16). Similarly, in our study, it was found that the incidence of septa formation in the inner opening of the canal (9.1%) was higher than the external opening (3.03%). In addition, spur formation was observed in the bilateral internal opening (6.06%) in 2 skulls, while no spur or septa formation was observed bilaterally in either the internal or external opening (24.24%) in 8 skulls. This situation guides surgeons against nerve damage regarding whether the structures passing through the canal, especially the hypoglossal nerve, show division during the intervention to the canal.

While completed septa formation was observed in the Greek population at a rate of 1.7% in the study of Paraskevas et al. (26), it was detected at a rate of 1.52% in our study and was observed to separate the right-sided HC into two channels. Although it is a rare condition; the presence of dividing channels can be encountered in Turkish and Greek populations.

In addition, when drilling OC, the operating needs to estimate the probable bottom and aspect of the HC.²⁸ In this study, the mean distance of the posterior end of the OC to the outer and inner openings of the HC was 14.37 ± 1.76 and 8.95 ± 1.00 mm on the right side, and 16.37 ± 1.76 and 10 on the

left side, respectively. Similar to our study, Kumar et al., Muthukumar et al., Kızılkant et al. and Parvindokht et al. declared that the distance of HC to the posterior edge of the OC varies between 11.42-12.3 mm (16,17,23,27). While the measurements in these studies were higher than our measurements, the results of Wen et al. (6) were lower than our results. According to the results of studies on the OC and HC relationship that differs between populations, a wider area can be used during the supracondylar approach to the canal in Northern and Southern Egyptian and Iranian populations, while a narrower intervention area should be used in the Turkish population.

In our study, the right inclination angle of the external opening of the HC to the midsagittal plane was found to be higher than the left inclination angle. The tilt angle indicated by Muthukumar et al. (17) and Paraskevas et al. (26) was higher than in our study. Accordingly, the angle of inclination to be calculated for the far lateral approach in the Turkish population should be made more parallel and closer to the midline compared to other populations.

PT is the central point of the nasopharynx also is important for both breathing and swallowing together with the adjacent anatomical structures. In spite of the significance of this area, the deficiency of the number of evaluations and the lack of research on its relationship with HC required us to

survey this region in elaboration morphometric (11). In our study, we determined the angle between the pharyngeal tubercle and the extracranial opening of the HC as $45.97 \pm 2.06^\circ$ on the right, $48.05 \pm 2.97^\circ$ on the left, and the angle between the PT and the extracranial openings of the two opposite HCs as $84.90 \pm 6^\circ$. In the surgery of this region, it should be kept in mind that the hypoglossal nerve may be within an angle of $45-50^\circ$ when intervening from the midline, and within an angle of $80-85^\circ$ in lateral approaches. In conclusion, in skull base surgery performed in the pharyngeal tubercle and craniocervical region tumors, attention should be paid to the position of the external opening of the HC and its angulation to the midline, and the difference in angulation on the right and left sides should be considered.

CONCLUSION

In studies of different populations in the literature, the left inclination angle of the external aperture HC to the midsagittal plane is higher than the right inclination angle, whereas in our study, these angles in the skulls of Turkish populations are less and the distances between HC and OC are shorter than in other populations. Therefore, we believe that our study will guide surgeons who perform transcondylar, supracondylar and lateral suboccipital approach surgeries, as well as anatomists and anthropologists in terms of examining the canal differences of Turkish society.

REFERENCES

1. Snell RS. Clinical Anatomy for Medical Students. 3rd ed. Boston: Little, Brown and Company. 1986;794–795.
2. Soames RW. Skeletal system. In: Bannister LH, Berry MM, Collins P, editors. Gray's Anatomy 38th ed. NY: ELBS with Churchill Livingstone. 1995;567–573.
3. Uysal S, Gokharman D, Kacar M, Tuncbilek I, Kosa U. Estimation of sex by 3D CT measurements of the foramen magnum. J Forensic Sci. 2005;50(6): 1310–1314.
4. Boulton MR, Cusimano MD. Foramen magnum meningiomas: concepts, classifications, and nuances. Neurosurg Focus. 2003; 14(6): e10, indexed in Pubmed: 15669785.
5. Radhakrishna SK, Shivarama CH, Ramakrishna A, Bhagya B. Morphometric analysis of foramen magnum for sex determination in South Indian population. NUJHS. 2012;2:20–22.
6. Wen HT, Rhoton AL Jr, Katsuta T, de Oliveira E. Microsurgical anatomy of the transcondylar, supracondylar, and paracondylar extensions of the far-lateral approach. J Neurosurg. 1997;87(4): 555-585.
7. de Oliveira E, Rhoton AL, Jr., Peace D. Microsurgical anatomy of the region of the foramen magnum. Surg Neurol. 1985;24(3):293-352.
8. Matsushima T, Natori Y, Katsuta T, Ikezaki K, Fukui M, Rhoton AL. Microsurgical anatomy for lateral approaches to the foramen magnum with special reference to transcondylar fossa (supracondylar transjugular tubercle) approach. Skull Base Surg. 1998;8(3):119-25.
9. Perneczky A. The Posterolateral Approach to the Foramen Magnum. In: Samii, M. (eds) Surgery in and around the Brain Stem and the Third Ventricle. Springer, Berlin, Heidelberg 1986.
10. Rhoton AL, Jr. The foramen magnum. Neurosurgery. 2000;47(3 Suppl): S155-193.
11. Rhoton AL, Jr. The far-lateral approach and its transcondylar, supracondylar, and paracondylar extensions. Neurosurgery 2000;47(3 Suppl):S195-209.
12. Matsushima K, Kawashima M, Matsushima T, Hiraishi T, Noguchi T, Kuraoka A. Posterior condylar canals and posterior condylar emissary veins-a microsurgical and CT anatomical study. Neurosurgical review. 2014;37(1):115-126.
13. Ginsberg LE. The posterior condylar canal. AJNR Am J Neuroradiol. 1994;15(5):969-972.
14. Gilsbach JM, Sure U, Mann W. The supracondylar approach to the jugular tubercle and hypoglossal canal. Surg Neurol. 1998;50(6):563-570.

15. Wanebo JE, Chicoine MR. Quantitative analysis of the transcondylar approach to the foramen magnum. *Neurosurgery*. 2001;49(4):934-943.
16. Kumar S, Verma R, Rai AM, Mehra RD. Morphological and Morphometric Analysis of Hypoglossal Canal in North Indian Dry Skulls and It's Significance in Cranial Base Surgeries. *J Clin Diagn Res*. 2017;11(3):3-7.
17. Muthukumar N, Swaminathan R, Venkatesh G, Bhanumathy SP. A morphometric analysis of the foramen magnum region as it relates to the transcondylar approach. *Acta Neurochir (Wien)*. 2005;147(8):889-895.
18. Naderi S, Korman E, Çıtak G, Güvençer M, Arman C, Şenoğlu M, Tetik S, Arda MN. Morphometric analysis of human occipital condyle. *Clinical Neurology and Neurosurgery* 2005;107:191-199.
19. Voyvodic F, Whyte A, Slavotinek J. The hypoglossal canal: normal MR enhancement pattern. *AJNR Am J Neuroradiol*. 1995;16(8):1707-1710.
20. Tatagiba M, Koerbel A, Roser F. The midline suboccipital subtonsillar approach to the hypoglossal canal: surgical anatomy and clinical application. *Acta Neurochir (Wien)* 2006;148(9): 965-969.
21. Wanebo JE, Chicoine MR. Quantitative analysis of the transcondylar approach to the foramen magnum. *Neurosurgery*. 2001;49(4): 934-943.
22. Katsuta T, Matsushima T, Wen HT, Rhoton AL Jr. Trajectory of the hypoglossal nerve in the hypoglossal canal: significance for the transcondylar approach. *Neurol Med Chir (Tokyo)*. 2000;40(4):206-210.
23. Kizilkanat ED, Boyan N, Soames R, Oguz O. Morphometry of the hypoglossal canal, occipital condyle and foramen magnum. *Neurosurgery*. 2006;16(3):121-25.
24. Singh V, Sethi R, Kharb P, Singh R. Bridging pattern of hypoglossal canal Reclassified. *J Anat Soc India*. 2014;63:S31-S34.
25. Babu RP, Sekhar LN, Wright DC. Extreme lateral transcondylar approach: technical improvements and lessons learned. *J Neurosurg*. 1994;81(1):49-59.
26. Paraskevas GK, Tsitsopoulos PP, Papaziogas B, Kitsoulis P, Spanidou S, Tsitsopoulos P. Osseous variations of the hypoglossal canal area. *Med Sci Monit*. 2009;15(3):BR75-BR84.
27. Parvindokht B, Reza DM, Saeid B. Morphometric analysis of hypoglossal canal of the occipital bone in Iranian dry skulls. *J Craniovertebr Junction Spine* 2015; 6(3): 111-114.
28. Saddler TW. Langman's Medical Embryology, Development of Head & Neck. Philadelphia, USA: Wolter and Kluwer; 11th ed. 2009; 265-291.