



## RETROSPECTIVE ANALYSIS OF 48 PATIENTS REOPERATED FOR CARPAL TUNNEL SYNDROME

Emrullah Cem KESİLMEZ<sup>1\*</sup>, Zafer YÜKSEL<sup>1</sup>


<sup>1</sup>Kahramanmaraş Sütçü İmam University, Faculty of Medicine, Department of Neurosurgery, 46100, Kahramanmaraş, Türkiye

**Abstract:** Carpal tunnel syndrome (CTS) is a condition in which the median nerve is compressed between the transverse ligament and the carpal bones. There are various techniques used in the surgical treatment of CTS. The present study aimed to investigate the reasons for reoperation by examining the reoperated cases diagnosed with CTS. Patients who underwent surgery for CTS at Kahramanmaraş Sütçü İmam University Department of Neurosurgery between January 1, 2015 and September 1, 2022 were evaluated retrospectively. All patients were operated by the same surgical team. Patients who underwent two or more operations with the same diagnosis were included in the study, while those operated for the first time due to CTS and with missing data were excluded. The included patients were analyzed in terms of gender, age, occupation, side of the surgery, presence of systemic diseases causing CTS such as diabetes mellitus (DM), number of the operations they underwent, time until the next operation, surgical technique, and medical branch that performed the surgery (orthopedics, neurosurgery, or plastic surgery). Forty-eight patients who met the study criteria were evaluated. Out of the 48 reoperated patients, 14 were male and 34 were female. Eighteen patients had been operated using the mini-incision open method, while 22 had undergone laparoscopic surgery, including 14 patients with biportal endoscopic surgery, and eight with uniportal endoscopic surgery. Out of the 48 patients, 31 (64.6%), 11 (22.9%), and six patients were first operated by orthopedic and traumatology physicians, plastic and reconstructive surgeons, and neurosurgeons, respectively. The use of open surgical technique is the gold standard in CTS and complete incision of the transverse ligament provides complete decompression of the median nerve. We believe that decompression with closed or small incisions due to aesthetic concerns may not be sufficient and may increase the risk of complications.

**Keywords:** Carpal tunnel syndrome, Reoperation, Open surgical technique, Endoscopic carpal tunnel surgery

\*Corresponding author: Kahramanmaraş Sütçü İmam University, Faculty of Medicine, Department of Neurosurgery, 46100, Kahramanmaraş, Türkiye

E mail: cemkesilmez@gmail.com (E. C. KESİLMEZ)

Emrullah Cem KESİLMEZ  <https://orcid.org/0000-0003-3905-2206>

Zafer YÜKSEL



<https://orcid.org/0000-0002-9234-5908>

Received: January 15, 2023

Accepted: May 29, 2023

Published: July 01, 2023

Cite as: Kesilmez EC, Yüksel Z. 2023. Retrospective analysis of 48 patients reoperated for carpal tunnel syndrome. BSH Health Sci, 6(3): 411-415.

### 1. Introduction

Carpal tunnel syndrome (CTS) is a condition in which the median nerve is compressed between the transverse ligament and the carpal bones. One of the most common but tricky neuropathies is CTS (Vögelin et al., 2014).

In 1854, Sir James Paget described CTS for the first time in a patient with distal radius fracture (Pfeffer et al., 1988; Lee et al., 1999). Marie and Foix demonstrated pathologic changes after long-term median nerve compression in an 80-year-old patient with thenar atrophy (Rengahary, 1985). Learmonth described the first decompression of the median nerve in 1933 (Tindall, 1990). Brain, Wright, and Wilkinson used the term “carpal tunnel syndrome” for the first time in 1947 in a series of patients who underwent surgical treatment and recovered (Dorwart, 1984).

After the studies, the prevalence of CTS was found to be 3.72%, but this rate increases up to 35% in professions that require constant use of the wrist (Jimenez et al., 1998). It is five times higher in women compared to men in the age range of 30–60 years and involves both wrists (Papanicolaou et al., 2001).

The most important factor in the development of CTS is the increase in pressure inside the carpal tunnel. This pressure increase disrupts the feeding of the median nerve and damage occurs in the nerve (Osiak et al., 2022). When the literature is reviewed in terms of the etiology of CTS, the cause is usually idiopathic in 50% of patients (Skuladottir, 2022). Causes other than the idiopathic include anatomical problems, abnormalities in the carpal bones, amyloidosis, DM, secondary causes related to tumors, rheumatic diseases, repetitive microtraumas due to occupation, and systemic diseases (Kıbıçıcı and Köksal, 2010; Zimmerman et al., 2022).

In CTS, surgical treatment is still the most accurate method in cases that cannot be improved with conservative treatment (Jimenez et al., 1998; Karjalainen, et al., 2022). Until now, different surgical methods have been applied in the treatment of CTS, including the classical open surgical method, endoscopic methods and the mini-incision open surgical technique. Although there is not much difference between these surgical techniques in terms of clinical and electrophysiologic values, cases with recurrent CTS occur due to incomplete incision of



the transverse ligament, damage to the median nerve, and scar tissue formation (Abdullah et al., 1995). Although it varies depending on how a specific surgical technique is applied, the recurrence rate in CTS operations performed with popular endoscopic techniques is 0%-10% in 5-year follow-up, and these recurrent cases are reoperated with the classical open surgical technique within 3-6 months (Oertel et al., 2006; Açıkgöz, 2010).

In the current study, we aimed to minimize neural tissue damage with appropriate surgical technique by examining cases with recurrent CTS that developed as a result of inadequate decompression of the carpal tunnel due to incomplete incision of the transverse carpal ligament.

## 2. Materials and Methods

Patients who underwent surgery for CTS at Kahramanmaraş Sütçü İmam University Department of Neurosurgery between January 1, 2015 and September 1, 2022 were evaluated retrospectively. Total number of the patients was 578. The number of patients who had CTS surgery for the first time was 521. The number of patients with missing data was 9. The inclusion criteria were as follows: Patients having complaints for at least three months, having no additional neurological pathology, and having conduction disturbances in motor and sensory fibers on electromyography (EMG). Patients who underwent two or more operations with the same diagnosis were included in the study, while those operated for the first time due to CTS and with missing data were excluded. 48 patients who met the study criteria were evaluated (Figure 1). 2 Neurosurgeons performed all surgeries. The same surgical team operated all patients with the same surgical technique.

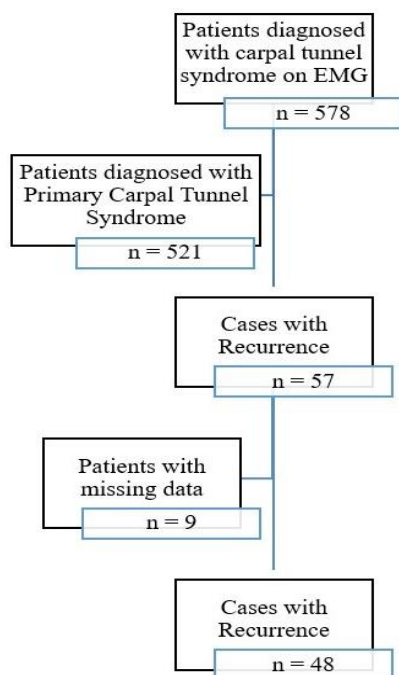


Figure 1. Flow chart of the study.

In all patients, EMG examination was performed once before the surgical procedure and twice after the surgical procedure (postoperative first and sixth month). The surgery was performed by the same surgical team and the patients were discharged postoperatively on the same day. Sutures were removed on the postoperative Day 15 and the patients were instructed to exercise with a stress ball. The mean follow-up period was 7.5 months. The included patients were analyzed in terms of gender, age, occupation, side of the surgery, presence of systemic diseases causing CTS such as DM, number of the operations they underwent, time until the next operation, surgical technique, and medical branch that performed the surgery (orthopedics, neurosurgery, or plastic surgery).

### 2.2. Surgical Technique

Open surgery using a mini incision, open surgery using a classic standard incision, or biportal or uniportal endoscopic surgical techniques are used in CTS operations. In these cases, we used the standard open technique with complete exposure of the transverse ligament. All surgeries was performed with this technique and by same surgical team.

In the standard open surgical technique, after local anesthesia, the procedure is started with a curved incision parallel to the thenar crease and close to the ulnar side. The incision is extended obliquely past the wrist crease along the ulnar side of the palmaris longus tendon to 2-3 cm distal to the forearm. The sensory palmar branch of the median nerve is preserved. With the help of blunt dissection, the subcutaneous tissues are passed and the antebrachial, palmar fascia, and the transverse carpal ligament are exposed. After dissection, the entry site of the median nerve under the transverse carpal ligament is visualized and this ligament is cut from proximal to distal on the ulnar side. Considering the variations of the median nerve, care is taken to preserve the recurrent branch of the median nerve.

### 2.3. Statistical Analysis

Statistical Package for Social Sciences software (SPSS), version 20.0, was used to analyze the data. Numerical data were given as mean ± standard deviation (minimum-maximum values). Categorical data were given as number (n) and percentage (%). Kolmogorov-Smirnov test was used to determine the conformity or non-conformity of the numerical data to normal distribution. One-sample chi-square test and binomial test were used to compare the numerical data between the groups. P<0.05 was considered statistically significant (Önder, 2018).

## 3. Results

Out of 578 patients who were diagnosed with carpal tunnel on EMG, 57 patients were considered as cases with recurrence after the examinations performed because their complaints continued after the operation. Nine of these patients were excluded from the study because their data was incomplete. The remaining 48

patients were included in the study.

Out of the 48 patients with reoperation, 14 were male and 34 were female. Female patients accounted for a significant group of the patients (70.8%). There was no right or left hand dominance in any of the groups and the numbers were similar. 31.25% of the patients had comorbidities, including DM in 14 patients and hypothyroidism in one patient. Thirty-three patients had no comorbidities.

Eighteen of the 48 reoperated patients had been operated using the mini-incision open method, while 22

had undergone laparoscopic surgery, including 14 patients with biportal endoscopic surgery and eight with uniportal endoscopic surgery. Only eight of them were operated using the classical open surgery technique.

Out of the 48 patients, 31 patients (64.6%) were first operated by orthopedic and traumatology physicians, 11 patients (22.9%) were first operated by plastic and reconstructive surgeons, and six patients were first operated by neurosurgeons. Out of the 48 patients, 45.8% were housewives, 20.8% were factory workers, and 18.8% were agricultural workers (Table 1).

**Table 1.** Demographic distribution of the patients operated for recurrent carpal tunnel syndrome

Data		Number and Percentage of Patients n (%)	P
Gender	Male	14 (29.2%)	0.006*
	Female	34 (70.8%)	
	Total	48 (100%)	
Side	Right	25 (52.1%)	0.885
	Left	23 (47.9%)	
	Total	48 (100%)	
Comorbidity	No	33 (68.75%)	0.014*
	Yes	15 (31.25%)	
	DM	14 (29.12%)	
First Surgical Technique	Hypothyroidism	1 (2.13%)	0.112
	Total	48 (100%)	
	Open surgery	8 (16.7%)	
	Biportal endoscopic	14 (29.2%)	
	Transverse mini incision	18 (37.5%)	
Medical Branch	Uniportal endoscopic	8 (16.7%)	<0.001*
	Total	48 (100%)	
	Neurosurgery	6 (12.5%)	
	Orthopedics and Traumatology	31 (64.6%)	
	Plastic and Reconstructive Surgery	11 (22.9%)	
Profession	Total	48 (100%)	<0.001*
	Farmer	4 (8.3%)	
	Housewife	22 (45.8%)	
	Factory Worker	10 (20.8%)	
	Officer	2 (4.2%)	
	Agriculture Worker	9 (18.8%)	<0.001*
	Tailor	1 (1.1%)	
	Total	48 (100%)	

\*= P<0.05

#### 4. Discussion

In patients with CTS, conservative treatments should be tried first and then surgical treatment methods should be applied if the patient does not benefit (Ziyal et al., 1999; Karjalainen et al., 2022; Cage et al., 2023; Mao et al., 2023). Surgically, it is aimed to decompress the median nerve by cutting the carpal ligament over the median nerve, which results in clinically significant improvement (Szabo and Steinberg, 1994; Ziyal et al., 1999).

Different methods for surgical treatment of CTS have been developed by clinicians until today. Although these methods are not clinically or electrophysiologically

superior to each other, insufficient or incomplete incision of the transverse ligament contributes to the recurrence rate (Lam et al., 2023; Lee et al., 2023; Walker, 2023).

First performed in 1924 and still being performed today, the results obtained by decompression of the transverse ligament in the carpal tunnel with the open surgical technique are satisfactory (Cellocco et al, 2009; Haglin et al., 2023).

The disadvantages of the open surgical technique are pain due to the incision and the possibility of scar tissue formation (Ziyal et al., 1999). In addition to the open

surgical technique, endoscopic surgical methods have been developed over time with the development of endoscopic instruments and surgeons gaining experience in endoscopic procedures over time, and it has been aimed for patients to return to work aesthetically better and painlessly in the early postoperative period (Palmer and Toivonen, 1999; Mende et al., 2023).

In surgeries performed with endoscopic methods, knowledge of endoscopic anatomy and an adequate level of experience are required; otherwise, serious complications or inadequate surgical outcomes may occur (Urbaniak and Desai, 1996; Yamamoto, et al., 2022; Zhang et al., 2023).

In the endoscopic surgical technique, incision of the transverse ligament without visualization may cause both inadequate surgical outcomes and median nerve injury (Andrew Lee and Strickland, 1998; Graham et al., 2023).

Another method used is the mini-incision open surgical technique. In this method, it is aimed to release the transverse ligament with a smaller incision compared to the classical open surgical method to achieve a more aesthetic appearance and less scar tissue (Topuz et al., 2012; Murthy et al., 2015).

However, the most important disadvantage of this technique is inadequate decompression or median nerve injury due to the inability to see the transverse ligament completely as in the endoscopic techniques.

The gold standard in CTS surgery is the classical open surgical technique (Jimenez et al., 1998). This technique allows full command over both the carpal tunnel and the transverse ligament. In addition, it is difficult to manage various variations of the motor branches of the median nerve with endoscopic or mini-incision techniques (Lanz, 1977; Açıkgöz, 2010; Khalid et al., 2023).

All of the 48 patients included in our study were operated in other centers and diagnosed with recurrence. The common characteristic of these patients was incomplete incision of the transverse ligament. The majority of the patients were operated with the endoscopic technique; however, in the endoscopic technique, the qualification of the instruments used is important just as much as the experience level of the surgeon, and in endoscopic surgeries, inadequate decompression is commonly observed (Chow, 1993).

In our classical technique, it is possible to cut the transverse ligament with complete visualization and the possibility of median nerve injury is minimized.

The next day after CTS surgery, the patient's paresthesia and pain are significantly reduced. In the absence of this reduction, inadequate decompression should be suspected.

## 5. Conclusion

We believe that, in CTS, the use of open surgical technique and complete incision of the transverse ligament provides complete decompression of the median nerve, thereby significantly reducing the rate of

recurrence. We believe that decompression with closed or small incisions due to aesthetic concerns may not be sufficient and may increase the risk of complications.

## Author Contributions

The percentage of the author(s) contributions is present below. All authors reviewed and approved final version of the manuscript.

	E.C.K.	Z.Y.
C	50	50
D	100	
S	50	50
DCP	100	
DAI	100	
L	80	20
W	100	
CR	20	80
SR	100	

C=Concept, D= design, S= supervision, DCP= data collection and/or processing, DAI= data analysis and/or interpretation, L= literature search, W= writing, CR= critical review, SR= submission and revision.

## Conflict of Interest

The authors declared that there is no conflict of interest.

## Funding

This research has not received any financial support from funding agencies in the public, commercial, or not-for-profit sectors.

## Ethical Approval/Informed Consent

The study was approved by the Clinical Studies Bioethics Committee of the Medical Faculty of Kahramanmaraş Sutcu Imam University (approval date: December 12, 2022, protocol code: 2022/377;08). Informed consent and written consent for the publication of the data were obtained from all individuals in the study.

## References

- Abdullah AF, Wolber PH, Ditto EW. 1995. Sequelae of carpal tunnel surgery. *Neurosurgery*, 37(5): 931-936.
- Açıkgöz B. 2010. Karpal tünel sendromu. In: Demircan N, Zileli M, editors. *Periferik sinir cerrahisi. Türk Nöroşirürji Derneği, Ankara, Türkiye*, pp: 281-304.
- Andrew Lee WP, Strickland JW. 1998. Safe carpal tunnel release via a limited palmar incision. *Plast Reconstr Surg*, 101(2): 418-424.
- Cage ES, Beyer JJ, Ebraheim NA. 2023. Injections for treatment of carpal tunnel syndrome: A narrative review of the literature. *J Orthop*, 37: 81-85.
- Cellocco P, Rossi C, El Boustany S, Di Tanna GL, Costanzo G. 2009. Minimally invasive Carpal Tunnel release. *Orthop Clin North Am*, 40(4): 441-448.
- Chow JCY. 1993. The chow technique of endoscopic release of the carpal ligament for carpal tunnel syndrome: Four years of clinical results. *Arthrosc J Arthrosc Relat Surg*, 9(3): 301-314.
- Dorwart BB. 1984. Carpal tunnel syndrome: A review. *Semin Arthritis Rheum*, 14(2): 134-140.
- Graham JG, Plusch KJ, Hozack BA, Ilyas AM, Matzon JL. 2023.

- Early revision rate following primary carpal tunnel release. *J Hand Surg Glob Online*, 5(3): 277-283. DOI: 10.1016/j.jhsg.2023.01.010.
- Haglin JM, Hinckley NB, Moore ML, Deckey DG, Lai CH, Renfree KJ. 2023. Long-term trends in open vs endoscopic carpal tunnel release among the medicare population in the United States. *HAND*, 0(0). DOI: 10.1177/15589447231168977.
- Jimenez DF, Gibbs SR, Clapper AT. 1998. Endoscopic treatment of carpal tunnel syndrome: A critical review. *J Neurosurg*, 88(5): 817-826.
- Karjalainen T, Raatikainen S, Jaatinen K, Lusa V. 2022. Update on efficacy of conservative treatments for carpal tunnel syndrome. *J Clin Med*, 11(4): 950.
- Khalid SI, Deysher D, Thomson K, Khilwani H, Mirpuri P, Maynard M. 2023. Outcomes following endoscopic versus open carpal tunnel release-a matched study. *World Neurosurg*, 171: 162-171.
- Kıbcı K, Köksal V. 2010. Mini açık teknikle yapılan karpal tünel cerrahisi ve fonksiyonel sonuçları. *Türk Nöroşirürji Derg*, 20(1): 7-14.
- Lam KHS, Wu Y-T, Reeves KD, Galluccio F, Allam AE-S, Peng PWH. 2023. Ultrasound-guided interventions for carpal tunnel syndrome: A systematic review and meta-analyses. *Diagnostics*, 13(6): 1138.
- Lanz U. 1977. 2 Anatomical variations of the median nerve in the carpal tunnel. *J Hand Surg Am*, (1): 44-53.
- Lee D, van Holsbeeck MT, Janevski PK, Ganos DL, Ditmars DM, Darian VB. 1999. Diagnosis of carpal tunnel syndrome. *Radiol Clin North Am*, 37(4): 859-872.
- Lee YS, Youn H, Shin SH, Chung YG. 2023. Minimally invasive Carpal Tunnel release using a hook knife through a small transverse carpal incision: Technique and outcome. *Clin Orthop Surg*, 15(2): 318.
- Mao B, Li Y, Yin Y, Zhang Z, Li J, Fu W. 2023. Local corticosteroid injection versus physical therapy for the treatment of carpal tunnel syndrome: A systematic review and meta-analysis of randomized controlled trials. *Asian J Surg*, DOI: 10.1016/j.asjsur.2023.04.104.
- Mende K, Kamphuis SJM, Schmid V, Schaefer DJ, Kaempfen A, Gohritz A. 2023. Early postoperative recovery after modified ultra-minimally invasive sonography-guided thread Carpal Tunnel release. *J Pers Med*, 13(4): 610.
- Murthy PG, Goljan P, Mendez G, Jacoby SM, Shin EK, Osterman AL. 2015. Mini-open versus extended open release for severe carpal tunnel syndrome. *HAND*, 10(1): 34-39.
- Oertel J, Schroeder HWS, Gaab MR. 2006. Dual-portal endoscopic release of the transverse ligament in Carpal Tunnel Syndrome: Results of 411 procedures with special reference to technique, efficacy and complications. *Neurosurgery*, 59(2): 333-340.
- Önder H. 2018. Nonparametric statistical methods used in biological experiments. *BSJ Eng Sci*, 1(1): 1-6.
- Osiak K, Elnazir P, Walocha JA, Pasternak A. 2022. Carpal tunnel syndrome: state-of-the-art review. *Folia Morphol (Warsz)*, 81(4): 851-862.
- Palmer AK, Toivonen DA. 1999. Complications of endoscopic and open carpal tunnel release. *J Hand Surg Am*, 24(3): 561-565.
- Papanicolaou GD, McCabe SJ, Firrell J. 2001. The prevalence and characteristics of nerve compression symptoms in the general population. *J Hand Surg Am*, 26(3): 460-466.
- Pfeffer GB, Gelberman RH, Boyes JH, Rydevik B. 1988. The history of carpal tunnel syndrome. *J Hand Surg Am*, 13(1): 28-34.
- Rengahary S. 1985. Entrapment neuropathies. In: Wilkins R, editor. *Neurosurgery*. Graw Hill Back Company, New York, US, pp: 1771-1777.
- Skuladottir AT, Bjornsdottir G, Ferkingstad E, Einarsson G, Stefansdottir L, Nawaz MS. 2022. A genome-wide meta-analysis identifies 50 genetic loci associated with carpal tunnel syndrome. *Nat Commun*, 13(1): 1598.
- Szabo R, Steinberg D. 1994. Nerve entrapment syndromes in the wrist. *J Am Acad Orthop Surg*, 2(2): 115-123.
- Tindall S. 1990. Chronic injuries of peripheral nerves by entrapment. In: Youmans J, editor. *Neurological surgery*. Saunders W.B., New York, US, pp: 2511-2524.
- Topuz AK, Eroğlu A, Atabey C, Dinç C, Göçmen NS, Çolak A. 2012. Nüks 18 Karpal Tünel Sendromu olgusu ve nedenlerinin değerlendirilmesi. *Türk Nöroşirürji Derg*, 22(11): 10-15.
- Urbaniak JR, Desai SS. 1996. Complications of nonoperative and operative treatment of carpal tunnel syndrome. *Hand Clin*, 12(2): 325-335.
- Vögelin E, Mészáros T, Schöni F, Constantinescu MA. 2014. Sonographic wrist measurements and detection of anatomical features in carpal tunnel syndrome. *Sci World J*, 2014: 1-6.
- Walker FO. 2023. A 15-year review of clinical practice patterns in Carpal Tunnel syndrome based on continuous certification by the American board of plastic surgery. *Plast Reconstr Surg*, 151(3): 524e-525e.
- Yamamoto M, Curley J, Hirata H. 2022. Trends in open vs. endoscopic carpal tunnel release: A comprehensive survey in Japan. *J Clin Med*, 11(17): 4966.
- Zhang D, Dyer GSM, Blazar P, Earp BE. 2023. The environmental impact of open versus endoscopic Carpal Tunnel release. *J Hand Surg Am*, 48(1): 46-52.
- Zimmerman M, Gottsäter A, Dahlin LB. 2022. Carpal tunnel syndrome and diabetes-A comprehensive review. *J Clin Med*, 11(6): 1674.
- Ziyal İM, Döşpöğlü M, Duman H, Öztürk A, Gezen F. 1999. Carpal tunnel syndrome: Comparison of the surgical outcomes of 36 cases (50 hands) with the literature data. *Düzce Tıp Fak Derg*, 1(1): 55-62.