

## Case Report / Olgu Sunumu

# A Rare Larynx Foreign Body: Dental Prosthesis

## Nadir Bir Larinks Yabancı Cismi: Diş Protezi

Serkan Ceyhan<sup>1\*</sup>

### ABSTRACT

Foreign body aspiration in the airway is a condition that may cause severe morbidity and mortality and requires immediate management. General symptoms and signs may include dysphonia, the sensation of a sting in the throat, dysphagia, respiratory stress, tachypnea, wheezing, stridor, and cyanosis. In our case report, the diagnosis and treatment process of the patient who was found to have a foreign body in the larynx is explained. An eighty-seven year-old male patient was consulted due to an increase oral secretion, tachypnea, dysphagia, and a worsening of oral nutrition. A metallic foreign body was observed in the flexible nasopharyngolaryngoscopic examination, and dental prosthesis was determined by radiological imaging. The foreign body was removed with the help of laryngeal forceps under sedation. The healthcare staff should be suspicious of all detachable prostheses, avoid using loosened prostheses, and in certain cases, they should manage the event immediately in patients with risk factors.

Key Words: Larynx, Foreign body, Dental prosthesis

### Öz

Hava yolunda yabancı cisim aspirasyonu ciddi morbidite ve mortaliteye neden olabilen ve acil müdahale gerektiren bir durumdur. Başlıca genel semptom ve bulgular disfoni, boğazda batma hissi, disfaji, solunum sıkıntısı, takipne, hırıltılı stridor ve siyanoz olarak sayılabilir. Olgu sunumumuzda larinkste yabancı cisim saptanan hastanın tanı tedavi süreci anlatılmıştır. 87 yaşında erkek hasta artmış oral sekresyon, takipne, disfaji ve oral beslenmenin bozulması ile tarafımıza konsülte edildi. Yapılan fleksible nazofaringolarinoskopik muayenesinde metalik yabancı cisim görüldü ve radyolojik görüntüleme ile dental protez olduğu tespit edildi. Sedasyon altında bir laringeal forseps yardımı ile yabancı cisim çıkarıldı. Sağlık personeli, çıkarılabilir tüm protezlerden şüphelenmeli, gevşemiş protez kullanmaktan kaçınılmalı ve bazı durumlarda, risk faktörü olan hastalarda olayı acil olarak yönetmelidir.

Anahtar Kelimeler: Larinks, Yabancı cisim, Diş protezi

1.Department of Ear Nose and Throat Diseases Eskişehir City Hospital, Eskişehir, Turkey

Gönderilme Tarihi: 16/01/2023

Kabul Tarihi: 01/03/2023

Yayınlanma Tarihi: 22/06/2023

\*Sorumlu Yazar

Serkan Ceyhan

Department of Ear Nose and Throat Diseases Eskişehir City Hospital, Eskişehir, Turkey

Tel: +90 533 7244004, E-mail: ceyhanserkan@hotmail.com

ORCID ID: 0000-0001-6497-0629

**Cite this article:** Ceyhan S. A Rare Larynx Foreign Body: Dental Prosthesis. Ağrı Med J. 2023;1(2): 61-63

## Introduction

Foreign body aspiration in the airway is a condition that may cause severe morbidity and mortality and requires immediate management. Foreign body aspiration is rare in adults, as it is more commonly seen in pediatric patients (1-3). Neurological disabilities are a common risk factor for foreign body aspirations. Foreign bodies in the airway may present as asymptomatic, but may also lead to symptoms and signs such as life-threatening sudden respiratory distress. Therefore, symptoms and signs should raise clinical suspicion and treatment should be started immediately. The severity of the symptoms depends on the size of the foreign body, localization, structure, and duration of stay in the aerodigestive tract (2). In our case, the diagnosis and treatment process of the patient who was found to have a foreign body in the larynx was presented.

## Case Report

An 87 year-old male patient was admitted to the Infectious Disease Department due to high fever, wheezing, poor general condition, altered mental status, lower respiratory tract infection caused by respiratory distress and bacteremia. The patient was consulted to us due to an increase in the oral secretion, increase in tachypnea, dysphagia, and a worsening of oral nutrition in the last three days. Medical history revealed that the patient had the cerebrovascular disease (CVD) 2 years ago. This event led to a left hemiparesis, and thus he needed physical assistance for mobilization. Examination revealed somnolence and increase in oral secretion. There were no stridor or cyanosis, while the patient had tachypnea and wheezing. Flexible nasopharyngolaryngoscopy was performed by injecting 1% lidocaine spray into the left nasal passage and after going into the left nasal passage and then by advancing to nasopharynx and oropharynx, a visible metal foreign body was detected under tongue base along with a dense purulent secretion. Laryngeal airway and vocal cords could not be observed. X-ray images were compatible with the total dental prosthesis. Patient's relatives stated that the upper portion of his dental prosthesis had been lost for a few days. Afterward, the patient was operated on. Under sedation, the foreign body was removed with a laryngoscope and a laryngeal forceps. After an evaluation of the larynx air passage and surrounding tissues, it was observed that there was no prominent tissue damage. Edema in arytenoid mucosa was detected, rima glottis was sufficiently wide, and arytenoid and vocal cords were mobile. Post operative x-ray results were normal and symptoms were relieved dramatically. Tachypnea was improved and oral intake was initiated. On the other hand, due to concomitant diseases, the patient's general condition got worsened. The patient died due to hypoxemic respiratory failure and respiratory arrest. He aspirated his dental prosthesis due to history of CVD and somnolence. When the patient's previous x-ray images were assessed, it was concluded that admission to the hospital was not due to foreign body aspiration. As the patient's relative stated, aspiration occurred in the last 2 days. In the plain chest x-ray, the foreign body is not visible at the patient's hospitalization (Figure 1). X-ray after ENT consultant examination due to oral secretion increase, and dysphagia shows foreign body (Figure 2,3,4).

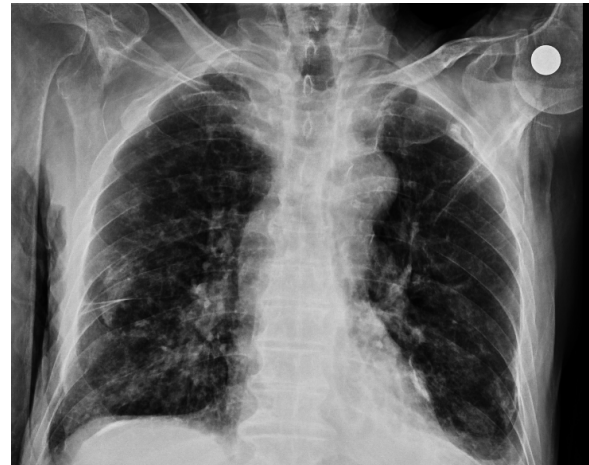

Figure 1: Posteroanterior (PA) thorax radiogram ; There was no foreign body during the first hospitalization.

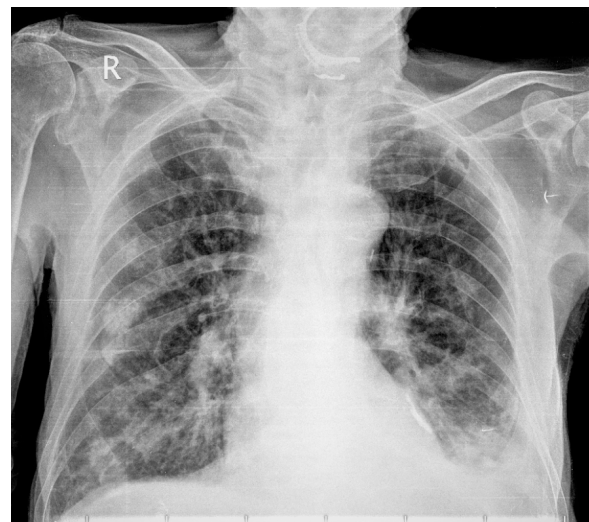


Figure 2: PA thorax radiogram.

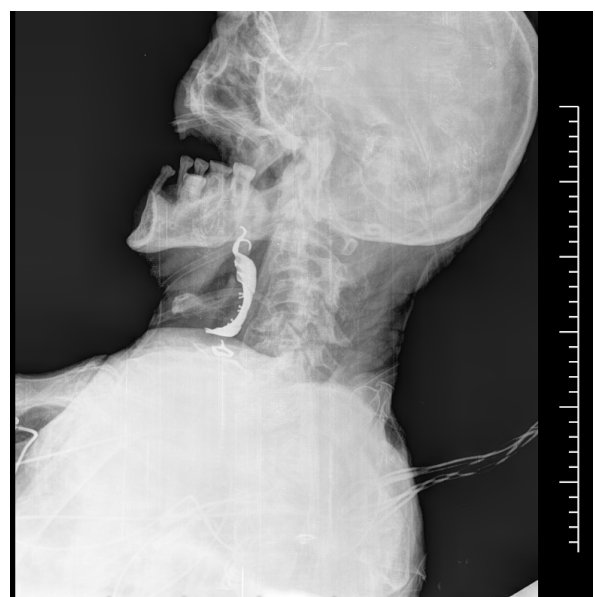

Figure 3: Lateral neck radiogram.

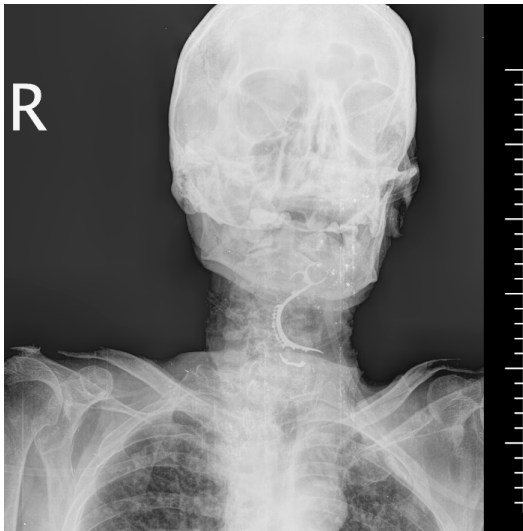

Figure 4: PA neck radiogram ; Foreign body detection after the onset of symptoms and ENT consultation.

## Discussion

Foreign body aspiration in the airway is a condition that may cause severe morbidity and mortality and requires immediate management. Laryngeal foreign bodies are extremely rare and they make 4% up of tracheobronchial foreign bodies. Foreign body aspiration is more commonly seen in pediatric patients (1-3). It is rare in the adult population. Mental retardation, facial trauma, dental procedures, metabolic encephalopathy, neurological disorders due to a history of stroke, episodes, upper airway infections, and alcoholism are among the risk factors for foreign body aspiration in the adult population (2,3). Symptoms can be asymptomatic and detected by a routine examination, however, they may vary from a simple dysphonia to an airway obstruction which is a life-threatening condition (1,4). The severity of the symptoms depends on the size of the foreign body, its localization, structure, and duration of stay in the aerodigestive tract (2). General symptoms and signs may include dysphonia, the sensation of a sting in the throat, dysphagia, respiratory stress, tachypnea, wheezing, stridor, and cyanosis. The most commonly aspirated foreign bodies include organic materials such as hazelnut and seed of the fruit in the pediatric population whereas in adult population food and food bones are the most commonly aspirated ones. Metallic foreign body aspirations are extremely rare (1). In his study, Yadav et al. reported metallic foreign body aspiration in 6 (4,5%) of 132 patients (5). In our case, a dental prosthesis aspiration occurred after hospitalization.

Due to a consciousness disorder and a history of CVD, the patient aspirated his dental prosthesis which had probably been loosened earlier. Healthcare staff should be suspicious of all detachable prostheses, avoid using loosened prostheses, and in certain cases, they should manage the event immediately in patients with a risk factor of mental retardation, facial trauma, dental procedures, metabolic encephalopathy, neurological disorders due to a history of stroke, episodes, upper airway infections, and alcoholism. Otherwise, airway obstruction, which is a life-threatening condition, may occur.

## REFERENCES

1. Hada M, Samdhani S, Chadha V, Harshvardhan RS, Prakash M ; Laryngeal foreign bodies among adults. *J Bronchology Interv Pulmonol* 2015; 22(2):145-146. DOI: 10.1097/LBR.0000000000000056
2. Türk B, Ünsal Ö, Kaya KS, Coşkun BU. Dislocated dental prosthesis sitting at the larynx in an aphasic patient: potential fatal Situation. *J Craniofac Surg.* 2017;28(7):3655-3657. DOI: 10.1097/SCS.00000000000003795
3. Kansara AH, Shah HV, Patel MA, Manjunatharao SV. Unusual case of Laryngeal Foreign Body. *Indian J Otolaryngol Head Neck Surg* 2007;59(1):63-65. DOI:10.1007/s12070-007-0019-0
4. Cohen SR, Herbert WT, Lewis GB, Geller KA. Five-Year Retrospective Study with Special Reference to Management. *Ann Otol Rhinol Laryngol* 1980;89: 437-442 DOI:10.1177/000348948008900513
5. Yadav SP, Singh J, Aggarwal N, Goel A. Airway foreign bodies in children: experience of 132 cases. *Singapore Med. J.* 2007;48(9):850-853. <https://pubmed.ncbi.nlm.nih.gov/17728968/>