



Letter to the Editor

Clin Exp Ocul Trauma Infect. 2022;4(1),11-13

Tips for Eyelid Lacerations

Assoc Prof Dr Sertaç Argun Kıvanç, MD, FEBOPht, FICOPht, MRCSEd(Opht)

Bursa Uludag University, Department of Ophthalmology, Bursa, Türkiye

Dear Editor;

I would like to point out some points that should be considered in the repair of eyelid injuries. When the patient is admitted to the hospital, the general condition of the patient is evaluated first, and then the eye should be evaluated. It is necessary to conduct a full ophthalmological examination for the condition of the eyeball and adnexa

Forensic reports are mandatory for all trauma patients in Turkey. The status of the tetanus vaccine should be questioned and, if necessary, tetanus vaccine should be given. If there is a dirty wound, it would be appropriate to start prophylactic antibiotics. In our own clinical practice, we perform Computed Tomography (CT) imaging for all ocular trauma patients and recommend it to all ophthalmologists. These are things to be done before the surgery and there are situations that should be considered during the surgery. Wound lips should be cleaned very well, foreign bodies should be removed as much as possible, necrotic tissues should be removed, but tissue loss should be kept to a minimum. Care must be taken to align the tissues in the anatomically correct position according to anterior and posterior lamella (Figure 1), to perform atraumatic suturing and to avoid excessive cauterization. Canaliculi, extraocular muscles and orbital injuries should also be carefully evaluated together with the globe. It should always be kept in mind that the eye is the priority in eyelid

injuries associated with open globe injuries. In large wounds, flaps and grafts should be used where necessary (1-4). During surgery, I recommend repairing at high magnification using a microscope or loop, if possible.

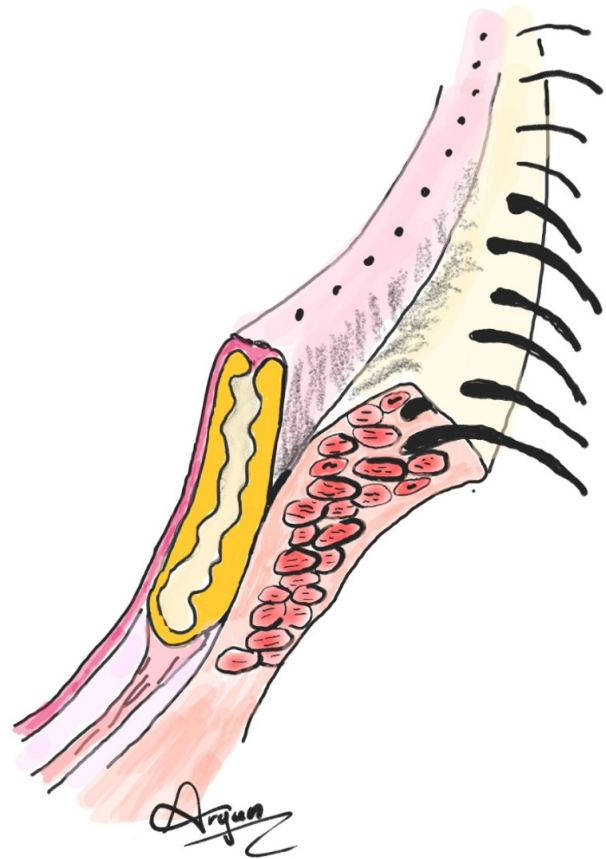


Figure 1. Anterior and posterior lamellas of the eyelid

One of the most important issues is the repair of the margin of the eyelid. Different techniques can be applied, the important thing is to ensure a good mutual apposition of the

wound lips in accordance with the anatomy (1,4). One of these techniques is primary closure with 3 sutures. Primary suturing can be done with 3 sutures placed on the meibomian gland orifices, gray line and lash line (Figure 2).

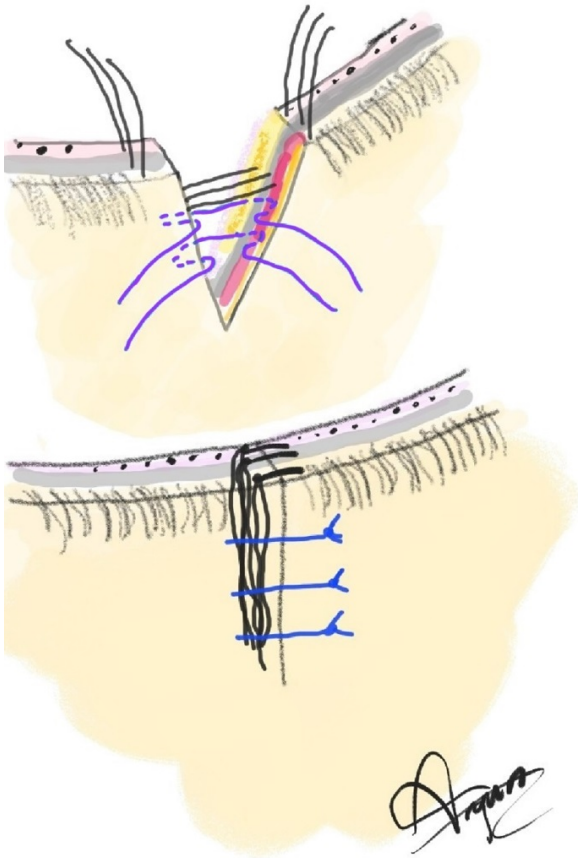


Figure 2. Primer suturation of the eyelid

Another method is mattress suturing. This can be done with 2 or 3 sutures

techniques. The knots of the sutures can be left in the wound or the ends of the sutures can be left long and left under the prolene suture placed on the skin (Figures 3 and 4). In this suture, the slightly everted wound lips will provide better healing of the wound line. 5/0-6/0 prolene, polyglactin or silk sutures can also be used for suturing in the repair of eyelid skin (4). We prefer to use 5/0-6/0 polyglactin sutures for subcutaneous tissue in our own department. Care should be taken not to suture the septum while suturing under the skin. The posterior lamella must be repaired first. The tarsal plate can be repaired with 6/0-7/0 polyglactin sutures. We prefer polyglactin or silk sutures for vertical matrix suturing.

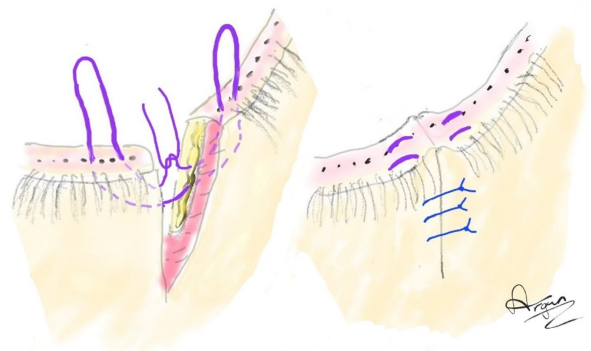


Figure 3. Mattress suturing where the knot remains in the tissues

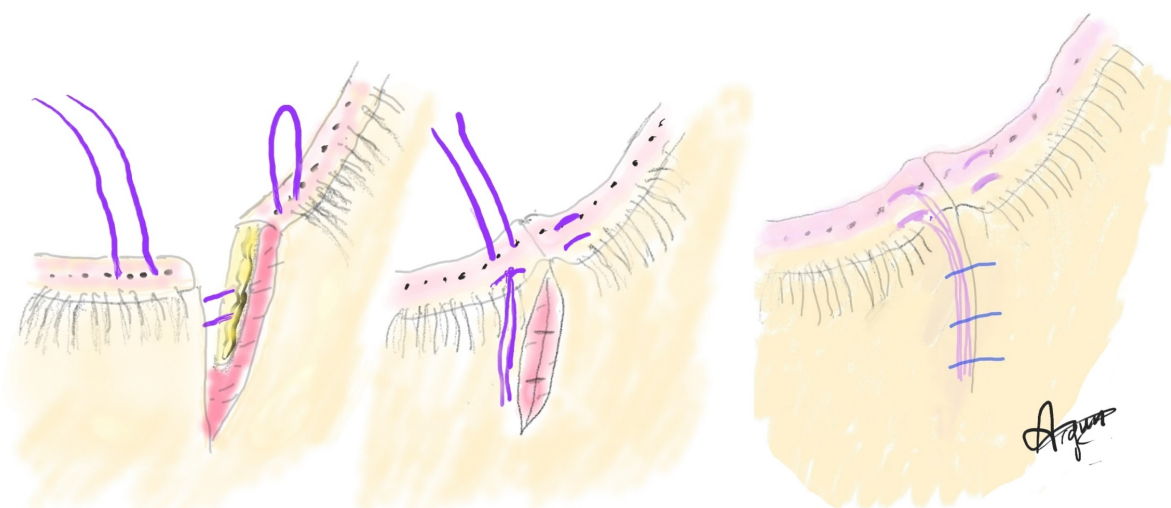


Figure 4. Mattress suturing with slightly everted wound lips and placement of long suture ends under prolene sutures.

References

1. Örnek F. Kapak Yaralanmalarında Primer Onarım ve Geç Rekonstrüktif Cerrahi. In: Oküler Travmatoloji ve Medikolegal Oftalmoloji: Güncel Tanı ve Tedavi Yaklaşımları. Türk Oftalmoloji Derneği Eğitim Yayınları. No 16. 2020, 79-88
2. Leibovitch I, Huilgol SC, Hsuan JD, Selva D. Incidence of host site complications in periocular full thickness skin grafts. Br J Ophthalmol. 2005; 89(2):219-22.
3. Bush K, Cartmill BT, Parkin BT. Skin grafts in the periocular region without a bolstered dressing. Orbit. 2011; 31(1):59-62.
4. American Academy of Ophthalmology. https://eyewiki.org/Eyelid_Laceration#Surgery (Internet Access September 2022)