

# The effect of hypertension in pregnancy and central nervous system anomalies on fetal brain development

Mehmet Albayrak<sup>1</sup>, Mehmet Faruk Köse<sup>1</sup>, Banu Anlar<sup>2</sup>

<sup>1</sup>Department of Obstetrics and Gynecology, Etlik Zübeyde Hanım Maternity and Gynecology Training and Research Hospital, Ankara, Turkey; <sup>2</sup>Department of Child Neurology, Hacettepe University Faculty of Medicine, Ankara, Turkey

## ABSTRACT

**Objectives:** The aim of this study was to investigate whether maternal hypertension affects fetal brain maturation, and to examine whether treatment with magnesium sulfate has a protective effect on the fetal brain.

**Methods:** A total of 26 fetuses, including 11 dead fetuses of pregnant women who were found to have hypertension and whose pregnancy was terminated due to this reason, and 15 fetuses who did not have this risk factor but died for various reasons as the control group, were included in the study. Brain tissue samples were evaluated for the presence of morphological and histopathological changes, as well as apoptotic cells. The morphologies of the samples were examined in sections stained with hematoxylin-eosin (H&E), and apoptosis was examined with light microscopy by the terminal deoxynucleotidyl transferase dUTP nick end labeling (TUNEL) method.

**Results:** In the control group, it was observed that the brain tissue had a morphological structure compatible with the development weeks. In the hypertension group, there were no bleeding foci and brain tissues mostly preserved morphological features similar to control patients. While edema was detected in 45.4% of the infants in the hypertension group, no edema was observed in 54.6%. In the hypertension group, Grade 1 necrosis was observed in 63.6% of the samples, Grade 2 necrosis was observed in 9.1%, and no necrosis was observed in 27.3% of the samples.

**Conclusions:** Based on the findings of this study, it can be concluded that maternal hypertension increases neurological maturation by causing vasodilation in the fetal brain, increasing blood flow, and decreasing cell death.

**Keywords:** Maternal hypertension, fetal development, brain, edema, hemorrhage, necrosis, apoptosis

Feto-placental development and functioning are vulnerable to maternal risk factors such as diabetes, obesity, and hypertension, creating an unfavorable environment for healthy fetal development [1]. Hypertensive disorders during pregnancy, such as gestational hypertension, pre-eclampsia, and eclampsia,

are common medical complications affecting up to 9% of women [2]. These disorders expose the fetus to general stress and alter the intrauterine environment, leading to changes in the structural and phenotypic characteristics of the fetus [3]. As a result, changes occur in the structural or phenotypic characteristics of



e-ISSN: 2149-3189

Received: February 14, 2023; Accepted: March 26, 2023; Published Online: April 13, 2023

**How to cite this article:** Albayrak M, Köse MF, Anlar B. The effect of hypertension in pregnancy and central nervous system anomalies on fetal brain development. *Eur Res J* 2023;9(6):1429-1437. DOI: 10.18621/eurj.1249233

**Address for correspondence:** Mehmet Albayrak, MD., Etlik Zübeyde Hanım Maternity and Gynecology Training and Research Hospital, Department of Obstetrics and Gynecology, Yeni Etlik Cad., No:55, 06010 Etlik, Keçiören, Ankara, Turkey. E-mail: albyrkmhmt@gmail.com, Phone: +90 312 567 40 00



©Copyright © 2023 by Prusa Medical Publishing  
Available at <http://dergipark.org.tr/eurj>  
[info@prusamp.com](mailto:info@prusamp.com)

the fetus. For example, fetuses exposed to hypertension are more sensitive to auditory stimuli after birth [4].

Preeclampsia, a common cause of hypertension during pregnancy, is a vascular disease that affects 3-8% of pregnancies worldwide [5]. Its pathogenesis involves placental and trophoblastic changes, leading to a decrease in uteroplacental blood flow and fetoplacental hypoxemia. Severe preeclampsia can result in eclampsia or mortality for both the mother and fetus [6, 7]. In addition, prenatal inflammation is the most blamed factor for fetal brain injury, while vascular endothelial growth factor (VEGF) decreases in the fetal lung due to maternal hypertension [8, 9]. Maternal hypertension has been reported to increase fetal brain maturation by affecting the gyrus and sulci morphology and neurophysiological methods [10, 11]. Recent studies have shown that molecular and apoptotic mechanisms play a crucial role in fetal central nervous system development Preeclampsia. While congenital anomalies of the CNS occur in around 1/1000 cases, detailed fetal sonographic examination has made it easier to detect these malformations [12]. There is limited data available on the neurodevelopmental outcomes of fetuses of mothers whose pregnancies were complicated by hypertension. Therefore, this study aimed to investigate the impact of maternal hypertension on fetal brain maturation and the protective effects of treatment methods applied during pregnancy, especially magnesium sulfate.

## METHODS

This study was conducted in Ankara Etlik Maternity and Gynecology Training and Research Hospital and Hacettepe University Faculty of Medicine, Department of Histology-Embryology. The study was approved by the local committee of our hospital, and all parents were informed about the objectives of the study and gave written informed consent.

A total of 26 fetuses were included in the study, including 11 fetuses of pregnant women who were found to have hypertension (preeclampsia and/or chronic hypertension) and whose pregnancy was terminated due to this reason, and 15 fetuses who did not have this risk factor but died for various reasons as the

control group. Fetuses that had died intrauterine 12 hours before the abortion were excluded from the study due to the possibility of incorrect results as autolysis of the cells. Additionally, fetuses of parents who refused participation were also excluded.

Pregnant women's age, gravida gestational week, and infants' birth weight were recorded. Pregnancy weeks were determined precisely by taking the last menstrual period and ultrasonographic measurements of the pregnant women included in the study. Spontaneous abortion or delivery was observed during labor in the control group. In case of any obstetric problem, the pregnancy was terminated by cesarean section. Treatments given in the hypertension group (antenatal steroids, tocolysis, magnesium sulfate, and other anti-hypertensive treatments) were recorded.

After normal vaginal delivery, cesarean section, or abortion, fetuses were macroscopically examined and their sex, weight, and malformations were recorded. Then, an incision was made at the level of the anterior fontanelle to access the frontal lobe of the fetal brain by passing through the skin, subcutaneous tissue, and dura mater. Full-thickness tissue samples were taken from the frontal lobe, including the cortex and subcortical layers, and the ventricular wall as much as possible. All samples were taken within 12 hours at most after delivery, abortion, or death of the baby. The material taken for hematoxylin-eosin (H&E) staining was fixed in formaldehyde at room temperature. The material taken for the terminal deoxynucleotidyl transferase dUTP nick end labeling (TUNEL) was transferred to the laboratory environment at -80°C nitrogen medium. Brain tissue samples were evaluated for the presence of morphological and histopathological changes and apoptotic cells. The morphologies of the samples were examined in sections stained with H&E, and apoptosis was examined with light microscopy by the TUNEL method. Histological evaluations of H&E stained specimens were classified as follows: Grade 1: Necrosis in very few cells, Grade 2: Necrotic changes in one area and/or a small number of cells, Grade 3: Necrotic changes in multiple sites and multiple cells. Stasis was evaluated with hemorrhage foci in the cortex, medulla, and periventricular areas and dilatation of vessels. Localization of edema was detected. Edema in both cortex and medulla was evaluated as diffuse edema.

### Statistical Analysis

The data obtained in this study were statistically evaluated using the SPSS (Statistical Package for Social Sciences, IBM Inc. Armonk, NY, USA) statistical software. The normality of the variables was evaluated with the Kolmogorob-Smirnov test. Since the variables were non-normally distributed, the Mann-Whitney test was used to compare continuous variables between two groups. Categorical variables were compared using the Chi-square method. Continuous variables were expressed with median, min-max values, mean ± standard deviation, while categorical variables were given as frequency and percentage. A *p* - value of less than 0.05 was considered statistically significant.

### RESULTS

A total of 26 patients were included in the study with 11 patients being in the hypertension group and 15 patients in the control group. Demographic features and obstetric history of the groups are given in Table 1. As seen in Table 1, gestational week and birth weight were significantly higher in the hypertension group compared with the control group (both *p* < 0.001). There were no significant differences between the two groups in terms of maternal age and gravida (both *p* > 0.05). Oligohydramnios was detected in two patients (18.2%) in the hypertension group, while it was due to membrane rupture in two (13.3%) patients in the control group. Intrauterine growth retardation (IUGR) was found in four (36.4%) infants in the hypertension

group, while none of the infants in the control group had IUGR. Two of all pregnancies were terminated by C/S, and the others were terminated by vaginal delivery. While 27.8% of the infants were stillborn, 72.2% of them died shortly after birth. Magnesium sulfate was administered to six (54.5%) patients with hypertension.

Comparison of the groups in terms of edema, necrosis, and intracranial hemorrhage in the examined brain tissues is presented in Table 2.

### Hematoxylin & Eosin Results

#### Control Group

In the examination of fetal brain samples of 15 patients in the control group, it was observed that the brain tissue had a morphological structure compatible with the development weeks. Neuron nuclei and cytoplasm were in normal histological structure. Only one 17-week-old sample of brain tissue had areas of edema in the neuropil. No edema was observed in other samples (Fig. 1).

#### Hypertension Group

There were no bleeding foci, and brain tissues mostly preserved morphological features similar to those of control patients. Although there was advanced dilatation of the vessels in all of the samples, it was noted that most of them did not have stasis (Fig. 2). In two of the samples with edema, the vessels were both very dilated and occluded. It was observed that necrotic cell density increased in these samples. Necrotic cells were less common in brain samples without edema (Fig. 2).

**Table 1. Demographic features and obstetric history of the groups**

		n	Mean	SD	Median	Min	Max	<i>p</i> value
<b>Maternal age</b>	<b>C</b>	15	29.5	6.7	31	18	43	0.646
	<b>HT</b>	11	27.5	4.8	25	21	33	
<b>Gestational week</b>	<b>C</b>	15	21.7	5.9	20	14	37	< 0.001
	<b>HT</b>	11	29.7	3.3	30	25	35	
<b>Birth weight</b>	<b>C</b>	15	598.7	658.2	400	100	2700	< 0.001
	<b>HT</b>	11	1068.2	417.3	900	600	1700	
<b>Gravida</b>	<b>C</b>	15	2.7	1.2	3	1	5	0.293
	<b>HT</b>	11	2.1	0.7	2	1	3	

HT = hypertension group, C = control group, SD: standard deviation

**Table 2. Edema, necrosis and intracranial hemorrhage in the examined fetal brain tissues**

		C		HT		Total	
		n	%	n	%	n	%
<b>Edema</b>	Yes	1	6.7	5	45.4	6	23.08
	No	14	93.3	6	54.6	20	76.9
	Total	15	100.0	11	100.0	26	100.0
<b>Necrosis</b>	Grade 1	4	26.7	7	63.6	11	42.31
	Grade 2	1	6.7	1	9.1	2	7.69
	Grade 3	0	0.0	0	0.0	0	0.0
	No	10	66.7	3	27.3	13	50.0
	Total	15	100.0	11	100.0	26	100.0

HT = hypertension group, C = control group

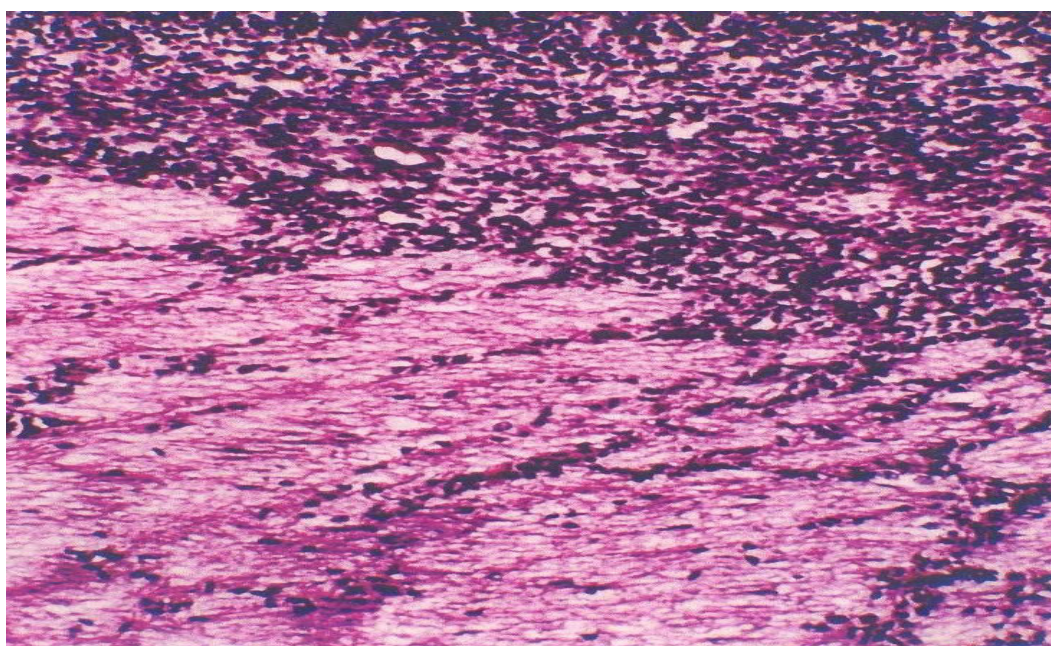
While edema was detected in 45.4% of the infants in the hypertension group, no edema was observed in 54.6%. Edema was detected in 6.7% of the control group, while there was no edema in 86.7% of the cases.

In the hypertension group, Grade 1 necrosis was observed in 63.6% of the samples, Grade 2 necrosis was observed in 9.1%, and no necrosis was observed in 27.3% of the samples. In the control group, 26.7% of the samples had Grade 1 necrosis, 6.7% had Grade

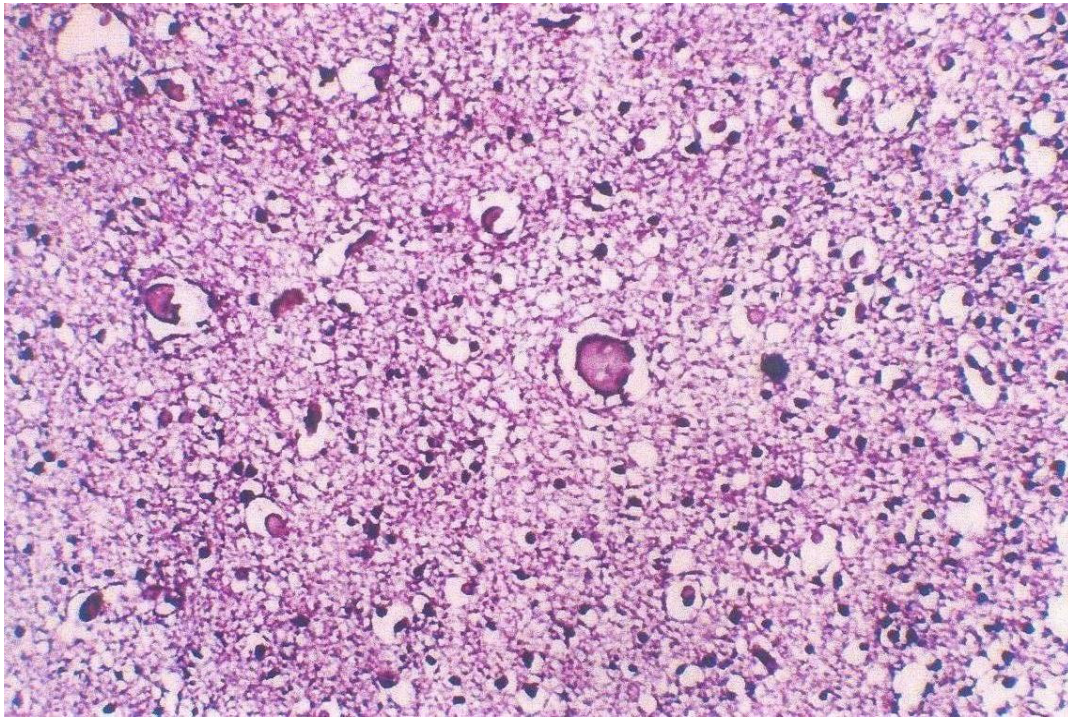
2 necrosis, while 66.7% did not have necrosis. While bleeding was not observed in the hypertension group, 20% of the control group had bleeding. Since the number of cases was insufficient, statistical significance could not be compared.

**Apoptosis Findings Obtained by the TUNEL Method**

A large number of diffuse apoptotic cells, especially dense in the inner cortex, were detected in 15



**Fig. 1.** Cells in the neuroepithelium have a normal histological structure in the fetal brain sample of a 20-week and 2-day infant in the control group (H&E × 20).

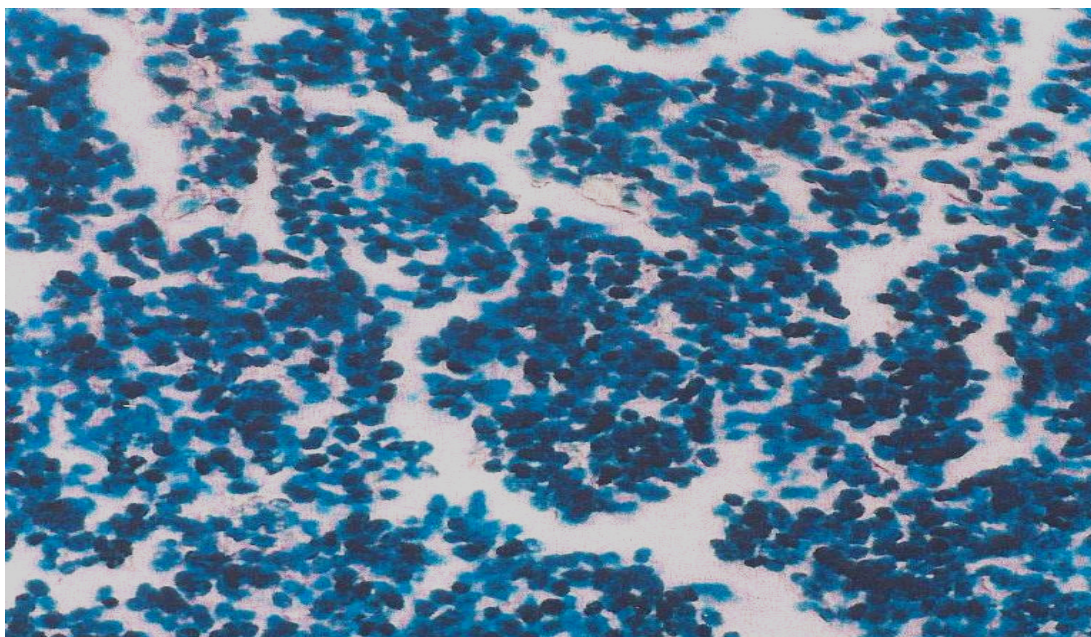


**Fig. 2.** Diffuse edema is noted in the medulla of the 31-week-old fetus in the hypertension group. While dilatation is observed in capillaries, there is stasis with advanced dilatation in larger vessels (H&E  $\times 20$ ).


samples in the control group (physiological apoptosis) (Fig 3).

In the samples from the hypertension group, although the number of apoptotic cells was less com-

pared to the control group, it was observed that they were more concentrated in the cortex. TUNEL apoptotic cells were particularly prevalent in the outer cortex in the hypertension group (Fig. 4).



**Fig. 3.** Diffuse TUNEL-positive apoptotic cells in a 20-week-old fetus (TUNEL  $\times 40$ ).



**Fig. 4.** TUNEL positive apoptotic cells (arrow) in 22-week-old hypertension group fetal brain sample (TUNNEL  $\times$  40).

## DISCUSSION

In this study, before examining the effects of hypertension on the fetal brain, fetal brain samples in the control group were evaluated to get an idea about normal brain development. In the light of the results obtained with hematoxylin-eosin (H&E) staining, which was the first of the methods used for this purpose, it can be said that the neuron nuclei and cytoplasm in the normal fetal brain have a regular histological structure and tissue edema, vessel dilatation and cell necrosis are not normally encountered findings. Despite the absence of abnormal morphological findings, it has been shown that apoptotic cells detected by the TUNEL method in different parts of the fetal brain were found in all normal fetuses, which is consistent with other previous studies showing the presence of cell death in different parts of the brain at different times [13-16].

It was reported that the definition of normally occurring apoptosis may provide a basis for further studies directed at central nervous system (CNS) malformations [17]. In a study investigating apoptosis in the developing brain, Simonati *et al.* examined the fetuses between 12-23 weeks and found apoptotic cells at increasing rates towards the 21st week, especially in the subventricular and ventricular areas, and they said that apoptotic cells were found only around 21-22 weeks in the outer layers [18]. In a study by Jiang *et al.* [19], a progressive increase in the number of TUNEL-positive cells was observed in the devel-

oping cerebral cortex. In another study examining fetuses at earlier weeks, it was shown that there were sparse TUNEL positive cells in the ventricular layer of the neural tube at 4-5 weeks, and the whole brain, particularly the ventricular and subventricular areas, contained apoptotic cells at 7-8 weeks [20].

In general, it can be said that cell death occurs from the 4th week of pregnancy and it starts from the inner layers and shifts outwards after the middle of pregnancy and starts to increase from the 18th week. In a study by Toyoshima *et al.*, it was suggested that proliferation, migration, and neural cell death occur during midgestation in the fetal brain [21]. In the presented study, normal fetuses between 14-37 weeks were examined and diffuse apoptotic cells were detected, especially in the intermediate area and the inner cortex, which includes the subplate. The absence of apoptotic cells in the medulla, which includes the ventricular and subventricular areas, was attributed to the advanced gestational weeks of the fetuses. In our study, the mean gestational week was found as 29.7 in the hypertension and 21.7 in the control group. Physiological apoptosis observed in the inner cortex is thought to serve for the disappearance of these regions in a short time after birth [18].

It is not always easy to determine the effects of maternal hypertension on the development of the infant. Because this development is affected by many other parameters such as IUGR and prematurity. The investigation of how the fetus is affected in the case of maternal hypertension started with the examination

of perinatal mortality rates and different results were obtained. In a study by Nakamura *et al.* [22], maternal hypertensive disorders of pregnancy was found to be associated with an increased risk for in hospital death, but it was also associated with a lower risk for mortality and adverse neurological outcomes in extremely and very preterm infants if all covariates except hypertensive disorders of pregnancy were identical. In a study by Ancel *et al.* [23], it was determined that the survival rate of preterm babies of hypertensive mothers was 96.3% and low perinatal mortality rate was associated with good perinatal care. In another study by Piper *et al.* [24], it was demonstrated that perinatal mortality in preterm infants of hypertensive mothers was decreased compared to infants of normotensive mothers, but perinatal mortality in term infants was higher in infants of hypertensive mothers, and they attributed this result to the fact that the stress created by hypertension reduces mortality due to prematurity. Since infants of hypertensive mothers are exposed to increased placental vascular resistance, it is thought that they undergo some adaptations during intrauterine life and, thanks to these adaptations, they adapt better to extrauterine life after birth. Conversely, in a study by Huang *et al.* [25], maternal hypertensive disorders of pregnancy, particularly eclampsia and severe preeclampsia, was found to be associated with increased risks of overall mortality and various cause specific mortalities in offspring from birth to young adulthood.

In a study by Härkin *et al.* [26], the infants of preeclamptic mothers exhibited an increased risk of intrauterine growth retardation; however, despite this serious complication, these infants exhibited a significant decrease in the risk for severe intraventricular hemorrhage. Epidemiological studies show that cerebral palsy rates increase in infants of pregnant women with hypertension. On the other hand, Gray *et al.* [23] showed that the rates of cerebral palsy and periventricular hemorrhage were lower in preterm infants of hypertensive mothers compared to the control group, and this low rate was found independent of magnesium sulfate treatment. It is biologically possible for magnesium sulfate, one of the drugs used in the treatment of maternal hypertension, to prevent neurological damage. In vitro and in vivo studies have shown that asphyxia, trauma, and N-methyl D-aspartate (NMDA)-mediated neuronal damage can be prevented with magnesium sulfate [27]. The magnesium ion is

required for numerous cellular processes such as glycolysis, oxidative phosphorylation, protein synthesis, DNA and RNA aggregation, and maintaining plasma membrane integrity. Magnesium can reverse the effects of excitatory amino acids that initiate neuronal damage by binding to NMDA receptors, such as glutamate, by competitive inhibition with calcium. In addition, magnesium has been shown to be a cerebral vasodilator [28]. Due to these properties, magnesium sulfate can be said to be a neuroprotective agent. In our study we administered magnesium sulfate in 6/11 (54.5%) patients.

According to research, magnesium sulfate has neuroprotective properties. According to the findings of the current study, maternal hypertension promotes neurological maturation by causing vasodilation in the fetal brain, increasing blood flow, and decreasing cell death. Although these effects were observed in patients who did not receive magnesium sulfate in this study, the existence of a relationship between maternal hypertension and neurological maturation due to the small number of patients and the role of the drugs used in treatment in this relationship is an issue that requires further investigation.

In chronic fetal hypoxia due to hypertensive diseases of pregnancy, there is significant vasoconstriction in the splanchnic bed, pulmonary bed and musculoskeletal systems, while there is an increase in blood flow to the brain, heart and adrenal glands [29]. In our study, vasodilatation, which is thought to develop as a part of the protective effect on the brain, was found in the vessels of the fetal brain tissue in all babies of hypertensive mothers. This finding suggests that pregnancies with brain sparing effect should be terminated in obstetric management before an increase in the fetal cerebral arteries pulsatility index begins. While vasodilation was a finding in all patients in the hypertension group, the absence of significant cell necrosis and the absence of hemorrhage foci are consistent with studies stating that vasodilation in fetal brain vessels to protect the brain does not cause hemorrhage and ischemia in the future.

### Limitations

The main limitation of this study is the small number of patients. Because of this, we could not compare edema, necrosis, hemorrhage and apoptosis statistically between the groups. However, given the limited

studies on this issue we believe that our findings could be guiding for further comprehensive studies with a larger series of patients.

## CONCLUSION

In the light of the findings of this study, it can be said that maternal hypertension increases neurological maturation by causing vasodilation in the fetal brain, increasing blood flow and decreasing cell death. The effects of hypertension on neurological maturation may depend on the effects of drugs used in the treatment and the most important of these is magnesium sulfate.

### Authors' Contribution

Study Conception: MA; Study Design: MA; Supervision: MFK; Funding: BA; Materials: BA; Data Collection and/or Processing: MA; Statistical Analysis and/or Data Interpretation: BA; Literature Review: MFK; Manuscript Preparation: MA and Critical Review: MFK.

### Conflict of interest

The authors disclosed no conflict of interest during the preparation or publication of this manuscript.

### Financing

The authors disclosed that they did not receive any grant during conduction or writing of this study.

## REFERENCES

- Williams K, Carson J, Lo C. Genetics of congenital heart disease. *Biomolecules* 2019;9:879.
- Cuneo BF, Curran LF, Davis N, Elrad H. Trends in prenatal diagnosis of critical cardiac defects in an integrated obstetric and pediatric cardiac imaging center. *J Perinatol* 2004;24:674-8.
- van der Bom T, Zomer AC, Zwinderman AH, Meijboom FJ, Bouma BJ, Mulder BJM. The changing epidemiology of congenital heart disease. *Nat Rev Cardiol* 2011;8:50-60.
- Wu W, He J, Shao X. Incidence and mortality trend of congenital heart disease at the global, regional, and national level, 1990-2017. *Medicine (Baltimore)* 2020;99:e20593.
- Van Velzen CL, Ket JCF, Van de Ven PM, Blom NA, Haak NC. Systematic review and meta-analysis of the performance of second-trimester screening for prenatal detection of congenital heart defects. *Int J Gynaecol Obstet* 2018;140:137-45.
- Marino B, Digilio MC, Toscano A, Giannotti A, Dallapiccola B. Congenital heart diseases in children with Noonan syndrome: an expanded cardiac spectrum with high prevalence of atrioventricular canal. *J Pediatr* 1999;135:703-6.
- Celep G, Ogur G, Gunal N, Baysal K. DiGeorge syndrome (Chromosome 22q11.2 deletion syndrome): a historical perspective with review of 66 patients. *J Surg Med* 2019;3:58-63.
- Pierpont ME, Basson CT, Benson DW, Belb BD, Giglia TM, Goldmuntz E, et al. Genetic basis for congenital heart defects: current knowledge. *Circulation* 2007;115:3015-38.
- Roodpeyma S, Kamali Z, Ashar F, Naraghi S. Risk factors in congenital heart disease. *Clin Pediatr (Phila)* 2002;41:653-8.
- Hartman RJ, Rasmussen SA, Botto LD, Riehle-Colarusso T, Martin CL, Cragan JD, et al. The contribution of chromosomal abnormalities to congenital heart defects: a population-based study. *Pediatr Cardiol* 2011;32:1147-57.
- Paladini D, Tartaglione A, Agangi A, Teodoro A, Forlogo F, Borghese A, et al. The association between congenital heart disease and Down syndrome in prenatal life. *Ultrasound Obstet Gynecol* 2000;15:104-8.
- Ballweg JA, Wernovsky G, Gaynor JW. Neurodevelopmental outcomes following congenital heart surgery. *Pediatr Cardiol* 2007;28:126-33.
- Arduini M, Rosati P, Caforio L, Guariglia L, Clerici G, Di Renzo GC, et al. Cerebral blood flow autoregulation and congenital heart disease: possible causes of abnormal prenatal neurologic development. *J Matern Fetal Neonatal Med* 2011;24:1208-11.
- Morton PD, Ishibashi N, Jonas RA. Neurodevelopmental abnormalities and congenital heart disease: insights into altered brain maturation. *Circ Res* 2017;120:960-77.
- Maulik D, You Laggda AP, Younhood JP, Willonghy L. Components of variability of umbilical arterial Doppler a prospective analysis. *Am J Obstet Gynecol* 1989;160:1406-12.
- Clerici G, Luzietti R, Cutuli A, Direnzo GC. Cerebral hemodynamics and fetal behavioral states. *Ultrasound Obstet Gynecol* 2002;19:340-3.
- Wolf H, Stampalija T, Lees CC; TRUFFLE Study Group. Fetal cerebral blood-flow redistribution: analysis of Doppler reference charts and association of different thresholds with adverse perinatal outcome. *Ultrasound Obstet Gynecol* 2021;58:705-15.
- Barzilay E, Hass J, de Castro H, Yinon Y, Achiron R, Gilboa Y. Measurement of middle cerebral artery diameter as a method for assessment of brain sparing in intra-uterine growth-restricted discordant twins. *Prenat Diagn* 2015;35:137-41.
- Gielecki J, Zurada A, Kozłowska H, Nowak D, Loukas M. Morphometric and volumetric analysis of the middle cerebral artery in human fetuses. *Acta Neurobiol Exp (Wars)* 2009;69:129-37.
- Vena F, Manganaro L, D'Ambrosio V, Masciullo L, Ventriglia F, Ercolani G, et al. Neuroimaging and cerebrovascular changes in fetuses with complex congenital heart disease. *J Clin Med* 2022;11:6740.
- Hahn E, Szwast A, Cnota J, Levine JC, Fifer CG, Jaeggi E, et al. Association between fetal growth, cerebral blood flow and neurodevelopmental outcome in univentricular fetuses. *Ultrasound Obstet Gynecol* 2016;47:460-5.
- Masoller N, Martinez JM, Gomez O, Bennasar M, Crispi F, Sanz-Cortes M, et al. Evidence of second-trimester changes in



head biometry and brain perfusion in fetuses with congenital heart disease. *Ultrasound Obstet Gynecol* 2014;44:182-7.

23. Ancel PY, Livinec F, Larroque B, Marret S, Arnaud C, Pierrat V, et al; EPIPAGE Study Group. Cerebral palsy among very preterm children in relation to gestational age and neonatal ultrasound abnormalities: the EPIPAGE cohort study. *Pediatrics* 2006;117:828-35.

24. Tarzamni MK, Nezami N, Sobhani N, Eshraghi N, Tarzamni M, Talebi Y. Nomograms of Iranian fetal middle cerebral artery Doppler waveforms and uniformity of their pattern with other populations' nomograms. *BMC Pregnancy and Childbirth* 2008;8:50.

25. Zloto K, Hochberg A, Tenenbaum-Gavish K, Berezowsky A, Barbara-Hazan S, Bardin R, et al. Fetal congenital heart disease

- mode of delivery and obstetrical complications. *BMC Pregnancy Childbirth* 2022;22:578.

26. Zeng S, Zhou J, Peng Q, Tian L, Xu G, Zhao Y, et al. Assessment by three-dimensional power Doppler ultrasound of cerebral blood flow perfusion in fetuses with congenital heart disease. *Ultrasound Obstet Gynecol* 2015;45:649-56.

27. Euser AG, Cipolla MJ. Magnesium sulfate for the treatment of eclampsia: a brief review. *Stroke* 2009;40:1169-75.

28. Yamanaka R, Shindo Y, Oka K. Magnesium is a key player in neuronal maturation and neuropathology. *Int J Mol Sci* 2019;20:3439.

29. Maršál K. Physiological adaptation of the growth-restricted fetus. *Best Pract Res Clin Obstet Gynaecol* 2018;49:37-52.



This is an open access article distributed under the terms of [Creative Commons Attribution-NonCommercial-NoDerivatives 4.0 International License](https://creativecommons.org/licenses/by-nc-nd/4.0/).