

The use of fetal bovine acellular dermal matrix for management of chronic wounds

 Tuna Gümüş¹,  Lucian G. Vlad²

¹Department of Undersea and Hyperbaric Medicine, Kartal Dr. Lütfi Kırdar City Hospital, University of Health Sciences, İstanbul, Turkey

²Department of Plastic and Reconstructive Surgery, Wake Forest University School of Medicine, Winston-Salem, NC, USA

Cite this article as: Gümüş T, Vlad LG. The use of fetal bovine acellular dermal matrix for management of chronic wounds. *J Health Sci Med.* 2023;6(4):713-719.

Received: 07.03.2023

Accepted: 08.06.2023

Published: 30.07.2023

ABSTRACT

Aims: In the treatment of chronic wounds, tissue growth must be addressed and optimized. The purpose of this study is to investigate the use of the regenerative medicinal product Fetal Bovine Acellular Dermal Matrix (FBADM) in chronic wounds.

Methods: The patients were chosen sporadically and randomly based on availability to FBADM. Patients were assessed for adequate perfusion, debridement was performed, and wounds were ensured to be free of infection. FBADM was placed in the wound bed covered with a non-adherent contact layer, and a hydrogel sheet was placed to maintain adequate moisture. Offloading or compression was used as clinically indicated. Patients were then followed weekly. Digital photography was used to visually document healing progress.

Results: After 1-3 weeks wounds managed with FBADM had improved characteristics and healthy vascularized tissue that subsequently epithelialized from wound margins or grafted with split thickness skin grafts. Of the 14 wounds we achieved 69% complete healing, 24% non-complete healing after 12 weeks of FBADM application. 7% of the wounds needed skin graft surgery.

Conclusion: We found FBADM to be useful for treatment regimen of diabetic foot and leg ulcers, venous leg ulcers, surgical wounds, and wounds being prepared for skin grafting.

Keywords: Chronic wounds, extracellular matrix, tissue engineering, skin substitutes

INTRODUCTION

FBADM is a dermal repair scaffold composed of natural dermal collagen fibers. The use of FBADM has been reported to promote healing of a range of wound types. The purpose of this study is to evaluate clinical usefulness and gain experience with FBADM in chronic recalcitrant wounds. A retrospective study of thirteen complex patients with difficult to heal full-thickness 14 chronic wounds is presented. Subjects have been retrospectively investigated through their charts.

In order to understand wound healing, it is necessary to master the healing phases.^{1,2} Not all wounds complete their healing phase completely or at all. Factors such as the etiology of the wound, infection status, vascular adequacy, medical or surgical intervention may play a role in this. Healing process is divided into five components of hemostasis, inflammation, proliferation, contraction and remodeling. Hemostasis begins as soon as the wound is formed, along with bleeding. Although vasoconstriction decrease the blood loss enough blood is released in the wound to stimulate Hageman factor

(XII) to initiate the clotting cascade.³ Blood fibrinogen converts to fibrin.⁴ The fibrin cell forms a pathway for cell migration, primarily fibroblasts. Fibroblast is one of the major cells in the proliferative phase of wound healing.⁵ Hemostasis also creates a protective layer, minimizing the risk of infection and creating the optimum environment for the subsequent healing phases. In the subsequent inflammatory phase, vasoconstriction is replaced by vasodilation. Vasodilation is the result of prostoglandin, nitric oxide and other inflammatory mediators in the environment. As plasma fluid fills the interstitial space, migration of white blood cells and diapedesis occur.⁶ In the first 2 phases of wound healing, bleeding was stopped, the wound was debrided, and infection control was achieved. In wounds without a delay in healing, the proliferative phase should start after a few days. In this phase, proliferative cytokines (PDGF, interleukin1, fibroblast growth factor and chemoattractant (transforming growth factor beta) take part and prepare wound healing for the next phase by mobilizing fibroblasts and multiplying them.⁷ The main

Corresponding Author: Tuna Gümüş, tunagumus@yahoo.com



This work is licensed under a Creative Commons Attribution 4.0 International License.

effective cell in the contraction phase fibroblast more specifically is myofibroblast. It involves the reduction of the wound in size.⁸ TGF b is very important in the natural process of the contraction phase. In remodeling phase the wound is characterized by a high level of metabolic activity. The remodeling phase is different from other phases. Hemostasis may take minutes, inflammation days, and proliferation weeks, the remodeling phase may continue for months or years. Initial mixture of Type1 and Type3 collagen density slowly changes into a wound with mainly Type1 collagen.³

This study aims to characterize the effectiveness of using regenerative medicinal product FBADM in chronic wounds, as well as to determine the ability of this matrix to facilitate normal tissue regeneration.

METHODS

A retrospective study of thirteen patients with recalcitrant chronic wounds treated in our advanced wound care center is presented. Subjects have been retrospectively evaluated. This study was initiated with the approval of the Clinical Researches Ethics Committee (Date:19.06.2015, North Carolina, Decision No: 00033880). All procedures were carried out in accordance with ethical rules and principles of the Declaration of Helsinki.

Patients with diabetic and venous wound etiologies were treated in our advanced wound care center. The patients were chosen sporadically and randomly based on availability to FBADM. This research is done with 13 subjects with 14 non-healing wounds those FBADM have been applied in our wound care center.

Patients were assessed for the inclusion and exclusion criteria listed below.

Inclusion criteria:

1. Be over 18 years old
2. Absence of infection according to American Society of Infectious Diseases criteria
3. Adequate vascular circulation (in the last 60 days)
 - a. Ankle-brachial index between (ABI) 0.7-1.2

Exclusion criteria:

1. Be under 18 years old
2. Lack of adequate vascular circulation, ABI <0.7->1.2
3. Presence of infection according to American Society of Infectious Diseases criteria

FBADM was placed in the wound bed covered with a non-adherent contact layer, and a hydrogel sheet was placed to maintain adequate moisture. Offloading or compression was used as clinically indicated. Patients were then followed weekly. Demographics, wound etiology, wound

dimensions, and associated comorbid conditions and complications were recorded. Digital photography was used to visually document healing progress.

Case 1: Post-Operative Dehiscence after Left Achilles Tendon Repair Subject

53 y\o white male with type 2 diabetes mellitus (DM) and peripheral venous insufficiency. PVI developed a wound over his left posterior Achilles after an Achilles tendon repair and heel spur resection surgery. The patient developed partial dehiscence over incision with exposed tendon. Sharp debridement was performed and post debridement measurements of wound were 5 cm×1.5 cm×1.2 cm with an area of 5.8 cm² (Figure 1). After one week of FBADM application the wound demonstrated healthy granulation tissue and had filled significantly. During the entire follow up time he was treated with multi layer compression wraps as well. At 8 weeks entire exposed tendon area was covered with granulation tissue (Figure 2). After 12 weeks the wound had totally reepithelialized (Figure 3).

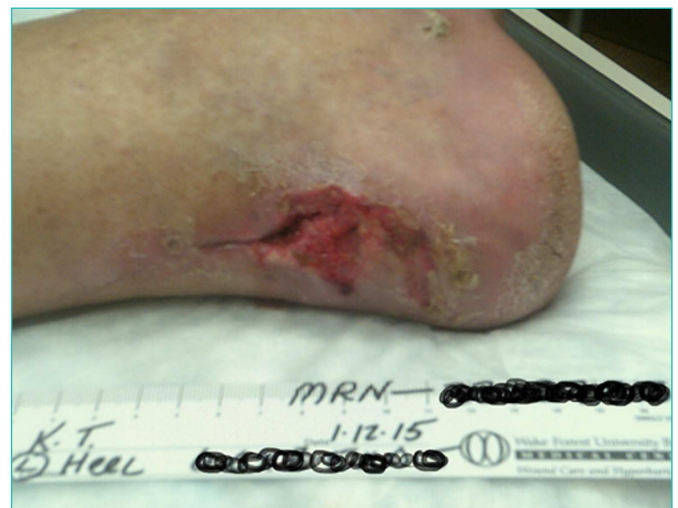

Figure 1. Wound presentation

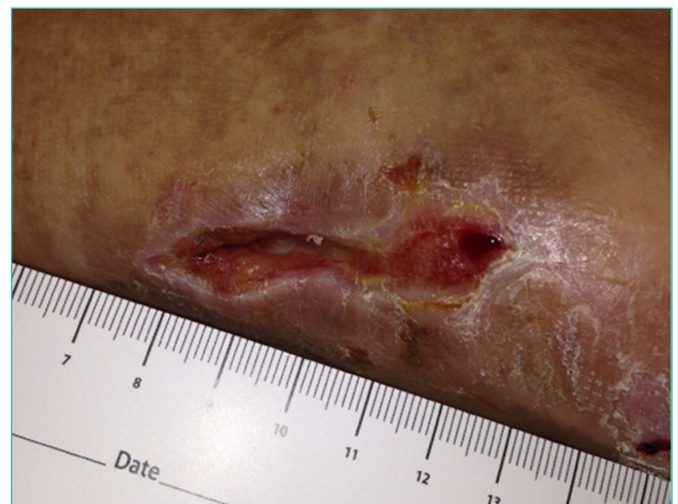

Figure 2. 8 weeks after FBADM application

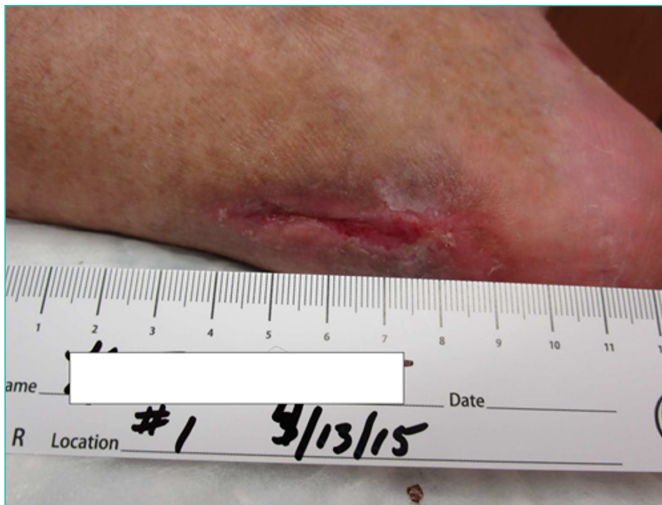

Figure 3. 12 weeks, complete re-epithelization

Case 2: Mixed Chronic Diabetic and Venous Leg Ulcer

41 y/o male with type 2 DM, morbid obesity, (Body Mass Index:38), presents with multiple wounds on both legs. Wounds have been present for the past 5 months. The patient has never received wound care but dry dressings. We decided to apply FBADM to the largest wound which located on left leg posterior which is filled with fibrotic tissue without any granulation, measured as 6.5cm x 11.5 cm x 0.4 cm with an area of 58.7 cm² (Figure 4). At one week after application (Figure 5) there was significant improvement in wound bed quality, healthy granulation, partially integrated FBADM and advancing epithelium at wound edges. Figure 6 (6 weeks) and Figure 7 (9 weeks) show rapid spontaneous epithelium advancing over wound bed from all edges. Patient had sporadic follow up due to personal issues he self reported the wound has healed approximately after 16 weeks. He applied to the wound care center after 24 weeks, the wound was totally healed with immature but intact epithelium (Figure 8). At 28 weeks wound was with mature epithelium, good quality healed skin (Figure 9).

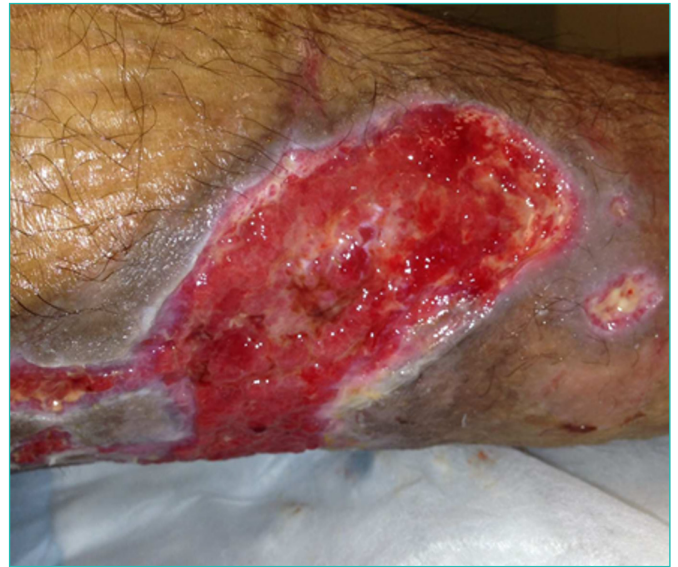

Figure 5. 1 week after FBADM application

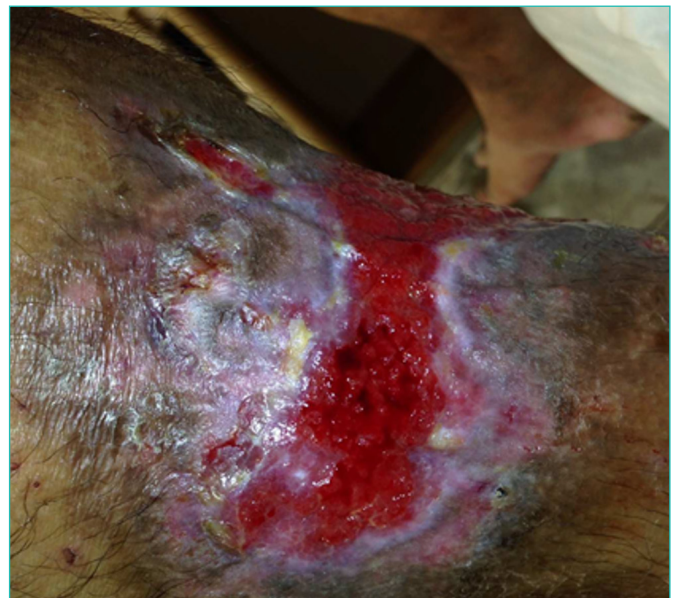

Figure 6. 6 weeks

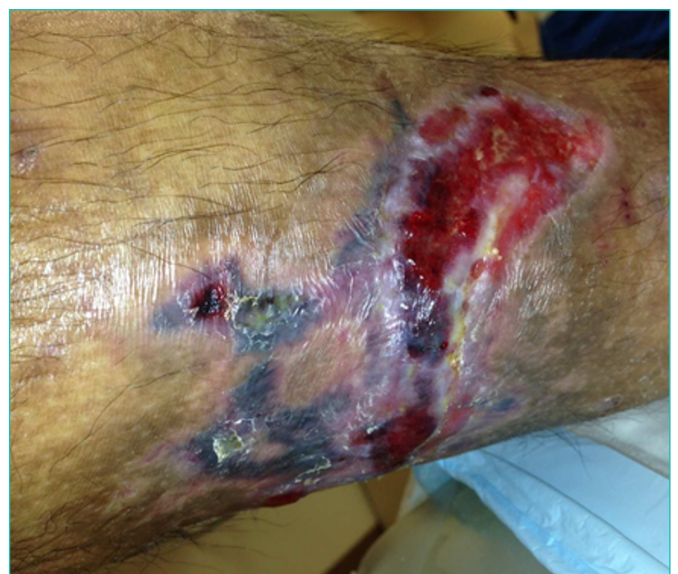

Figure 7. 9 weeks

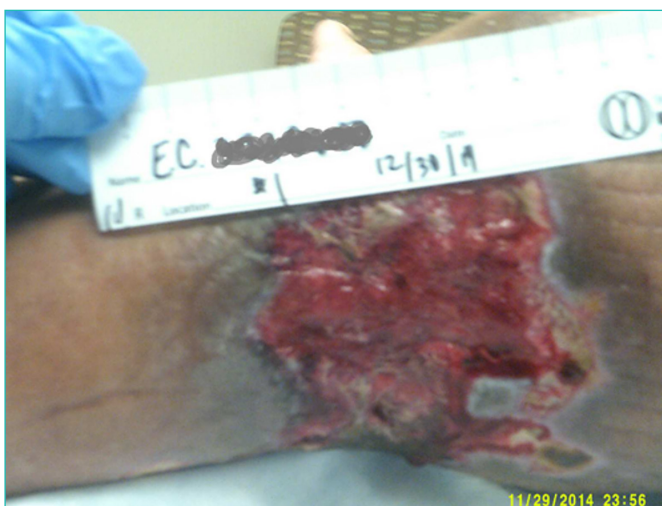

Figure 4. Wound presentation

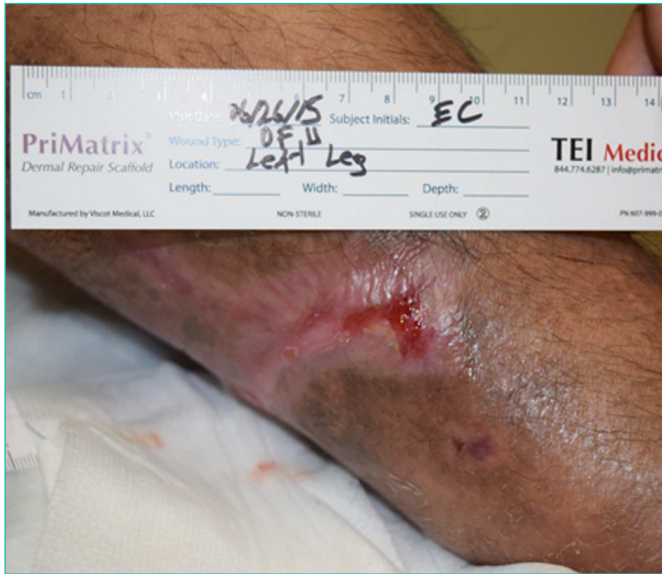

Figure 8. 24 weeks

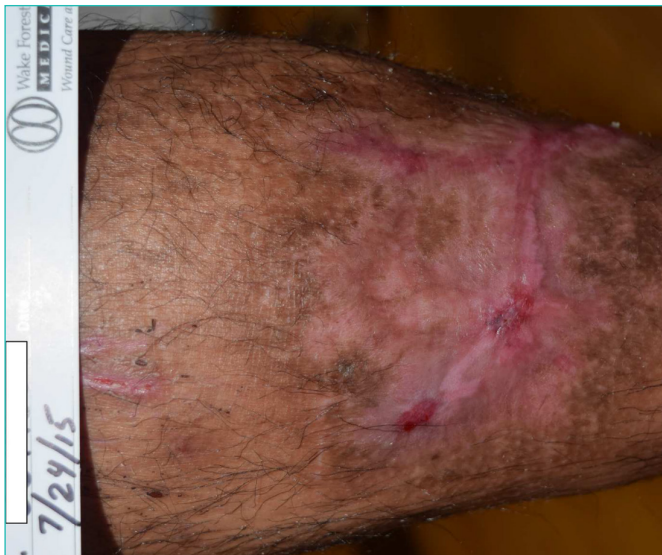

Figure 9. 28 weeks

Sharp debridement was performed and FBADM was applied along with four layer compression bandage. Wound area has reduced to 25.7 cm² and 0.2 cm² at week 4 and week 12 respectively without any complication.

RESULTS

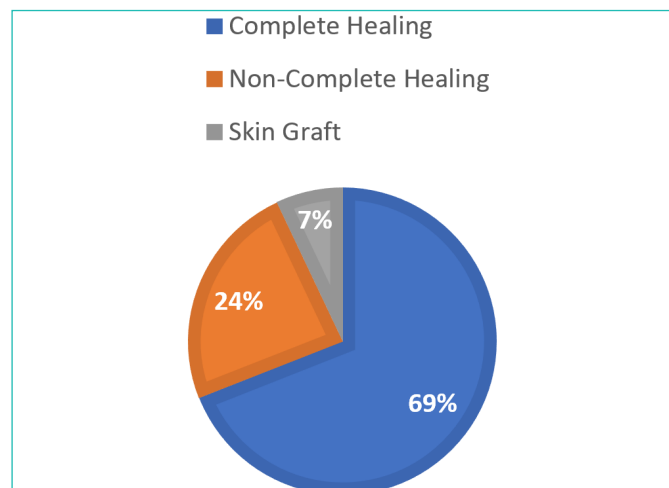
Of the 13 patients, 69% were male, 31% female. 61% were white, 30% African-American, 9% Hispanic. Average body mass index (BMI) was 35.3, and median age was 57 (41 -77). Etiology was also varied, included diabetic foot or leg ulcers (46%), venous leg ulcers (peripheral vein insufficiency – PVI), 2 ulcers (15%) had mixed diabetic and venous insufficiency, other 2 ulcers (15%) had mixed venous and lymphedema etiology, 1 ulcer was in context of sickle cell disease and venous insufficiency and 1 ulcer was caused by scleroderma and venous insufficiency (Table 1).

| Table 1. Subject demographics | |
|-------------------------------|----------------------|
| Subjects | 13 |
| Age | 57 +/- 9.7 (41-77) |
| BMI | 35.3 +/- 2.6 (21-53) |
| Ethnicity | |
| Caucasian | 61% |
| Black | 30% |
| Hispanic | 9% |
| Gender | |
| Male | 59% |
| Female | 31% |
| Etiology | |
| DM | 46% |
| PVI | 38% |
| DM + PVI | 15% |
| Lymphedema + PVI | 15% |
| Sickle cell disease | 7% |
| Scleroderma + PVI | 7% |

Wound chronicity was average 546 days. Including one of the patients had chronic ulcer of approximately 4 years (~1400 days) Excluding this patient, average wound chronicity was 73 days. Average ulcer size was 10.1 +/- 4.3 sq. cm (Table 2).

| Table 2. Wound characteristics | |
|--------------------------------|----------|
| Wound age (days) | 546±159 |
| Wound area (cm ²) | 10.1±5.3 |

After 1-3 weeks wounds managed with FBADM had improved characteristics and healthy vascularized tissue that subsequently epithelized from wound margins or grafted with split thickness skin grafts. 10 ulcers (69%) had complete healing with spontaneous epithelization in the follow up period until 12 weeks. One ulcer had improved wound bed characteristics becoming candidate for split thickness skin grafting at 4 weeks, and although the skin graft did not have 100% take after surgery, the ulcer had healed in the following 6 weeks with wound care. This patient had a previously completely failed attempt at split thickness skin grafting. One patient (7%) had some improvement, but non-complete healing. One patient (7%) had no change and one (7%) had some increase in wound size (worsening) during the 12 weeks follow up period (Graph 1).



Graph 1. Treatment results

DISCUSSION

Wound occurs as a result of deterioration of skin and soft tissue integrity by many mechanisms. Among the causes of chronic wound are factors such as insufficient angiogenesis, insufficient cell migration and insufficient innervation that interrupt the physiological healing process.^{9,10}

There is always a risk of recurrence in healed chronic wounds, especially diabetic foot ulcers.¹¹ Extracellular matrix (ECM) is very important in wound healing. It provides structural support and is the largest dermal layer.¹² In chronic wounds, the ECM is often insufficient. Application of ADM in chronic wounds can be an alternative to ECM.^{13,14} Since there is no cellular component in ADM, it does not produce an immunological response.¹⁵ ADM creates a favorable environment for cellular proliferation and vascularization.¹⁶ As a result of the contact of the ADM with the surrounding tissue, epithelialization and the formation of healthy granulation tissue can be triggered.¹⁷ It is predicted that extracellular matrix equivalents such as ADM are effective in comorbid patients with complex non-healing wounds,^{18,19} and will shorten the recovery time and increase the rate of recovery, and decrease the percentage of amputation, especially in patients with chronic neuropathic ulcers, compared to standard treatment.²⁰

Tissue engineering aim is to produce the product that will either increase the existing organ function or replace it by passing the materials through mechanical and chemical processes. Wound healing process, is a dynamic process in which the communication and relationships of intercellular, ECM and growth factors are effective after the disruption of tissue integrity.²¹ ECM consists of three-dimensional space with structural proteins, laminins, proteoglycans, hyaluronic acid, collagens, fibronectins and elastins. In addition to being a structural support for cells, ECM binds to growth factors and is a reservoir for active molecules that are effective in cell proliferation and

migration after loss of tissue integrity.²² In many chronic wounds, the increased number of inflammatory cells causes an increase in protease levels and breaks down and reduces ECM components, such as growth factors and proteins, which are essential in the healing process.²³

During ADM construction, all living cells are removed. These matrices or scaffolds provide a collagen structure for tissue remodeling. The purpose of removing viable cells is to prevent an inflammatory or immunological response.²⁴ We can define the function of acellular matrices as a biological modulator that affects the biological process of wound healing.

ADM prepares a bed for cell growth and granulation tissue formation, contains receptors for fibroblasts to attach to tissue support, and stimulates angiogenesis. It contains and protects growth factors.²⁵ When implanted, the ADM must be fully inserted into the wound. It is thought that ADMs provide normal wound healing by forming a biological cover.^{26,27} FBADM is rich in collagen type 3. This type of collagen has important role in proliferative stage of wound healing and in stimulating tissue regeneration processes. It is not denatured or cross-linked during manufacturing process.²⁸

In recent years, a wide range of skin substitutes has been developed. These products have been largely used as a reconstructive option for skin loss and defects in chronic wounds. Although an optimal skin substitute is not yet available, these products address the various challenges of wound healing.²⁹

FBADM remains morphologically identical to natural tissue structure, which provides a preferred environment for cellular migration and proliferation. The mechanical property of this matrix is similar to the adjacent environment.³⁰ The main advantage of FBADM is represented by the lack of morbidity of the donor areas, less surgical time related to the procedure, and faster rehabilitation. These innovative biomaterials provide easier and less stressful possibilities for non healing wounds.³¹ This ECM derived from decellularized fetal bovine dermis intended for the treatment of non healing ulcers, second-degree burns, and surgical wounds, rich in type III collagen, which is the first type of collagen synthesized during both embryonic development and wound healing.^{32,33} In addition to providing elasticity to the ECM, type III collagen has been shown to promote migration of fibroblasts,³⁴ and to be an essential regulator of ECM deposition and organization,³⁵ FBADM becomes incorporated into the wound and rapidly degrades and has shown success for the treatment of acute full-thickness wounds.³⁶ FBADM has several advantages relating to its source tissue and manufacturing process, which may have contributed to the limited inflammatory response.³⁷

Despite all the FBADM benefits, complications such as hematoma, seroma, necrosis, and infection must be considered. Also, FBADM is an expensive product and this can make it unsuitable for many patients. More work should be done to achieve cheaper FBADM to make it a cost-effective choice. Another potential disadvantage of FBADM is its limited size options. The studies on FBADM is inadequate, and more research on the results of FBADM usage in chronic wounds is needed.

This study, included recalcitrant ulcers of various etiologies with overall satisfactory results. According to the findings FBADM can stimulate tissue regeneration and reset wound healing to allow progression through stage beyond the inflammatory phase where most of the wounds become chronic.

CONCLUSION

We found FBADM to be useful for treatment regimen of diabetic foot and leg ulcers, venous leg ulcers, surgical wounds, and wounds being prepared for skin grafting. Future comparative and prospective evaluations are needed.

ETHICAL DECLARATIONS

Ethics Committee Approval: The study was carried out with the permission of Wake Forest University Faculty of Medicine Clinical Researches Ethics Committee (Date: 19.06.2015, Decision No: 00033880)

Informed Consent: All patients signed and free and informed consent form.

Referee Evaluation Process: Externally peer reviewed.

Conflict of Interest Statement: The authors have no conflicts of interest to declare.

Financial Disclosure: The authors declared that this study has received no financial support.

Author Contributions: All the authors declare that they have all participated in the design, execution, and analysis of the paper, and that they have approved the final version.

REFERENCES

- Hayn E. Successful treatment of complex traumatic and surgical wounds with a foetal bovine dermal matrix. *Int Wound*. 2014;11(6):675-680. doi: 10.1111/iwj.12028. Epub 2013 Mar 4.
- James S A Neill, William C Lineaweaver. Tissue response to bovine fetal collagen extracellular matrix in full-thickness skin wounds. *Am J Clin Pathol*. 2013;140(2):248-252. doi: 10.1309/AJCPMF3B9XJAKXKM.3.
- Monaco JL., Lawrence WT. Acute wound healing an overview. *Clin Plast Surg*. 2003;30(1):1-12. doi: 10.1016/s0094-1298(02)00070-6.
- Herndon DN, Nguyen TT, Gilpin DA. Growth factors. Local and systemic. *Arch Surg*. 1993;128(11):1227-1233. doi: 10.1001/archsurg.1993.01420230055009.
- Wang D, Chen H, Lei L, et al. Biofabricated macrophage and fibroblast membranes synergistically promote skin wound healing. *Bioeng Transl Med*. 2022;7(3):e10344. doi:10.1002/btm2.10344
- P Martin, J Hopkinson-Woolley, J McCluskey. Growth factors and cutaneous wound repair. *Prog Growth Factor Res*. 1992;4(1):25-44. doi: 10.1016/0955-2235(92)90003-z.
- Postlethwaite AE, Keski-Oja J, Moses HL, Kang AH. Stimulation of the chemotactic migration of human fibroblasts by transforming growth factor beta. *J Exp Med*. 1987;165(1):251-256. doi:10.1084/jem.165.1.251
- Tomasek JJ, Gabbiani G, Hinz B, Chaponnier C, Brown RA. Myofibroblasts and mechano-regulation of connective tissue remodelling. *Nat Rev Mol Cell Biol*. 2002;3(5):349-363. doi:10.1038/nrm809
- Golinko MS, Clark S, Rennert R, et al. Wound emergencies: the importance of assessment, documentation, and early treatment using a wound electronic medical record. *Ostomy Wound Manag*. 2009;55:54.
- Armstrong DG, Gurtner GC. A histologically hostile environment made more hospitable? *Nat Rev Endocrinol*. 2018;14:511.
- Armstrong DG, Boulton AJM, Bus SA. Diabetic foot ulcers and their recurrence. *N Engl J Med*. 2017;376:2367.
- Kirsner RS, Bohn G, Driver VR, et al. Human acellular dermal wound matrix: evidence and experience. *Int Wound J*. 2015;12(6):646-654. doi:10.1111/iwj.12185
- Brigido SA, Schwartz E, McCarroll R, Hardin-Young J. Use of an acellular flowable dermal replacement scaffold on lower extremity sinus tract wounds: a retrospective series. *Foot Ankle Spec*. 2009;2(2):67-72. doi:10.1177/1938640009333474
- Jeon M, Kim SY. Application of a paste-type acellular dermal matrix for coverage of chronic ulcerative wounds. *Arch Plast Surg*. 2018;45(6):564-571. doi:10.5999/aps.2018.00605
- Marston WA, Hanft J, Norwood P, Pollak R; Dermagraft Diabetic Foot Ulcer Study Group. The efficacy and safety of Dermagraft in improving the healing of chronic diabetic foot ulcers: results of a prospective randomized trial. *Diabetes Care*. 2003;26(6):1701-1705. doi:10.2337/diacare.26.6.1701
- Nicholas MN, Yeung J. Current Status and Future of Skin Substitutes for Chronic Wound Healing. *J Cutan Med Surg*. 2017;21(1):23-30. doi:10.1177/1203475416664037
- Zelen CM, Serena TE, Gould L, et al. Treatment of chronic diabetic lower extremity ulcers with advanced therapies: a prospective, randomised, controlled, multi-centre comparative study examining clinical efficacy and cost. *Int Wound J*. 2016;13(2):272-282. doi:10.1111/iwj.12566
- Karr JC. Retrospective comparison of diabetic foot ulcer and venous stasis ulcer healing outcome between a dermal repair scaffold (PriMatrix) and a bilayered living cell therapy (Apligraf) *Advances in Skin & Wound Care*. 2011;24(3):119-125.
- Lullove E. Acellular fetal bovine dermal matrix in the treatment of nonhealing wounds in patients with complex comorbidities. *J Am Pediatr Med Assoc*. 2012;102(3):233-239.
- Kavros SJ. Acellular fetal bovine dermal matrix for treatment of chronic ulcerations of the midfoot associated with charcot neuroarthropathy. *Foot & Ankle Specialist*. 2012;5(4):230-234.
- Clark RA, Ghosh K, Tonnesen MG. Tissue engineering for cutaneous wounds. *J Invest Dermatol*. 2007; 127(5): 1018-1029.
- Schultz GS, Wysocki A. Interactions between extracellular matrix and growth factors in wound healing. *Wound Repair Regen*. 2009;17(2):153-162.
- Gibson D, Cullen B, Legerstee R, et al. MMPs Made Easy. *Wounds Int*. 2009; 1(1).
- Nataraj C, Ritter G, Dumas S, et al. Extracellular wound matrices: novel stabilisation and sterilisation method for collagen-based biologic wound dressings. *Wounds*. 2007; 19(6):148-156.

25. Hodde JP, Hiles MC. Bioactive FGF-2 in sterilized extracellular matrix. *Wounds*. 2001;13(5):195-201.
26. Wiegand C, Abel M, Ruth P, Hipler UC. Influence of the collagen origin on the binding affinity for neutrophil elastase. Abstract presented at: 18th Conference of the European Wound Management Association (EWMA); May 14-16, 2008.
27. Mulder G, Lee DK. A retrospective clinical review of extracellular matrices for tissue reconstruction: equine pericardium as a biological covering to assist with wound closure. *Wounds*. 2009;21(9):254-61.
28. Cornwell KG, Landsman A, James KS. Extracellular matrix biomaterials for soft tissue repair. *Clinics in Podiatric Medicine and Surgery* vol. 26, no. 4, pp. 2009:507-23.
29. Limova M. Active wound coverings: bioengineered skin and dermal substitutes. *Surg Clin North Am*. 2010; ;90(6):1237-1255.
30. Wilson GJ, Courtman DW, Klement P, Michael Lee J, Yeger H. Acellular matrix: a biomaterials approach for coronary artery bypass and heart valve replacement. *Ann Thorac Surg*. 1995;60:353-358.
31. Onesti MG, Carella S, Maruccia M, Marchese C, Fino P, Scuderi N. A successful combined treatment with dermal substitutes and products of regenerative medicine in a patient affected by extravasation injury from hypertonic solution. *In Vivo* 2012;26(1):139-142.
32. Smith LT, Holbrook KA, Madri JA. Collagen types I, III, and V in human embryonic and fetal skin. *Am J Anat*. 1986;175:507-521.
33. Sykes B, Puddle B, Francis M, Smith R. The estimation of two collagens from human dermis by interrupted gel electrophoresis. *Biochem Biophys Res Commun*. 1976;72:1472-1480.
34. Postlethwaite AE, Seyer JM, Kang AH. Chemotactic attraction of human fibroblasts to type I, II, and III collagens and collagen-derived peptides. *Proc Natl Acad Sci U S A*. 1978;75:871-875.
35. Liu X, Wu H, Byrne M, Krane S, Jaenisch R. Type III collagen is crucial for collagen I fibrillogenesis and for normal cardiovascular development. *Proc Natl Acad Sci U S A*. 1997;94:1852-1856.
36. Wanitphakdeedecha R, Chen TM, Nguyen TH. The use of acellular, fetal bovine dermal matrix for acute, full-thickness wounds. *J Drugs Dermatol*. 2008;7:781-784.
37. Cornwell KG, Landsman A, James KS. Extracellular matrix biomaterials for soft tissue repair. *Clin Podiatr Med Surg*. 2009;26(4):507-523. doi:10.1016/j.cpm.2009.08.001