

## A Case of Perianal Fistula Mimicking Pilonidal Sinus

### Pilonidal Sinüsü Taklit Eden Perianal Fistül Olgusu

Nazım Agaoglu<sup>1</sup>, Mehmet Ulusahin<sup>1\*</sup>, Serkan Tayar<sup>2</sup>

<sup>1</sup>Karadeniz Technical University, Faculty of Medicine, Department of General Surgery, 61080 Trabzon, Türkiye

<sup>2</sup>Medical Park Trabzon Karadeniz Hospital, General Surgery Clinic, Trabzon Turkey

\*Corresponding author e-mail: [ulusahinmehmet@hotmail.com](mailto:ulusahinmehmet@hotmail.com)

<sup>1</sup><https://orcid.org/0000-0003-4326-4607>

<sup>2</sup><https://orcid.org/0000-0002-0212-2103>

<sup>3</sup><https://orcid.org/0000-0001-5174-2416>

#### ABSTRACT

A case of perianal fistula mimicking pilonidal sinus is presented. The fistula was diagnosed with magnetic resonance imaging (MRI) examination and confirmed with examination under anesthesia by retrograde manipulation of the probe at Morgagni crypts and continuity of the tract up to the external opening in the sacrococcygeal region was confirmed. Tract of the fistula excised down to intergluteal cleft and the rest of the tract curetted. Patient was followed up to 3 months with complete healing of the fistula. In this unusual case we aimed to draw attention to rare presentation of perianal fistula with an external opening located as far as the sacrococcygeal region mimicking pilonidal sinus. Differentiating unusual presentation of perianal fistula from pilonidal disease sometimes is challenging.

**Keywords:** Fistula, Perianal, Pilonidal sinus

#### ÖZET

Pilonidal sinüsü taklit eden bir perianal fistül olgusu sunulmuştur. Fistül tanısı manyetik rezonans görüntüleme (MRG) ile konuldu. Anestezi altında yapılan muayenede Morgagni kriptlerinden probun retrograd manipülasyonu ile sakrokoksigeal bölgedeki dış açıklığa kadar fistül traktının devam ettiği görüldü. Fistül traktı intergluteal yarık seviyesine kadar eksize edildi ve traktın geri kalanı kürete edildi. Hasta 3. aya kadar takip edildi ve fistülün tamamen iyileştiği gözlemlendi. Bu yazıda perianal fistülün sakrokoksigeal bölgeye kadar uzanarak pilonidal sinüsü taklit eden nadir bir formuna dikkat çekmeyi amaçladık. Olağandışı yerleşimli perianal fistülü pilonidal sinüsten ayırdetmek bazen zor olabilir.

**Anahtar Kelimeler:** Fistül, Perianal, Pilonidal sinüs

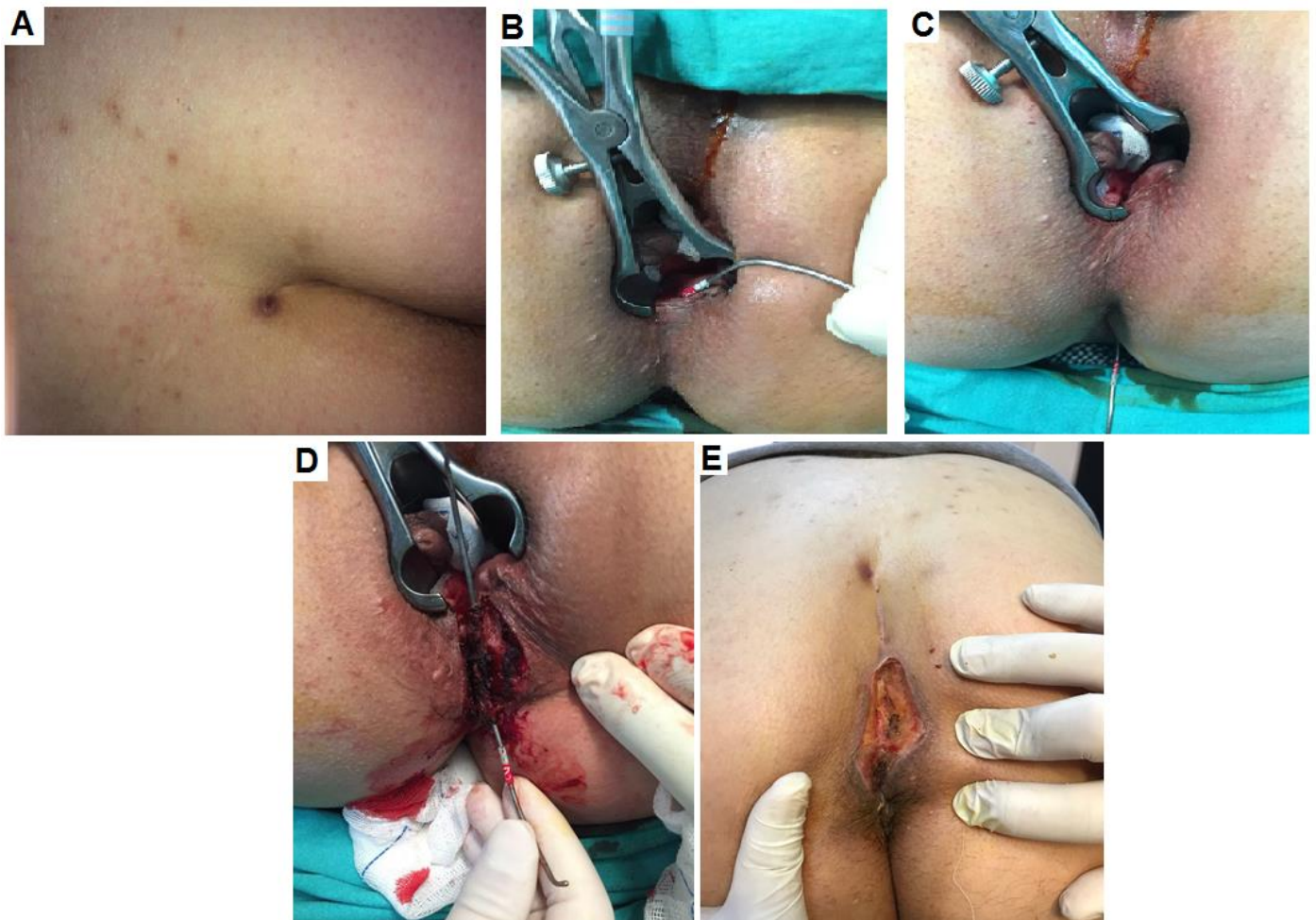
## INTRODUCTION

Perianal fistula results from suppuration in the cryptogenic anal glands located in the intersphincteric space advanced to a well formed anorectal abscess which bursts spontaneously or was drained inadequately and classically the external opening of the fistula is located within few centimeters of the anal verge. Another entity is pilonidal sinus which usually presents as a pit in midline of sacrococcygeal region with recurrent suppuration, pain, discharge and usually contains hair tufts within the depth of the sinus. However there are atypical presentations of the pilonidal disease complicated with fistula formation extending to the perianal region or even to inside the anal canal.<sup>1-7</sup> Pilonidal disease and perianal fistula are two distinctive pathological conditions but in rare occasion they are inter-related in their clinical presentations and might be a source of confusion in the definitive diagnosis. Here we present a rare case of

perianal fistula with external opening far in the sacrococcygeal region mimicking pilonidal sinus.

## CASE REPORT

A 39-year old male presented to our surgical department complaining of discharge and discomfort at the perianal region. Physical examination revealed only a small opening in the sacrococcygeal region resembling pilonidal sinus with no hair visible from the aperture (Figure 1A). Digital and anoscopic examination of the anal canal was of no significance. Magnetic resonance imaging (MRI) examination revealed a posterior intersphincteric anorectal fistula with internal opening at 6 o'clock of the anal canal but no obvious external opening in vicinity of the anus. After adequate bowel preparation and prophylactic antibiotic cover the patient was examined under anesthesia in lithotomy position. Internal opening of the fistula located about dentate line at 6 o'clock was identified with gentle retrograde manipulation of the probe at the base of Morgagni columns namely Morgagni crypts (Figure 1B).



**Figure 1.** Physical examination revealed a pit in the sacrococcygeal region resembling pilonidal sinus, (B) Internal opening of the fistula located at 6 o'clock was identified with the probe at the depth of Morgagni crypt, (C) The probe passed through the opening in the sacrococcygeal region which could be advanced down to the same perianal region and continuity of the tract was confirmed, (D) The tract of the fistula was excised down to intergluteal cleft and left open to allow free drainage, (E) Healing process of the fistula after 3 weeks of fistulectomy.

The probe advanced easily through the perianal region and intergluteal cleft toward the opening in the sacrococcygeal region. Then the probe passed through the opening in the sacrococcygeal region which could be advanced down to the same perianal region and continuity of the tract was confirmed (Figure 1C). The tract of the fistula was excised down to intergluteal cleft and left open to allow free drainage (Figure 1D). The remaining portion of the tract was curetted till the external opening in the sacrococcygeal region. Patient was discharged with routine dressing and followed up to 3 months until complete healing of the fistula and closure of the pit in the sacrococcygeal region (Figure 1E).

## **DISCUSSION**

Perianal fistula is an established tract lined with granulation tissue with internal opening in the anal canal and classically drains through an external opening within few centimeters of the anal verge. The position of the external and internal holes from the diagnosis of perianal fistula can give an idea about the fistula trace. According to the Goodsall salmon rule; If the external hole is anterior to the transverse line drawn from the middle of the anal orifice, it opens radially to the anterior of the anal canal, and an external hole behind the line opens to the posterior midline. External holes more than 3 cm from the anal verge are opened in the posterior midline wherever they are located.<sup>8</sup> Commonly the main complaint of the patient is persistent sero-purulent discharge that cause irritation and discomfort in the perianal region. On other hand pilonidal sinus classically presents as a pit in midline of sacrococcygeal region with recurrent suppuration and discharge. However there are atypical presentation of the pilonidal disease complicated with fistula formation extending down to the perianal region or even to inside the anal canal which might raise suspicion of anorectal fistula.<sup>1-7</sup> Occasionally, distinction between these two separate pathological conditions is difficult with physical examination. However in patients with pilonidal disease with fistula formation extending to perianal region features of perianal and deep-seated sepsis, characteristic of fistula in ano are also found but the absence of intersphincteric sepsis or enteric opening allows reliable MRI imaging distinction between the two conditions.<sup>9</sup> In pilonidal disease on examination under anesthesia with fistula to perianal area an internal opening to anal canal is absent and usually there are tufts

of hair within the cavity. We believe that in this particular case of perianal fistula the tract of the fistula extended through the perianal region and intergluteal cleft toward the opening in the sacrococcygeal region simulating pilonidal disease. This conception is based on the facts that there was an internal opening of the fistula at the depth of Morgagni crypt illustrated at the anal examination under general anesthesia, MRI examination which revealed clearly a posterior intersphincteric sepsis, anorectal fistula with an internal opening at the anal canal and the absence of hair tufts within the pit in sacrococcygeal region which are usually but not always present in pilonidal disease. Coexistence of these two conditions, pilonidal disease and fistula in ano, at the same time with an established tract between them is another possibility which could not verified from the patient.

## **CONCLUSION**

In this unusual case we aimed to draw attention to rare presentation of perianal fistula with an external opening located as far as the sacrococcygeal region mimicking pilonidal sinus. Differentiating unusual presentation of perianal fistula from pilonidal disease sometimes is challenging.

### **Authorship contribution statement**

Consept and desing: NA, MU, ST.

Acquisition of data: NA, MU.

Analysis and interpretation of data: NA, MU.

Drafting of the manuscript: NA, MU, ST.

Critical revision of the manuscript for important intellectual content: NA, MU, ST.

Supervision: NA, MU.

### **Declaration of competing interest**

All contributing authors declare that they have no conflicts of interest.

### **Availability of data and materials**

All data generated or analyzed during this study are included in this published article.

### **Funding**

The authors declared that this study has received no financial support.

## **REFERENCES**

1. Accarpio G, Davini MD, Fazio A, Senussi OH, Yakubovich A. Pilonidal sinus with an anal canal fistula. Report of a case. *Dis Colon Rectum*. 1988; 31(12): 965-967. DOI: 10.1007/BF02554896.

2. Garg P. Anal fistula and pilonidal sinus disease coexisting simultaneously: An audit in a cohort of 1284 patients. *Int Wound J.* 2019; 16(5): 1199-1205. DOI: 10.1111/iwj.13187.
3. Taylor BA, Hughes LE. Circumferential perianal pilonidal sinuses. *Dis Colon Rectum.* 1984; 27(2): 120-122. DOI: 10.1007/BF02553991.
4. Iqbal CW, Gasior AC, Snyder CL. Pilonidal disease mimicking fistula-in-ano in a 15-year-old female. *Case Rep Surg.* 2012; 2012: 310187. DOI: 10.1155/2012/310187.
5. Eberspacher C, Mascagni D, Fralleone L, et al. Pilonidal disease mimicking anterior anal fistula and associated with posterior anal fistula: a two-step surgery. Case report. *G Chir.* 2017; 38(6): 313-317. DOI: 10.11138/gchir/2017.38.6.313.
6. Kumar P, Betigeri GG, Hasanrabba S. Pilonidal disease mimicking as fistula in ano a rare case report. *JEMDS* 2013; 2(12): 1939-44. DOI: 10.14260/jemds/484.
7. Mallinath IT, Aradhyamath S. Posterior High Anal Fistula can mimic Pilonidal Sinus-A Case Report. *JAIMS* 2022; 7(2): 113-119.
8. Gaertner WB, Burgess PL, Davids JS, et al. The American Society of Colon and Rectal Surgeons Clinical Practice Guidelines for the Management of Anorectal Abscess, Fistula-in-Ano, and Rectovaginal Fistula. *Dis Colon Rectum.* 2022; 65(8): 964-985. DOI: 10.1097/DCR.0000000000002473.
9. Taylor SA, Halligan S, Bartram CI. Pilonidal sinus disease: MR imaging distinction from fistula in ano. *Radiology.* 2003; 226(3): 662-667. DOI: 10.1148/radiol.2263011758.

**To Cite:** Agaoglu N, Ulusahin M, Tayar S. A Case of Perianal Fistula Mimicking Pilonidal Sinus. *Farabi Med J.* 2023; 2(4): 28-31. DOI: 10.59518/farabimedj.1263475.