

BELLE TEN

Cilt : XIX

Ekim 1955

Sayı : 76

A REVIEW OF THE ORDER OF ERUPTION OF THE
PERMANENT TEETH IN FOSSIL HOMINIDS

MUZAFFER ŞENYÜREK, Ph. D.

Professor of Anthropology and Chairman of the Division of Palaeoanthropology
University of Ankara

Information on the order of eruption of the permanent teeth in fossil hominids, unlike that on the living anthropoids and recent Europeans, is rather scanty and most of this data is scattered through the literature. Although it is true that in some of the more recent publications mention is made of the eruption of permanent teeth in the known forms of fossil hominids in general, in most cases these references are only brief.¹ In view of this I have considered it worthwhile to review the literature on this subject to see what is definitely known about the order of eruption of the permanent teeth in the fossil hominids and to what extent they resemble the anthropoid apes and

¹ See Drennan, 1932, pp. 492-493; Boule, Vallois and Verneau, 1934, p. 145; Matiegka, 1934, p. 133; Schultz, 1935, p. 542; Bay, 1946/47, p. 4; Schultz, 1950B, fig. 7; Weidenreich, 1937, p. 122; Dart, 1948, p. 394; Broom and Robinson, 1951, p. 443; Broom and Robinson, 1952, pp. 88-89; Le Gros Clark, 1952, p. 49; Clements and Zuckerman, 1953, pp. 324-331.

It may be mentioned here that although Clements and Zuckerman have treated the Swartkrans material at length and in a critical manner (see Clements and Zuckerman, 1953, pp. 325-330) they have referred to the order of eruption of the permanent teeth in other fossil hominids only too briefly.

differ from the modern Europeans. The results of this review, based mostly on the published reports, are given below. In this study the definition of an erupting tooth given by Schultz² has been adopted. Schultz states: "*In the skulls of primates a tooth is considered to be erupting when the uppermost portion of its crown reaches clearly above and not merely to the alveolar margin. In many juvenile skulls one or more permanent Premolars can be seen underneath the corresponding deciduous molars which are evidently almost ready to drop out. Even though a Premolar actually projects above the alveolar margin, it is not counted as an erupting tooth until the deciduous molar to be replaced has definitely lost its hold by even the last of its roots.*"³

ERUPTION OF THE PERMANENT TEETH IN AUSTRALOPITHECINAE

Australopithecus: Among the material assigned to this genus, there are four specimens which yield information about the order of eruption of the permanent teeth. These are the child's skull found at Taungs, which was originally described by Dart,⁴ two mandibles, one of an adolescent and the other of an adult female individual, from Makapansgat (Makapan), again studied by Dart⁵ and the mandibular fragment of a child from Sterkfontein, originally described by Broom and Robinson as *Plesianthropus*.⁶ But as in a recent study, Robinson⁷ has eliminated the genus *Plesianthropus* of Broom,

² Schultz, 1935, p. 494.

³ Ibid., p. 494. In this regard Clements and Zuckerman (1953, p. 314) also have stated: "*In both sets of records teeth were classified as non-erupted, when their crowns were below the level of the alveolar margin; as erupting, when the entire top of the crown was above the alveolar margin or, in the case of living and embalmed animals, had just pierced the gum; or as erupted, when the tooth was fully or almost completely in place.*"

⁴ Dart, 1925.

⁵ Dart, 1948 and 1954.

⁶ Broom and Robinson, 1950, p. 50.

⁷ Robinson, 1954A, pp. 196 and 198. In this recent study Robinson (1954A, pp. 196 and 198) retains genus *Paranthropus* Broom, but places Broom's *Plesianthropus* in genus *Australopithecus* Dart. Regarding the division of genus *Australopithecus* Robinson (1954A, p. 199) states: "*Australopithecus contains a single species with two subspecies, containing the specimens from Taungs, Sterkfontein, Makapan and East Africa.*"

However, it should be mentioned here that in a recent study on the East African remains, referred to by Robinson, I came to the following conclusion (Şen-

including all the specimens formerly described under this heading in genus *Australopithecus* Dart, this Sterkfontein mandible is here also considered with other remains of *Australopithecus*. According to Oakley, who has recently reviewed the evidence on the relative dating of australopithecine bearing beds, Makapansgat remains appear to be earlier than those from Taungs and Sterkfontein.⁸

The state of eruption of the permanent teeth in the adolescent mandible from Makapansgat was described by Dart as follows: "In *Australopithecus prometheus* the second permanent molars are both fully erupted, and yet, although the first premolar on the left side has erupted, the one on the right is only half erupted and the second premolars have not as yet emerged from their eruption canals. The well-worn second milk molar is still in position on the right side; while, on the left side, the crown of the second premolar is partially exposed as it lies in its eruption canal. This pattern in which the second molars erupt before the premolars (that ordinarily erupt in the 9th and 10th years) is found in the anthropoids and lower primates; but it does also occur in some human races such as the Bushman (Drennan, '32), Neanderthal Man, and even the race represented by the sapient human youth from Grimaldi."⁹ This is all that is said by Dart about the sequence of eruption of the permanent teeth in the Makapansgat mandible, referred by him to *Australopithecus prometheus*,¹⁰ which is now classified as *Australopithecus africanus transvaalensis* by Robinson.¹¹

In a more recent publication, Broom and Robinson give the sequence of eruption of the permanent teeth in Makapansgat mandible

yürek, 1955, p. 35): "1. The maxillary fragment from the Serengeti district of Tanganyika Territory, designated as *Meganthropus africanus* by Weinert and Remane, in the morphology of its teeth comes closer to the australopithecines of South Africa than to the other hominids. But still this form differs from *Australopithecus* and *Paranthropus* in a number of features which, in my opinion, entitle it to a separate generic rank. I propose to rename this form, which belongs to the family Hominidae, as *Praeanthropus africanus*.

2. The isolated third upper molar from the Serengeti district, found 6 or 3 kilometers away from the maxillary fragment, also belongs to Hominidae, but probably to a form more advanced from the morphological standpoint than *Praeanthropus africanus*, *Australopithecus* and *Paranthropus*."

⁸ Oakley, 1954, p. 13 and table 1.

⁹ Dart, 1948, p. 394.

¹⁰ Ibid., p. 392.

¹¹ Robinson, 1954A, p. 196.

ble, as follows: ($M_1 I_1$) $I_2 M_2 P_1 P_2$ ($C_1 M_3$).¹² In the adolescent mandible of Makapansgat, shown in figs. 1-4,¹³ the dental formula, in which the deciduous teeth are indicated by small and the permanent teeth by capital letters, is as follows: $I_1 I_1 c_1 P_1 m_2 M_1 M_2$. In this mandible the four permanent incisors, which had erupted, the deciduous canines and the second left deciduous molar have been lost, either during¹⁴ or after death. Of the temporary dentition only the second right deciduous molar and of the permanent dentition the right and left first premolars (the right one is still only partly out), the right and left first permanent molars and the fully erupted second permanent molars of both sides are retained. From this it is clear that, as is also concluded by Dart¹⁵ and Broom and Robinson,¹⁶ in the adolescent mandible from Makapansgat the first and second premolars erupted after the second permanent molar, P_1 preceding P_2 in eruption. It is also certain that in this adolescent mandible, the permanent canine erupts after the first premolar, as is indicated also in the order of eruption given by Broom and Robinson.¹⁷

In the sequence of eruption of the permanent teeth in the Makapansgat mandible, given by Broom and Robinson,¹⁸ the permanent canine is shown as erupting even later than the second premolar. The position of the right permanent canine in this adolescent mandible is described by Dart as follows: "*The tip of the right canine has been exposed lying 3 mm below the bone orifice of its eruption canal.*"¹⁹ Regarding the left second premolar in this mandible Dart states:

¹² Broom and Robinson, 1952, pp. 88 and 89. In this connection see also Broom and Robinson, 1951, p. 443.

¹³ These photographs are made from the casts. In this connection I wish to extend my thanks to Prof. Dr. Raymond A. Dart of the Witwatersrand University for sending me the casts of the earlier finds of *Australopithecus*.

¹⁴ Regarding the possible cause of the loss of some of these teeth Dart (1948, p. 393) states: "*The result of that decisive blow, as far as this mandible is concerned, was that the 4 permanent incisors (and perhaps the left second deciduous molar) were sprung from their sockets and the bone was shattered.*"

¹⁵ Dart, 1948, p. 394.

¹⁶ Broom and Robinson, 1952, pp. 88-89.

¹⁷ Ibid., pp. 88-89.

¹⁸ Ibid., pp. 88-89.

¹⁹ Dart, 1948, p. 402.

“...while, on the left side, the crown of the second premolar is partially exposed as it lies in its eruption canal.”²⁰ In the cast of the adolescent Makapansgat mandible in my possession the tip of the lingual cusp of the left second premolar is seen to have reached the level of the alveolar margin on the inside, while the disto-lingual corner of the crown is still overhung by bone. On the other hand, the tip of the buccal cusp of this tooth is observed to project slightly above the alveolar margin, on the external side. Thus this tooth, which in life must have been overlain by the second milk molar, cannot be classified as erupting, but it appears to be getting ready to do so. While the tip of the buccal cusp of the left second premolar slightly projects above the alveolar border, in the cast of this mandible the tip of the right permanent canine is seen to be further below this margin. This suggests that in this adolescent mandible the permanent canine would erupt after the second premolar, as is indicated in the sequence of eruption given by Broom and Robinson.²¹ However, as both teeth are still unerupted, this suggested sequence, which appears likely, still needs to be confirmed, which is possible only when more adolescent remains of *Australopithecus* from Makapansgat are discovered.

Regarding the sequence of eruption of M_1-I_1 and C_1-M_3 in this adolescent mandible, Broom and Robinson correctly state: “We have only the one jaw, and no evidence whether I_1 appears before or after M_1 , and no evidence as to whether C or M_3 is the last to appear as both are unerupted.”²² However, while the adolescent mandible from Makapansgat does not give us any information in this regard, fortunately other specimens have been found that throw light on the relative times of eruption of these teeth in genus *Australopithecus*.

In a recent paper Dart has described the mandibular fragment of an adult female from Makapansgat, in which all the permanent teeth of the right side, in addition to some on the left side, are retained.²³

²⁰ Ibid., p. 394.

²¹ Broom and Robinson, 1952, pp. 88-89.

²² Ibid., p. 88.

²³ Dart, 1954, p. 319. In this recent paper Dart (1954, p. 332) states: “Detailed description of the dentition of this specimen, however, is reserved for a later communication, in which it will be possible to discuss individually both the lower and upper teeth of *A. prometheus* in the light of previous discoveries and a series of developing permanent teeth (lateral incisor to second premolar inclusive) recently recovered from an infantile maxilla that had

From the two photographs of this female mandible published by Dart,²⁴ showing the teeth in occlusal view, it is seen that the right permanent canine has suffered more attrition than the right wisdom tooth. This would suggest that the third molar in this mandible has erupted later than the permanent canine.

Evidence for the time of eruption of the lower first permanent molar relative to that of the lower first permanent incisor, is furnished by the Taungs child and the mandible of a child from Sterkfontein. The dental formula of the maxilla and mandible of the Taungs child, whose teeth have been studied by various writers²⁵ is as follows:

$$\frac{i^1 \ i^2 \ c^1 \ m^1 \ m^2 \ M^1}{}$$

$i_1 \ i_2 \ c_1 \ m_1 \ m_2 \ M_1$ The teeth of the child's mandible from Sterkfontein are described by Broom and Robinson as follows: "The child *Plesianthropus* lower jaw, found on 11th March, 1948, gives us examples of all the lower milk teeth. As already mentioned the bone is hopelessly imperfect. Presumably it had been chewed by some carnivore before it was fossilised, so that very little of the bone remains. Fortunately, the two right milk molars with the 1st right permanent molar are in undisturbed position. The right milk canine is badly displaced and the right incisors slightly displaced. The left 1st and 2nd incisors are preserved with the left canine together, and only a little displaced; and the left 1st deciduous molar is also preserved."²⁶

As can be seen from the photograph published by Broom and Robinson,²⁷ in this Sterkfontein mandible the lower first permanent molar had erupted. It is thus clear that in both the Taungs child and in the Sterkfontein child the lower first permanent molar had preceded the lower first permanent incisor in eruption. The evidence of the Taungs skull as well as that of the Sterkfontein mandible, originally described as *Plesianthropus* which is now assigned to *Australopithecus* by Robinson,²⁸ shows that in the later forms of *Australo-*

also been discovered previously." But as still no pictures are published, till Dart's report on the teeth is published, it will not be known what light this infantile maxilla may throw on the sequence of eruption of the anterior permanent maxillary teeth.

²⁴ Dart, 1954, figs. 3-4.

²⁵ Among others see Dart, 1925; Broom, 1934 and 1946; Keith, 1931.

²⁶ Broom and Robinson, 1950, p. 50.

²⁷ Ibid., pl. 4, fig. 18.

²⁸ Robinson, 1954A, pp. 196 and 199.

pithecus the lower first permanent incisor erupted later than the lower first permanent molar, as it does in the great anthropoid apes. According to the dental formulae given by Schultz²⁹ for *Pongo*, *Pan* and *Gorilla* and Clements and Zuckerman³⁰ for *Pan* and *Gorilla*, the lower first permanent molars in these great anthropoid apes always precede the lower first permanent incisors in eruption. According to the dental formulae given by Schultz, this is also true for the vast majority of Gibbons.³¹

The reverse condition, where the lower first permanent incisor erupts before the lower first permanent molar is found in one specimen of *Paranthropus* from Swartkrans, described by Broom and Robinson³² and in some of the recent Whites, while in the other modern Whites the first lower permanent molar erupts before the first lower permanent incisor.³³ The appearance of the lower first permanent molar before the lower first permanent incisor, which is clearly the primitive condition, in Taungs and Sterkfontein specimens suggests that in the earlier Makapansgat form, also, the lower first permanent molar might have erupted before the lower first permanent incisor.

The evidence in hand indicates that the sequence of eruption of the permanent lower teeth in genus *Australopithecus* was as follows: $M_1 I_1 I_2 M_2 P_1 P_2 C_1 M_3$. The sequences of eruption of the permanent teeth in the living great anthropoid apes and recent man are shown below.³⁴

²⁹ See Schultz, 1935, tables 17, 18 and 19; Schultz, 1940, table 22; Schultz, 1941, table 18; Schultz, 1950A, table 10.

³⁰ Clements and Zuckerman, 1953, tables 1-2 and pp. 324 and 331.

³¹ See Schultz, 1944, table 17. According to this table of Schultz (1944, table 17), out of 118 gibbons studied by him in only one clear case the lower first permanent incisor erupts before the lower first permanent molar.

³² Broom and Robinson, 1952, p. 88.

³³ For the time of eruption of the lower first permanent molar relative to that of the lower first permanent incisor in modern whites see: Schultz, 1950B, fig. 7; Clements, Davies-Thomas and Pickett, 1953A, tables 1, 2 and 6; Clements, Davies-Thomas and Pickett, 1953B, table 2; Clements and Zuckerman, 1953, pp. 322 and 330.

³⁴ The lines denote that the order of eruption of the teeth indicated is variable. According to more recent findings of Schultz, in *Pongo* M_2 may sometimes precede I^2 and in some male individuals C^1 may appear after M_3 but before M^3 (see Schultz, 1941, p. 83).

Pongo: (Schultz, 1935)	$\frac{M^1 \ I^1 \ I^2 \ M^2 \ \overline{P^1} \ \overline{P^2} \ C^1 \ M^3}{M_1 \ I_1 \ I_2 \ M_2 \ P_2 \ P_1 \ C_1 \ M_3}$
Pan: (Clements and Zuckerman, 1953)	$\frac{M^1 \ \overline{I^1} \ \overline{I^2} \ M^2 \ \overline{P^2} \ \overline{P^1} \ \overline{C^1} \ M^3}{M_1 \ I_1 \ I_2 \ M_2 \ P_1 \ P_2 \ C_1 \ M_3}$
Gorilla: (Clements and Zuckerman, 1953)	$\frac{M^1 \ \overline{I^1} \ \overline{I^2} \ M^2 \ \overline{P^2} \ \overline{P^1} \ \overline{C^1} \ M^3}{M_1 \ I_1 \ I_2 \ M_2 \ P_2 \ P_1 \ C_1 \ M_3}$
Recent Man: (Schultz, 1935)	$\frac{\overline{M^1} \ I^1 \ I^2 \ \overline{P^1} \ \overline{P^2} \ \overline{C^1} \ M^2 \ M^3}{M_1 \ I_1 \ I_2 \ C_1 \ P_1 \ P_2 \ M_2 \ M_3}$
Recent Britishers (Male): (Clements and Zuckerman, 1953)	$\frac{\overline{M^1} \ I^1 \ I^2 \ \overline{P^1} \ \overline{C^1} \ \overline{P^2} \ M^2}{I_1 \ M_1 \ I_2 \ C_1 \ P_1 \ M_2 \ P_2} \ M_3$
Recent Britishers (Female): (Clements and Zuckerman, 1953)	$\frac{\overline{M^1} \ I^1 \ I^2 \ P^1 \ \overline{C^1} \ \overline{P^2} \ \overline{M^2}}{I_1 \ M_1 \ I_2 \ C_1 \ P_1 \ M_2 \ P_2} \ M_3$

The available evidence thus indicates that the sequence of eruption of the permanent teeth in genus *Australopithecus*, was quite different from that of recent Europeans and came close to that of the anthropoids, as has also been noted by Broom and Robinson.³⁵

Paranthropus: Among the remains from Swartkrans, originally described as *Paranthropus crassidens* by Broom and Robinson,³⁶ but now considered to be a subspecies of *Paranthropus robustus* (*Paranthropus robustus crassidens*) by Robinson,³⁷ there are several immature specimens which have been briefly described by Broom and Robinson.³⁸ Regarding the sequence of eruption of the permanent teeth in the Swartkrans form of *Paranthropus*, Broom and Robinson, in their more recent study, state: "From all these facts we can give the sequence of the permanent dentition in *Paranthropus crassidens* with full confidence; and it is ($I_1 \ M_1$) I_2 ($C \ P_1$) $M_2 \ P_2 \ M_3$. The only variation that seems possible is between I_1 and M_1 , C and P_1 and M_2 and P_2 , but the

³⁵ Broom and Robinson, 1952, p. 88.

³⁶ Ibid.

³⁷ Robinson, 1954A, pp. 196 and 198.

³⁸ Broom and Robinson, 1952, pp. 28-29 and 88-89.

order given is that for which we have definite evidence.”³⁹ Commenting upon the last sentence in the above quotation, Clements and Zuckerman state: “Presumably this means that the possible sequence is $M_1, I_1, I_2, P_1, C, P_2, M_2, M_3$.”⁴⁰ The sequence of eruption of the permanent teeth in the Swartkrans form has been critically reviewed by Clements and Zuckerman,⁴¹ and is further considered below, where each specimen is given a number.

1. *Maxilla* (Child’s skull). Broom and Robinson state: “The teeth showing are the first molar which has just come into use. In front of it is the deciduous second premolar slightly worn. In front of this is the broken deciduous first premolar about to be shed, and with the crown of the first permanent premolar nearly ready to function. The deciduous canine has probably still been functioning, but is lost and a fracture shows the crown of the permanent canine well developed, but still at a fairly high level in the bone. It is pretty manifestly a male. The second permanent incisor is fully erupted and the crown perfect. The first incisor is also fully erupted, but has been damaged on both sides.”⁴² From the illustrations given by Broom and Robinson,⁴³ it is difficult to assess the state of eruption of the still unerupted teeth, but the description given by them⁴⁴ suggests that in this skull, although still unerupted, P^1 might perhaps have appeared before the permanent canine and the permanent second molar.

2. *Maxilla*. Broom and Robinson state: “Then we have a child upper jaw, which shows that the C about to erupt about the same time as P_1 , but probably a little earlier, and certainly long before P_2 or M_2 .”⁴⁵ As this maxilla has not been figured by Broom and Robinson,⁴⁶ it is not possible to assess the state of eruption of the teeth referred to. Clements and Zuckerman omit this specimen from consideration by

³⁹ Ibid., p. 89.

⁴⁰ Clements and Zuckerman, 1953, p. 325.

⁴¹ Ibid., pp. 325-330.

⁴² Broom and Robinson, 1952, p. 28.

⁴³ Ibid., figs. 27-28 and pl. 5, fig. 18.

⁴⁴ Ibid., p. 28. It may be mentioned here that in fig. 28 published by Broom and Robinson (1952), the tip of the buccal cusp of the left upper first premolar is indicated as slightly projecting below the alveolar margin. However, this observation made on the drawing, could not be made out in the photograph published by these authors (Broom and Robinson, 1952, pl. 5, fig. 18).

⁴⁵ Broom and Robinson, 1952, p. 88.

⁴⁶ Ibid.

stating: "*This specimen has been omitted, since the experience has led us to be cautious about inferences regarding the probable time of appearance of teeth which have not yet erupted. Reliable conclusions about orders of eruption can be based only on the continuous study of the same individual, or on comparisons of the actual dental patterns in different specimens.*"⁴⁷

3. *Maxilla* (Child's skull). Broom and Robinson state: "*The beautiful palate has on the right side the first and second permanent molars, the crown of the second permanent premolar has probably cut the gum, but is not yet functioning. There are also preserved the sockets of the permanent first premolar, and of the permanent canine and first and second incisors. On the left side there are preserved the second molar and part of the first molar.*"⁴⁸ From the photograph published by Broom and Robinson,⁴⁹ showing the teeth in occlusal view, the right upper second premolar appears to have projected only very little below the alveolar margin. From the description quoted above and the photograph, it is clear that in this skull the second upper premolar would erupt later than the second upper molar, the first upper premolar and the permanent upper canine. However, as the second molar, the first premolar and the permanent canine had already erupted, this skull does not give us any information as to whether P¹ and C¹ erupted before or after M², and what the order of eruption of P¹ relative to C¹ was.

4. *Maxilla*. Broom and Robinson state: "*We have a beautiful palate with all the permanent teeth functioning except P₂. (The third molar is not preserved in the specimen but almost certainly would be unerupted). The deciduous P₂ is still being used. The C and P₁ are both a little worn, but it is impossible to decide which had erupted first — possibly the C. The second molar is functioning but, as it is practically unworn, it has probably been but recently erupted.*"⁵⁰ The only thing this description clearly shows is that in this individual the second upper premolar erupts later than the upper second permanent molar, the first upper premolar and the upper permanent canine.⁵¹ The description of the state of attrition on M², P¹ and C¹ suggests that the upper second permanent

⁴⁷ Clements and Zuckerman, 1953, p. 325.

⁴⁸ Broom and Robinson, 1952, pp. 28-29.

⁴⁹ *Ibid.*, pl. 5, fig. 19.

⁵⁰ *Ibid.*, p. 89.

⁵¹ See also Clements and Zuckerman, 1953, p. 329.

molar might have erupted later than the first upper premolar and the upper permanent canine.

5. *Jaw*. Broom and Robinson state: "And we have a child jaw where M_1 and I_1 are both unerupted but where it seems probable that M_1 will erupt first."⁵² This specimen, described only as a jaw and not illustrated by Broom and Robinson,⁵³ is considered to be a lower jaw by Clements and Zuckerman.⁵⁴

6. *Mandible*. Broom and Robinson state: "We have a child mandible which shows the I_1 erupting while M_1 is still unerupted."⁵⁵ The photograph of this mandible published by Broom and Robinson⁵⁶ clearly shows that the central incisor in this mandible erupts before the first permanent molar, which represents an advanced condition.

7. *Mandible*. Broom and Robinson state: "We also have a mandible which shows that M_2 functions before P_2 ."⁵⁷ This statement shows only that the second premolar erupts later than the second permanent molar, as is also the case in the upper jaw.

From the account given above it is clear that the only thing that can be stated to be certain about the sequence of eruption in the upper jaw of Swartkrans form is that, as shown by specimens 3 and 4, the second upper premolar erupts later than the upper second permanent molar, the upper first premolar and the permanent upper canine. The state of attrition of the teeth in specimen 4 also suggests that the first upper premolar and the permanent upper canine might have erupted before the upper second permanent molar. In the lower jaws, it is clear that, as shown by specimen 6, the lower central permanent incisor appears before the lower first permanent molar and that, as indicated by specimen 7, the second lower premolar erupts later than the lower second permanent molar.

In connection with the order of eruption of the permanent teeth in the Swartkrans form, Broom and Robinson, as quoted before, stated: "The only variation that seems possible is between I_1 and M_1 , C

⁵² Broom and Robinson, 1952, p. 88.

⁵³ Ibid.

⁵⁴ Clements and Zuckerman, 1953, p. 325.

⁵⁵ Broom and Robinson, 1952, p. 88.

⁵⁶ Ibid., pl. 1, fig. 5.

⁵⁷ Ibid., p. 89.

and P_1 and M_2 and P_2 , but the order given is that for which we have definite evidence.”⁵⁸ Taking this in reverse order, it can be stated that, as far as the published material is concerned, there appears to be no indication that the second premolar, in both the upper and lower jaws, ever erupted before the second permanent molar. As for the order of eruption of the first premolar and permanent canine, Broom and Robinson’s statement probably refers mainly to the upper jaw, as they make no statement regarding the state of eruption of the canine and first premolar in any one of the mandibles.

As has been quoted before, Broom and Robinson are inclined to believe that in specimens 2 and 4 the upper canine may appear before the first upper premolar. On the contrary, the described position of these two teeth in specimen 1 suggests, but still does not prove, that the first upper premolar may erupt before the upper permanent canine. It is thus possible that the order of eruption of these two teeth may have been variable.⁵⁹ But it is evident that for the determination of the true order of eruption of P^1 and C^1 , more material is needed. As for the times of eruption of the first permanent molar and the central permanent incisor, there is no evidence in the published upper jaws to show in what order these two teeth erupted. In the mandible, specimen 6 clearly shows that the lower central permanent incisor precedes the lower first permanent molar in eruption. If specimen 5 is a mandible, as seems to be the case, its description would suggest, but not prove, that the order of eruption of these two mandibular teeth may have been variable. But still this remains to be demonstrated.

According to our present knowledge, the order of eruption of the permanent teeth in upper and lower jaws of Swartkrans form may be expressed as follows:⁶⁰

⁵⁸ Ibid., p. 89.

⁵⁹ It is of interest to note that in their earlier study Broom and Robinson (1951, p. 443) stated: “. . . the canine appears about the same time as the 1st premolar.”

⁶⁰ This formula is not intended to indicate whether an upper or lower tooth, as for example P^2 and P_2 , erupts before the other, as to do it we need upper and lower jaws belonging to the same individuals. The order of eruption of M^1 , I^1 and I^2 in the upper jaw and that of I_2 in the mandible, have been assumed as the more likely ones from our knowledge of the order of eruption of these teeth in recent man and the majority of the anthropoids. The position of M^3 is based

$M^1 I^1 I^2$	$(\overline{P^1 C^1} \text{ or } \overline{C^1 P^1})$	$M^2 P^2 M^3$
$I_1 M_1 I_2$		$M_2 P_2 M_3$ (Place of C_1 and P_1 in sequence of eruption not known).

A comparison of this sequence with those of the living anthropoids⁶¹ shows that the sequence of eruption of the permanent teeth in the Swartkrans form, as far as it is known, deviated conspicuously from that of the anthropoid apes, as has been duly noted by Broom and Robinson,⁶² Le Gros Clark⁶³ and Clements and Zuckerman⁶⁴ and came close to that of recent man, as already stated by Broom and Robinson⁶⁵ and Clements and Zuckerman.⁶⁶ As far as the present information is concerned, the only certain feature that seems to be retained from the original anthropoid condition in Swartkrans form is the later eruption, in both jaws, of P_2 than M_2 .

In comparing the sequences of eruption in *Australopithecus* and *Paranthropus*, Broom and Robinson state: "The order is seen to differ very considerably from that in Dart's ape-man which, as we have shown, agrees with the apes and Sinanthropus. . . ."⁶⁷ This is certainly valid for the order of eruption of the lower M_1 and I_1 and also may very well turn out to be true for the order of eruption in the upper jaw when more adolescent maxillae of *Australopithecus* are discovered. However, as at the moment our information on the order of eruption of the upper permanent teeth in *Australopithecus* is restricted to the observation that, as shown by the Taungs child, M^1 appears before I^1 , and as in *Homo sapiens* examples are encountered in which the order of eruption of premolars relative to M_2 may vary in upper and

upon Broom and Robinson's statement regarding specimen 4. The place of M_3 has been supposed to be likely from the restored drawings of the type specimen, published by Broom and Robinson (1952, figs. 1-3) which show the lower canine, which is missing in the find, in its place, in addition to the fully erupted and preserved P_1 , P_2 , M_1 and M_2 , while M_3 is still in its alveolus.

⁶¹ See p. 414

⁶² Broom and Robinson, 1951, p. 443 and 1952, p. 89.

⁶³ Le Gros Clark, 1952, p. 49.

⁶⁴ Clements and Zuckerman, 1953, p. 329.

⁶⁵ Broom and Robinson, 1951, p. 443.

⁶⁶ Clements and Zuckerman, 1953, pp. 329-330.

⁶⁷ Broom and Robinson, 1952, p. 89.

lower jaws,⁶⁸ a strict comparison of the sequences of eruption of upper permanent teeth in *Australopithecus* and *Paranthropus* is not yet possible and the comparison must by necessity be confined to the mandibles. There is no difference in the place occupied by P_2 in the order of eruption of the lower permanent teeth in *Australopithecus* and *Paranthropus*, as in both genera it erupts later than M_2 . As the places of C_1 and P_1 in the order of eruption of the lower permanent teeth of Swartkrans form are not known, it is not possible to make a comparison between the two genera in regard to these teeth. On the other hand, in having I_1 erupt before M_1 , which is an advanced condition, Swartkrans ape-man, at least one individual of this form, conspicuously deviates from the older *Australopithecus* which still retains the primitive anthropoid condition.⁶⁹ Although it is possible that some individuals of Swartkrans form may have also retained this primitive relation, this still remains to be demonstrated. It appears that starting from a common ancestral stock, that gave rise both to *Australopithecus* and *Paranthropus* and which may date back into the Pliocene period, *Australopithecus* has retained the primitive anthropoid condition in this regard, while during the course of its evolution *Paranthropus* has acquired a tendency to have I_1 erupt before M_1 .

In an earlier study on "The Dentition of Plesianthropus and Paranthropus", I had stated: "*However, Plesianthropus, Paranthropus and probably Australopithecus are too late geologically to be direct ancestors of the Pleistocene hominids. They are somewhat modified survivors from the Pliocene period. We should regard them only as our structural ances-*

⁶⁸ This is clearly shown by the difference in position of upper and lower canines and the upper and lower second premolars in the sequence of eruption of the permanent teeth of modern Britishers given by Clements and Zuckerman (see p. 6). It is further shown by the sequence of eruption of upper and lower premolars relative to the second permanent molars, in a Chalcolithic child from Anatolia (Troy: No. 1 Tr.). In the upper jaw of this child of Chalcolithic Age, first premolar erupts before and the second premolar after the second molar, while in the lower jaw the second molar precedes both the first and second premolars in eruption.

⁶⁹ According to Oakley, Swartkrans breccia may be later than the Taungs and Sterkfontein deposits (see Oakley, 1954, table 1). In discussing the relative ages of australopithecine bearing beds, Robinson (1954B, p. 332) states: "*The relationship of Sterkfontein (Australopithecus) and Swartkrans (Paranthropus) is more certain, the former being a little older than the latter.*"

tors, that is, as representing forms that resemble our earlier and direct ancestors. They are the conservative cousins of the Pleistocene hominids. I believe that they are survivors from the Middle Pliocene period.”⁷⁰ In the same study, regarding the upper lateral incisor of female *Plesianthropus* (*Australopithecus*), I had remarked: “The size of the upper lateral incisor of the female *Plesianthropus* is smaller than that of the anthropoids and *Sinanthropus*. In the degree of reduction of this tooth *Plesianthropus* had overshot the stage represented by *Sinanthropus* and had paralleled the later stages of human evolution.”⁷¹ It is also of interest to note that in accelerating the eruption of the upper permanent canine Swartkrans form had overshot some of the fossil *Homo sapiens* and had paralleled recent man, as in the ancient Afalou peoples of North Africa, described by Boule, Vallois and Verneau, the upper permanent canine erupted rather late as will be discussed below.⁷² It is also probable that the tendency acquired by Swartkrans ape-man to have I_1 erupt before M_1 is another incidence of parallelism with recent Europeans.

⁷⁰ Şenyürek, 1941, p. 301.

⁷¹ *Ibid.*, p. 293. In the same study I had also stated (Şenyürek, 1941, pp. 293-294): “As I pointed out before (1940), in the degree of reduction of the upper canine the female *Plesianthropus* was more advanced than the female *Sinanthropus*. That is, it had paralleled the later stages of human evolution in this respect. However, this is probably not true for the male *Plesianthropus*, as it is inferred from the size of the lower canine. The size of the upper canine of male *Plesianthropus* was probably of about the same size as that of *Sinanthropus*, if not somewhat bigger.” In this connection it is of interest to note that the upper canine of male *Plesianthropus* (*Australopithecus*) described by Broom and Robinson in 1950 has a robustness value of 132.98 (according to Broom and Robinson, 1950, the mesio-distal diameter is 10.9 and the bucco-lingual diameter 12.2 mm.) which is higher than the maximum of males of Peking Man (as calculated from Weidenreich’s, 1937, measurements the maximum robustness value in the upper canine of Peking man is 109.2) and indeed is even bigger than that of *Pithecanthropus modjokertensis* (*Pithecanthropus robustus* Weidenreich), in which the average robustness value of the right and left upper canines is, as calculated from the measurements given by Weidenreich (1945A, table 5), 112.1. Thus the upper canine of male *Plesianthropus* (*Australopithecus*) has come true to expectation.

⁷² See Boule, Vallois and Verneau, in Arambourg, Boule, Vallois and Verneau, 1934, pp. 145-146.

ERUPTION OF THE PERMANENT TEETH IN
SINANTHROPUS PEKINENSIS BLACK⁷³

According to Weidenreich the permanent mandibular teeth of Peking Man erupted in the following order: $M_1 I_1 I_2 M_2 P_1 C_1 P_2 M_3$.⁷⁴ This sequence of eruption given by Weidenreich was based on mandibles BI and BV.⁷⁵ The state of eruption of the permanent teeth in mandible BI, originally studied and illustrated by Black,⁷⁶ is described by Weidenreich as follows: "... the *permanent incisors are already in place and the same is true of the first permanent molar, while the deciduous canine and the two molars still persist. However, M_2 is already preparing to erupt, its chewing surface being exposed immediately below the surface of the alveolar process. A skiagram of the mandible (Plate VI, fig. 1 in the above quoted publication) demonstrates besides that picture that M_2 really is situated in the level below the surface, whereas the germs of P_1 and P_2 are still embedded rather deeply within the body of the jaw.*"⁷⁷ This suggests that in this mandible, as has already been inferred by Weidenreich,⁷⁸ the second permanent molar precedes the premolars and the permanent canine in eruption. However, as M_2 is unerupted,⁷⁹ this inferred sequence still needs to be further confirmed, which is possible only when additional remains of Peking Man are discovered.

On the stage of eruption of the permanent teeth in mandible BV, Weidenreich states: "*In regard to the teeth, the four permanent incisors are preserved but slightly worn. One half of the right canine is erupted while the left one is cutting the gum. Since the outer wall is broken off in this specimen, the tooth may be seen in its natural position in the bone. The right first premolar has just erupted. In place of the second premolar there is the second milk molar which is rather strongly worn; below this the second per-*

⁷³ It should be mentioned here that Peking Man is now designated *Pithecanthropus pekinensis* by Le Gros Clark (1949, p. 80) and *Pithecanthropus erectus pekinensis* by Hooijer (1951, p. 277).

⁷⁴ Weidenreich, 1937, p. 122.

⁷⁵ See *ibid.*, p. 122.

⁷⁶ Black, 1934, pp. 74-75 and fig. 8.

⁷⁷ Weidenreich, 1937, p. 122.

⁷⁸ *Ibid.*, p. 122.

⁷⁹ For the state of eruption of M_2 see Weidenreich, 1936, pl. II, fig. 3, and pl. VI, fig. 1.

manent premolar was exposed."⁸⁰ The pictures published by Weidenreich,⁸¹ clearly show that in this mandible the permanent canine erupts after the first premolar but before the second premolar, as has been indicated by Weidenreich in his order of eruption. As this mandible is unfortunately broken behind the right second milk molar, it is not possible to determine whether M_2 had erupted.

In addition to the above, there is another mandible (B IV) of Peking Man described by Weidenreich in 1936. Regarding the teeth of mandible B IV, Weidenreich states: "*It comprises the right side of the body beginning with the middle line and ending behind the first permanent molar. All teeth, with the exception of the latter, are preserved, representing together the entire set of the deciduous teeth of this side. The first permanent molar was just in the stage of erupting but is completely broken off; a few splinters can be observed to adhere to the upper surface.*"⁸² This description and the skiagram published by Weidenreich⁸³ indicate that in this mandible the first permanent molar preceded the central permanent incisor in eruption.⁸¹

According to the present indications, the sequence of eruption of the lower permanent teeth of Peking Man appears to be that given by Weidenreich.⁸⁵ This sequence differs from the order of eruption of the lower permanent teeth of the anthropoids and *Australopithecus*, only in the position of the permanent canine, the eruption of which has been slightly accelerated, having come to erupt before the second premolar, instead of after it. On the other hand, this sequence still differs conspicuously from the norm for the lower teeth of recent whites, that is it is much more primitive.

⁸⁰ Weidenreich, 1936, p. 15.

⁸¹ *Ibid.*, pl. IX, figs. 1-8.

¹² *Ibid.*, p. 15.

⁸³ *Ibid.*, pl. VIII, fig. 5.

⁸⁴ In his study of 1937, Weidenreich attributed two isolated immature second molars (one upper and one lower) to individual B IV (Weidenreich, 1937, p. 8). As can be seen from the pictures published by Weidenreich (1937, pl. XIV, fig. 113, pl. XXIX, fig. 275, pl. XIX, fig. 165 and pl. XXX, fig. 290) in both of these immature teeth the crowns are fully formed. If Weidenreich's attribution of these isolated teeth to individual B IV is correct, it would further confirm that in this mandible M_1 erupted before I_1 , which is the primitive condition.

⁸⁵ See p. 422 and Weidenreich, 1937, p. 122.

ERUPTION OF THE PERMANENT TEETH IN GENUS HOMO

Homo neanderthalensis: According to Virchow, the permanent teeth in the mandible of Ehringsdorf child appeared in the following order: M_1 I_1 I_2 C_1 M_2 P_1 P_2 M_3 .⁸⁶ Weidenreich also, following Virchow, gives the above order for the Ehringsdorf child.⁸⁷ As can be seen from the pictures published by Virchow,⁸⁸ in this juvenile mandible M_2 had completed its eruption, the right first premolar had about half erupted and the left second premolar, lagging behind P_1 , had just begun to erupt, which clearly show that, as has been concluded by Virchow,⁸⁹ the latter two successional teeth succeeded the second permanent molar in eruption, as we have already seen to be the case in the anthropoids, *Australopithecus* and Peking Man.

Regarding the state of eruption of the right permanent canine in the Ehringsdorf mandible Weidenreich made the following observation: "*The Ehringsdorf canine (fig. 57) is just in the stage of eruption with the base of the lingual part still embedded within the border of the alveolar process.*"⁹⁰ But in spite of this, on a later page in the same study Weidenreich stated: "*On the other hand C in the Ehringsdorf child erupts immediately after the incisors and before M_2 *"⁹¹ The appearance of the right permanent canine in fig. 3, Pl. III, published by Virchow,⁹² showing the teeth in occlusal view, seems to support this observation made by Weidenreich. This would suggest that in this juvenile mandible, which according to Zeuner dates from "*the latter half of last interglacial*",⁹³ viz., Riss - Würm interglacial, the second permanent molar might have preceded the permanent canine in eruption.

⁸⁶ Virchow, 1920, fig. 39; Weidenreich, 1937, p. 122.

⁸⁷ Weidenreich, 1937, p. 122.

⁸⁸ See Virchow, 1920, pl. IV. figs. 2-3, pl. VI, fig. 5 and pl. VII, figs. 6-7.

⁸⁹ Ibid., p. 102.

⁹⁰ Weidenreich, 1937, p. 33.

⁹¹ Ibid., p. 122.

⁹² Virchow, 1920.

⁹³ Zeuner, 1940, p. 5.

Spiegel, cited by Schultz,⁹⁴ and Weidenreich⁹⁵ have noted that in Krapina mandible C, the second premolar had appeared before the second milk molar was shed.⁹⁶ Among the Krapina material described by Gorjanović-Kramberger,⁹⁷ there are a few other specimens which also yield information on the order of eruption of at least some permanent teeth.

Krapina Maxilla B: Regarding this maxilla Gorjanović-Kramberger states: "*Dieser ziemlich gut erhaltene Oberkiefer wurde vollständig angetroffen. Da er jedoch gerade an der Humusgrenze lag und dadurch Konstant den Einflüssen der Feuchtigkeit ausgesetzt war, wurde er auch dermassen durchweicht angefundnen, dass man nur mit grösster Mühe den grösseren Teil davon retten konnte. Sämtliche Schneidezähne lösten sich vom Kiefer ab, da dieser eben vorn zerbröckelte. Ebenso lösten sich auch alle vorn zum Durchbruche bereit gestandenen Zähne (beide oJ_1 , roJ_2 und der $lo C$) ab. Unser Kiefer stellt uns also einen im Zahnwechsel begriffenen Kiefer eines etwa 9jährigen Kindes dar. Am Kiefer selbst sind noch fälgende Zähne sichtbar: der $l. J_2$, die beiden C , die beiderseitigen P_1 und P_2 des Milchgebisses, ferner die beiderseitigen M_1 des definitiven Gebisses, während der lM_2 und der $l. J_2$ im Kiefer noch stecken.*"⁹⁸ This description and the picture published by Gorjanović-Kramberger⁹⁹ show that in this maxilla the first permanent molar erupted before the central permanent incisor.

Krapina Maxilla C: On the state of eruption of the permanent teeth in this maxilla, Gorjanović-Kramberger stated: "*Dieser Oberkiefer*

⁹⁴ Schultz, 1935, p. 542. Spiegel's paper (1934) has unfortunately been inaccessible to me. Regarding Spiegel's observation, Schultz (1935, p. 542) states: "*Spiegel ('34) has recently called attention to the fact that the picture by Gorjanović - Kramberger ('06) of the fossil human mandible 'C' from Krapina shows an erupted M_2 alongside an m_2 (and not a P_2).*"

⁹⁵ Weidenreich, 1937, p. 122.

⁹⁶ Regarding Krapina man, Boule, Vallois and Verneau (in Arambourg, Boule, Vallois and Verneau, 1934, p. 145) state: "*Sur un jeune Néanderthalien de Krapina, âgé de treize ans, la deuxième prémolaire est encore incluse, alors que la deuxième arrière-molaire est déjà en place.*" This statement also very probably refers to mandible C.

⁹⁷ Gorjanović-Kramberger, 1906 and 1907.

⁹⁸ Gorjanović-Kramberger, 1906, p. 137. However, it must be mentioned here that in the explanation of the picture of this jaw, Gorjanović-Kramberger (1906, pl. IV, fig. 3) gives the age as 7, which is more correct.

⁹⁹ Gorjanović-Kramberger, 1906, pl. IV, fig. 3.

ist zwar nicht vollständig aber sonst schön erhalten. Er zeigt uns die linke Zahnreihe, bestehend aus den beiden grossen Alveolen der I_1 , des C und des P_1 (dM_1), ferner den P_2 (dM_2), M_1 und den noch nicht ganz in die Reihe gelangten M_2 . Auf der nur teilweise erhaltenen rechten Kieferhälfte sehen wir die grossen Alveolen des I_1 , C und des P_1 , ferner den I_2 und den beinahe hervorgebrochenen P_2 . - Dieser Oberkiefer musste einem etwa 13jährigen Menschen angehört haben."¹⁰⁰ This and the photographs published by Gorjanović-Kramberger,¹⁰¹ clearly show that in this maxilla both the second permanent molar and the permanent canine precede the two premolars in eruption. However, as the canines are not preserved, it is not possible to determine exactly, at least from the photographs, which one of M^2 and C^1 preceded the other in eruption.

Krapina Mandible B: In describing this mandibular fragment, Gorjanović-Kramberger noted: "... der P_1 näher an den Kiefferrand heraufgerückt ist, als auch der P_2 , weil eben auch jener vor diesem letzteren zum Durchbruche gelangt wäre."¹⁰² This suggests that in this mandible P_1 might erupt before P_2 , as it did in Peking Man and Ehringsdorf child.

Krapina Mandible C: On this mandible Gorjanović-Kramberger stated: "Von diesem Kiefer liegt der rechte Körperteil samt dem Aste (welchem nur der Processus condyloideus abgebrochen ist) bis zum Eckzahn der linken Kieferhälfte vor.—Von Zähnen sind der linke definitive I_2 , der dP_2 und die definitiven M_1 und M_2 vorhanden. Der bleibende P_2 steckt noch unter der Wurzel des schon stark abgekauten Backenzahnes, der im Begriffe stand aus dem Kiefer zu fallen. Das Alter des Individuums, dem dieser Kiefer angehört hat, kann mit 13 Jahren festgestellt werden."¹⁰³ This and the skiagram of this mandible¹⁰⁴ show that, as has already been noted by the authors mentioned before, in this mandible M_2 preceded P_2 in eruption. The left permanent canine also appears to have erupted before P_2 . On the other hand, as nothing is said about the first milk molar, it is not known whether the first premolar had erupted or not.

¹⁰⁰ Ibid., p. 139.

¹⁰¹ Ibid., pl. IV, figs. 2, 2a and 2b.

¹⁰² Ibid., p. 144.

¹⁰³ Ibid., p. 145.

¹⁰⁴ See Gorjanović-Kramberger, 1907, fig. 5. For the pictures of this mandible see also, Gorjanovic-Kramberger, 1906, fig. 25 and pl. VI, figs. 3 and 3a.

Krapina Mandible E: The description and photographs given by Gorjanović-Kramberger¹⁰⁵ clearly show that in this subadult mandible, as is expected, M_3 is the last tooth to erupt.

According to the available data, the order of eruption of the permanent teeth in Krapina Neanderthals, which according to Zeuner date from the Riss-Würm interglacial,¹⁰⁶ appear to have been as follows:¹⁰⁷

M^1 I^1 I^2 (M^2 C^1) (P P) M^3
 (M_1 I_1) I_2 M_2 P_2 M_3 (Exact place of C_1 and P_1
 not known, although the former appears to precede P_2).

In the Le Moustier adolescent, the exact geological age of which is not known but according to Zeuner¹⁰⁸ may belong to Würm I, as is clearly seen in the cast in my possession, all the permanent teeth, except upper and lower wisdom teeth which are in process of eruption and the still unerupted left lower permanent canine, had erupted and had been in use. As has been duly noted by various writers,¹⁰⁹ in this youth the left lower milk canine was still functioning, the permanent canine below being described as "impacted" by Gregory.¹¹⁰

La Quina child, which according to Zeuner¹¹¹ dates from Würm I sheds light only on the order of eruption of upper M^1 and I^1 . The description and the figures given by Martin clearly show that in this individual M^1 had erupted before I^1 , which has not yet completed its eruption.¹¹²

¹⁰⁵ Ibid., p. 149 and pl. VII, figs. 2 and 2a.

¹⁰⁶ Zeuner, 1940, p. 6 and table 1. Regarding the age of Krapina Neanderthals, Zeuner (1940, p. 6) states: "The deposit, including the human remains, thus appears to belong to the last interglacial and to be almost contemporary with Taubach and Ehringsdorf."

¹⁰⁷ Letters in parentheses indicate teeth of which the order of eruption relative to each other, for example that of M^2 to C^1 , is not known.

¹⁰⁸ Zeuner, 1940, p. 14.

¹⁰⁹ Gregory, 1921, pp. 142 and 147-148; Boule, Vallois and Verneau (*in* Arambourg, Boule, Vallois and Verneau, 1934, p. 145); Weidenreich, 1937, p. 122.

¹¹⁰ Gregory, 1921, pp. 142 and 148.

¹¹¹ Zeuner, 1940, p. 9 and table 1.

¹¹² Martin, 1926, pp. 120-121 and figs. 34-35. See also Weidenreich, 1945B, p. 154.

In 1940 I had described the fossil remains of two individuals, found by Prof. Coon at Mugharet El 'Aliya in Tangier, and attributed them to *Homo neanderthalensis*.¹¹³ The first individual is represented by a fragment of a maxilla belonging to a child of about 9 years of age in which the permanent canine, the two premolars and the second permanent molar had not yet erupted, while the second individual is represented by an isolated worn upper second permanent molar which belongs to an adult.¹¹⁴ In a recent study on the prehistoric populations of Northwest Africa, Briggs has restudied the Tangier specimens and has postulated the sequence of eruption of the permanent teeth in the maxilla of the child.¹¹⁵ In this study Briggs states: "*In the Tangier maxilla, the permanent upper left canine and premolars are all present though unerupted, as we have seen, and the distal surface of the socket of the unerupted permanent second molar is preserved. The positions of these teeth in the bone of the alveolar process rather suggest that the permanent second molar might well have been destined to erupt later than the premolars but earlier than the canine, the apparent order being, PM₁, PM₂, M₂, C. If this was so, then the Tangier child was intermediate in the order of tooth eruption between modern man and more primitive forms such as Sinanthropus (Weidenreich, '37), Neanderthal Man (Gorjanovič-Kramberger, '06; Virchow, '20), the Afalou series (Boule and Vallois, '34) and even Bushmen (Drennan, '32). But we must remember that the true order of eruption in this case is not certain, and may, in any event, be no more than a matter of individual eccentricity.*"¹¹⁶

The skiagram of this maxilla published in my earlier study,¹¹⁷ clearly shows that the position of the permanent canine is far above those of the two premolars, P² being located slightly higher than P¹. This suggests, as has been postulated by Briggs that, in this

¹¹³ Şenyürek, 1940A and 1940B. For opinions on the age of Tangier remains see Howe and Movius, 1947, pp. 10 and 27; Vaufrey, 1950, p. 505.

¹¹⁴ Şenyürek, 1940A, pp. 2-3.

¹¹⁵ Briggs, 1955, pp. 18-19.

¹¹⁶ *Ibid.*, p. 19. It may be mentioned in this connection that, as was described and illustrated in my earlier study (Şenyürek, 1940A, p. 2 and fig. 2a), in this maxilla only the anterior or mesial part of the alveolus of M² is preserved and not its distal part.

¹¹⁷ Weidenreich, 1945B, p. 158. Debetz's (1940) original study on the Teshik-Tash skull has unfortunately been inaccessible to me.

maxilla C¹ would perhaps erupt later than the two premolars. But as none of these teeth are erupted or ready to do so, the tip of the lingual cusp of P¹ still standing about 2 mm. above the alveolar margin, it is evident that this suggested sequence still remains to be proven, which is possible only when more remains of this form are found.

As for the relation of the time of eruption of upper premolars and upper canine to the upper second molar it is not possible to say anything definite about it as M² is not preserved in the maxilla, only a part of the anterior wall of its alveolus being retained. As nothing is known of the stage of development of upper second molar, except that it had not yet erupted, it cannot be determined whether it would erupt before or after the premolars and canine. Thus the Tangier maxilla does not give us any definite information about the sequence of eruption of the upper permanent teeth, except a suggestion that C¹ may erupt after the upper premolars.

The state of eruption of the permanent teeth of the child's skull from the cave of Teshik-Tash in Central Asia is described by Weidenreich as follows: "*In the lower jaw of the Uzbekistan child the permanent incisors and the first molars are in place. But the milk dentition is still represented by the two milk molars and the canine. In the upper jaw the same conditions occur, only the first milk molar has fallen out. The canines and the first premolars are on the point of eruption and more advanced in the upper than in the lower jaw. But the second molars are still deeply embedded in their sockets in both jaws and do not show any indication of erupting. It follows from this fact that the sequence of eruption is that of the modern human type and not that of the Neanderthals. Unfortunately, we do not know how the conditions of the Skhul population have been in this regard.*"¹¹⁷

From the photographs reproduced by Weidenreich¹¹⁸ and Movius¹¹⁹ it is observed that the second upper and lower molars are still *in situ* and there does not seem to be any indication that the second upper and lower premolars were getting ready to erupt. The same also appears to be true for the lower permanent canine and lower first premolar, which are still deeply embedded in the mandible. Of the successional teeth upper first premolar just reaches the level

¹¹⁸ Weidenreich, 1945B, pl. 1.

¹¹⁹ Movius, 1953, pl. VI, figs. 1-3.

of alveolar border and the upper permanent canine occupies a slightly higher position than the former. That is, these two teeth cannot properly be considered to have erupted. However, their locations suggest that, as is implied by Weidenreich,¹²⁰ P¹ and then C¹ might perhaps erupt before M². However, as none of these teeth had yet erupted, it is apparent that for a definite determination in this regard more fossil material from this region is needed.

The Teshik-Tash child, whose exact geological age is not known,¹²¹ is regarded by Weidenreich as a form midway between *Homo neanderthalensis* and *Homo sapiens*.¹²² The suggestion that P¹ and C¹ might erupt before M² in this skull, would seem to favor Weidenreich's viewpoint.

To sum up, it can be stated that the only satisfactory information on the eruption of the permanent dentition in *Homo neanderthalensis* is obtained from Krapina and Ehringsdorf remains, which date from the Riss-Würm interglacial. The sequences of eruption of upper and lower permanent teeth indicated respectively by Krapina and Ehringsdorf specimens are as follows:¹²³

Krapina	:	M ¹ I ¹ I ² (M ² C ¹) P P M ³
Ehringsdorf	:	(M ₁ I ₁) I ₂ M ₂ C ₁ P ₁ P ₂ M ₃

The sequence of eruption of the upper permanent teeth of Krapina Neanderthals differs from those of the living anthropoids only in the position of the canine. The place of the canine in the order of eruption of the lower teeth of the Ehringsdorf child, whether it erupts before or after M₂, of which the latter seems more likely, also constitutes the only difference between the sequences of the mandibular teeth of Ehringsdorf Neanderthal on the one hand and those of the

¹²⁰ Weidenreich, 1945B, p. 158.

¹²¹ Regarding the geological age of this find, Movius (1953, p. 52), states: "It is therefore tentatively suggested that this site was occupied by Neanderthal man during the Central Asiatic equivalent of what is called Würm I/II Interstadial in terms of Alpine chronology, although the possibility that it is older -i. e. Riss-Würm Interglacial — cannot be entirely ruled out. Certainly in the light of what we now know concerning the Pleistocene sequences in Eurasia, however, there is no justification whatsoever for the view put forward by Okladnikov and Gromova that Teshik-Tash dates from Mindell-Riss times."

¹²² Weidenreich, 1945B, pp. 160-161.

¹²³ For the meaning of the letters in parentheses see footnote 107.

living anthropoids, *Australopithecus* and Peking Man on the other. Thus it appears that in these early Neanderthals of Riss-Würm interglacial age the eruption of the permanent canines was further accelerated as compared with those of *Australopithecus* and Peking Man. However, Le Moustier and Tangier specimens indicate that the time of eruption of the permanent canines in *Homo neanderthalensis* was rather variable and that some forms or individuals of this species were probably not as advanced as the Krapina and Ehringsdorf specimens in this regard.

Finally the Teshik-Tash child suggests that in, strictly morphologically speaking, some advanced forms of Neanderthal Man some progressive changes such as for instance the seemingly earlier appearance of P¹ than of M², may have taken place in the sequence of eruption of the permanent teeth.

Homo sapiens: The sequence of eruption of the permanent teeth of fossil representatives of *Homo sapiens* is imperfectly known. Regarding the Grimaldi adolescent of lower Aurignacian Age from Grotte des Enfants, Boule, Vallois and Verneau state: "*Sur le jeune Négroïde de Grimaldi, la deuxième prémolaire supérieure gauche de lait est encore fonctionnelle, bien que la deuxième arrière-molaire définitive soit en place.*"¹²⁴ This situation is seen in the drawing published by Gaudry¹²⁵ and reproduced by Verneau¹²⁶ and Boule and Vallois.¹²⁷ However, regarding the teeth of Grimaldi adolescent Gaudry, in 1903, had stated: "*Ce crâne provient d'un jeune homme chez qui les prémolaires n'avaient point encore chassé les dernières molaires de lait de la mâchoire supérieure et où les dents de sagesse restaient cachées dans l'intérieur des mâchoires en haut et en bas. Il était nécessaire de les dégager et de les mettre au niveau des autres dents; mon ami M. Marcellin Boule s'est chargé de ce travail délicat. Ainsi, nous connaissons dans son entier la dentition à l'état adulte (voir figures 1, 2, 7, 10, 13). M. Boule a laissé seulement d'un côté, à la mâchoire supérieure, la dent de lait sous laquelle est placée la dernière prémolaire (fig. 1).*"¹²⁸ This procedure adopted at the beginning of this century, viz.,

¹²⁴ Boule, Vallois and Verneau, in Arambourg, Boule, Vallois and Verneau, 1934, p. 145.

¹²⁵ Gaudry, 1903, fig. 1.

¹²⁶ Verneau, 1906, fig. 23.

¹²⁷ Boule and Vallois, 1952, fig. 208.

¹²⁸ Gaudry, 1903, p. 3.

placing the unerupted teeth in positions they would occupy in adulthood, is hardly a commendable one. But still Gaudry's statement implies that not only the left but also the right upper second premolar had not erupted.

It is evident that the dentition of the Grimaldi adolescent should be restudied with a view to determine the exact stage of eruption of the permanent teeth at the time of death. At the moment all that can be said is that in this adolescent individual M^2 had preceded P^2 in eruption.

Regarding the state of eruption of the permanent teeth in Predmost specimen VII, Matiegka states: "*Toutes les secondes molaires permanentes sont pleinement développées; en revanche seules, P_1 sup. sin. et P_2 inf. dext. ont percé, tandis que m_2 sup. dext. est encore en place, et les autres m_2 et m_1 sont bien tombées, mais elles n'ont pas encore été remplacées.*"¹²⁹ It thus appears that in this Predmost skull the premolars, at least some of them, were preceded by the second permanent molars in eruption.¹³⁰

Weidenreich gave the following sequence of eruption for the prehistoric Afalou peoples of Northwest Africa: " $M_1 I_1 I_2 M_2 P_1 P_2 C M_3$ or even $M_3 C$."¹³¹ However, it is not known how Weidenreich arrived at this result, as only a part of this sequence is supported by the available data on the Afalou peoples, which are now assigned by Briggs, following the dating of Aymé and Balout to the Mesolithic period.¹³²

¹²⁹ Matiegka, 1934, p. 133.

¹³⁰ Regarding Predmost skull VII Matiegka (1934, p. 133) further stated: "*G. Elliot Smith voit, dans le fait que sur la mâchoire d'Ehringsdorf la second molaire a percé, tandis que les deux molaires de lait ne sont pas encore remplacées, la preuve que la dentition s'opérait chez l'homme de Néanderthal à la façon des anthropoïdes. Notre crâne no VII pouvait fournir la preuve qu'encore dans le quaternaire supérieur, ce processus de dentition s'était assez souvent conservé chez l'homme, s'il ne s'agit pas ici d'un phénomène individuel.*" In this connection it may also be mentioned that in Predmost mandible XXV depicted by Matiegka (1934, pl. 15) the milk molars are still implanted in the mandible, while the second permanent molar, although unerupted, has risen to the vicinity of the alveolar border.

¹³¹ Weidenreich, 1937, p. 122.

¹³² Briggs, 1955, p. 13. Aymé and Balout's (1943) and Balout's (1948) papers, cited by Briggs (1955, p. 13) were unhappily unavailable to me.

Regarding the eruption of the permanent teeth in Afalou skulls, Boule, Vallois and Verneau stated: "*Le seul sujet où l'on puisse observer le remplacement des dents de lait, l'enfant n° 26, présente en effet la disposition suivante à la mâchoire supérieure, seule conservée: les première et deuxième arrière-molaires définitives sont en place, ainsi que les deux incisives et la première prémolaire. Les deuxième prémolaires sont sorties, mais elles n'ont pas tout à fait atteint le plan des autres. Enfin les canines de lait sont encore présentes et fonctionnelles.*

Sur deux enfants plus âgés, le remplacement des dents de lait était complet et, seules, les troisièmes arrière-molaires étaient encore incluses. Mais sur deux sujets à peine adultes, à en juger par la très faible usure de leurs dents, des retards d'éruption des canines supérieures s'observaient encore. Dans un cas, les incisives, prémolaires et arrière-molaires définitives, sont toutes en place, mais les canines fonctionnelles sont celles de lait, tandis que, derrière elles, sur la face inférieure du palais, les canines définitives sont encore incluses dans leur loge. Dans l'autre cas, toutes les dents définitives sont sorties, y compris la canine droite, mais la gauche commence à peine son éruption, et l'alvéole de la canine de lait est encore largement ouvert, signe que cette dent venait seulement de tomber.

*Ces constatations paraissent bien indiquer que, chez les Hommes d'Afalou, il existait une tendance à un retard d'éruption de la canine définitive. Le rapprochement de ce fait avec ceux que nous avons rapportés pour divers Hommes paléolithiques laisse supposer que, chez les races préhistoriques, l'ordre d'éruption des dents permanentes n'a pas toujours été le même que chez les Hommes actuels. Des recherches étendues à d'autres sujets permettraient d'obtenir plus de précisions sur ce point."*¹³³

This description only shows that P² erupts later than M² and that the upper canine appears after P² and indeed, in at least some cases,¹³⁴ even later than M³, as is expressed in the sequence of eruption given by Weidenreich.¹³⁵ On the other hand, this description

¹³³ Boule, Vallois and Verneau, in Arambourg, Boule, Vallois and Verneau, 1934, pp. 145-146.

¹³⁴ It is not known whether the two specimens described by Boule, Vallois and Verneau (1934, p. 146) as "*Sur deux enfants plus âgés, le remplacement des dents de lait était complet et, seules, les troisièmes arrière-molaires étaient encore incluses.*", are upper or lower jaws.

¹³⁵ Weidenreich, 1937, p. 122.

does not tell us whether P^1 erupts before of after M^2 and in what order M_1 and I_1 appeared.

Regarding the time of eruption of the wisdom teeth in Afalou skulls, Boule, Vallois and Verneau state: "*Notons enfin que, contrairement à ce qui se passe aujourd'hui, les troisièmes arrière-molaires des Hommes d'Afalou présentaient habituellement une éruption très précoce: déjà en place sur l'adolescent n° 38, elles étaient également sorties sur le n° 1, plus âgé, mais où les épiphyses des os des membres ne sont pas encore soudées. Nous avons indiqué plus haut qu'elles ne faisaient qu'exceptionnellement défaut chez les adultes. Il semble que leur éruption devait suivre de très près celle des deuxièmes arrière-molaires.*"¹³⁶ It thus appears that in these prehistoric peoples the wisdom teeth were early to erupt, as is also a characteristic of modern Zulus, studied by Suk.¹³⁷

It was stated before that in the mandible of a Chalcolithic child from Anatolia (Troy No. 1 Tr.), the lower second permanent molar erupts before the first and second lower premolars. Among the crania of ancient Anatolians there are some where one or more premolars, in one jaw or the other, erupt later than the second molars, as well as specimens in which one or more premolars precede the second molars.¹³⁸

In a recent study on the teeth of ancient Athenians, Philippas has published the skiagram of the mandible of an ancient Athenian child which clearly shows that M_2 is erupting, while P_1 and P_2 are still unerupted.¹³⁹

¹³⁶ Boule, Vallois and Verneau, in Arambourg, Boule, Vallois and Verneau, 1934, p. 146. It may also be mentioned here that from the description given by Boule and Vallois it appears that in at least some individuals among the Mesolithic peoples of Tévéc, the third permanent molars also erupted rather early, as these authors have noted its presence in an adolescent individual (see Marthe and St. Just Péquart, Boule and Vallois, 1937, p. 138). Among 28 specimens from Tévéc studied by Boule and Vallois, these authors observed that the third permanent molars had not erupted only in one adult female individual (M. and St. Just Péquart, Boule and Vallois, 1937, p. 138). Regarding this Boule and Vallois (in M. and St. Just Péquart, Boule and Vallois, 1937, p. 138) state: "*Elles ne font défaut qu'à la mâchoire supérieure de la jeune femme n° 18 (de 20 à 30 ans)....*"

¹³⁷ Suk, 1919.

¹³⁸ Eruption of the permanent teeth in ancient Anatolians will be discussed in detail in a coming paper.

¹³⁹ Philippas, 1952, fig. 8. Philippas has also published the skiagram of the mandible of another ancient Athenian child, which shows that M_2 , although

From the account given it is clear that the ancient representatives of *Homo sapiens* reviewed were still in possession of some primitive traits in the order of eruption of their permanent teeth.

As for the order of eruption of the permanent teeth in the modern primitive peoples, in an often cited paper published in 1932, Drennan, of the University of Capetown, demonstrated that in four mandibles belonging to Bushmen the second permanent molars preceded the two premolars in eruption.¹⁴⁰ From a statement of Drennan, it appears that the same is also true for the maxillary teeth of Bushmen.¹⁴¹ But while Drennan has published the skiagrams of four mandibles, he has unfortunately not given the pictures of the upper jaws. In this very important study, Drennan also does not make any statement regarding the place occupied by the permanent canines in the sequence of eruption of the permanent teeth, at least relative to M₂.

Regarding the order of eruption of the permanent teeth in the Australian aborigines, Campbell states: "*A series of more than twenty skulls of young individuals among the present material provided various stages of transition from the deciduous to the permanent dentition, and a few notes have been made to indicate the sequence in which the permanent teeth erupt. The number of specimens is hardly sufficient to justify any hard and fast statements, but the following conclusions were arrived at.*

It would appear that the upper first permanent molars and central incisors erupt at about the same time. Then follow the lateral incisors; and next the first premolars. The second premolars and canines erupt about the same time, but this period was not well represented in the series. Then come the second molars and finally the third molars.

In the lower jaw the sequence is apparently similar, except that the canine appears to come before the second premolar, and rather keeps pace with the first premolar. This latter feature is recognized as taking place in white children also."¹⁴² The sequence described by Campbell comes near

unerupted, is just below the alveolar margin, while P₁ and P₂ are still deeply buried below the still functioning first and second milk molars.

The brief remarks of Bay show that primitive conditions in the order of eruption existed also in some Neolithic and historic peoples of central and western Europe (see Bay, 1946-47, p. 4).

¹⁴⁰ Drennan, 1932, p. 493. For Drennan's findings see also: Boule, Vallois and Verneau, in Arambourg, Boule, Vallois and Verneau, 1934, p. 145; Weidenreich, 1937, p. 122; Dart, 1948, p. 394; Clements and Zuckerman, 1953, p. 324.

¹⁴¹ See Drennan, 1932, p. 493. For this Drennan (1932, p. 493) states: "*L'ordre d'éruption pour les dents des maxillaires supérieurs est aussi interverti.*"

to the norm for modern Europeans. However, an examination of the pictures published by Campbell¹⁴³ and Jones¹⁴⁴ show some deviations from the described pattern.

The skiagram of a mandible published by Campbell¹⁴⁵ shows that M_2 has begun to erupt, while the second milk molar is still *in situ*, P_2 being located below it. From the photograph of a palate published by the same author,¹⁴⁶ it is seen that M^2 has already erupted,¹⁴⁷ the right P^2 has begun to erupt,¹⁴⁸ while the left second milk molar is still in place. Similarly from the photograph of an Australian aborigine given by Jones¹⁴⁹ it is seen that the occlusal surface of the left upper second permanent molar has slightly protruded beyond the alveolar border, while the first and second left upper milk molars are still *in situ*. It is seen that in some individuals of Australian aborigines the premolars, at least some of them, may still erupt later than the second permanent molars. Thus the sequence of eruption of the permanent teeth of recent Australian aborigines seems to be variable, in some individuals the premolars erupting later and in some earlier than the second permanent molars, the latter condition being, according to the findings of Campell,¹⁵⁰ the more frequent.

In their study of 1926 Gregory and Hellman Published the photographs and skiagrams of the mandibles of two young American Indians from Tarasco.¹⁵¹ From the photograph and skiagram it is seen that in the older child M_2 has begun to erupt, while the permanent canine, P_1 and P_2 are still unerupted.¹⁵² That is, in this mandible M_2 precedes C_1 , P_1 and P_2 in eruption which is a primitive condition.

According to the figures given by Suk,¹⁵³ in Zulus of South

¹⁴² Campbell, 1925, pp. 54-55.

¹⁴³ Ibid.

¹⁴⁴ Jones, 1947.

¹⁴⁵ Campbell, 1925, pl. IV, fig. 2.

¹⁴⁶ Ibid., pl. XXXIV, fig. 1.

¹⁴⁷ The right M^2 has been lost, only its alveolus being preserved.

¹⁴⁸ For P^2 see Campbell, 1925, p. 63.

¹⁴⁹ Jones, 1947, pl. 2, fig. A.

¹⁵⁰ See Campbell, 1925, pp. 54-55.

¹⁵¹ See Gregory and Hellman, 1926, pls. XVIII and XIX.

¹⁵² Ibid., pl. XVIII, fig. D and pl. XIX, upper figure. For Tarasco indians, New Caledonians and Papuans see Bay, 1946/47, p. 5.

¹⁵³ Suk, 1919. For Suk's figures see also Shaw (1931, table LI) and Schultz (1935, table 4.).

Africa, in both the upper and lower jaws, the permanent canine and the two premolars usually precede the second permanent molars in eruption, that is, the order of eruption of the permanent teeth in Zulus does not seem to differ, on the average, from the norm of modern Europeans.

The orders of eruption of the permanent upper and lower teeth in recent Whites are listed below. In this table the order of eruption of the group listed as Europeans is derived from the averages of Röse, recorded by Schultz¹⁵⁴ and those of other groups are taken from the orders of eruption listed by Clements, Davies-Thomas and Pickett.¹⁵⁵ In this table, in series where the orders of eruption of the upper and lower teeth are the same in males and females, one sequence is given for both sexes.

	Maxilla	Mandible
Europeans (Male & Female). Röse, cited by Schultz, 1935.	M ¹ I ¹ I ² P ¹ P ² C ¹ M ²	M ₁ I ₁ I ₂ C ₁ P ₁ P ₂ M ₂
Sweden (Male & Female). Clements, Davies-Thomas and Pickett, 1953A, after Dahlberg and Maunsbach, 1948.	I ¹ I ² P ¹ P ² C ¹ M ²	I ₂ C ₁ P ₁ P ₂ M ₂
Hungary. Clements, Davies-Thomas and Pickett, 1953 A, after Gödény, 1951.	Male: I ¹ I ² P ¹ P ² C ¹ M ² Female: I ¹ I ² P ¹ C ¹ P ² M ²	I ₂ C ₁ P ₁ P ₂ M ₂ I ₂ C ₁ P ₁ P ₂ M ₂
America (Male & Female). Clements, Davies-Thomas and Pickett, 1953A, after Klein, Palmer and Kramer, 1937.	M ¹ I ¹ I ² P ¹ P ² C ¹ M ²	M ₁ I ₁ I ₂ C ₁ P ₁ P ₂ M ₂

¹⁵⁴ Schultz, 1935, table 4.

¹⁵⁵ Clements, Davies-Thómas and Pickett, 1953A, table VI.

New Zealand (Male & Female).

Clements, Davies - Thomas and Pickett, 1953A, after Leslie, 1951.

$M^1 I^1 I^2 P^1 C^1 P^2 M^2$ $I_1 M_1 I_2 C_1 P_1 M_2 P_2$

Britishers (Male & Female).

Clements, Davies - Thomas and Pickett, 1953A, after Ainsworth, 1925.

$M^1 I^1 I^2 P^1 P^2 C^1 M^2$ $M_1 I_1 I_2 C_1 P_1 P_2 M_2$

Britishers (Birmingham series). Male & Female.

Clements, Davies - Thomas and Pickett, 1953A.

$M^1 I^1 I^2 P^1 C^1 P^2 M^2$ $I_1 M_1 I_2 C_1 P_1 M_2 P_2$

From this table it is seen that in Röse's European, Ainsworth's British and Klein, Palmer and Kramer's American series M_1 erupts before I_1 which is, as we have seen, the primitive condition, whereas in Clements, Davies-Thomas and Pickett's British and Leslie's New Zealand series the reverse is the mode, which represents the advanced condition. It is thus seen that the order of eruption of M_1 relative to I_1 is still variable in recent whites, in some M_1 and in others I_1 being the first tooth to erupt.

This table further shows that in most recent white groups, with the only exception of the lower second premolar in Clements, Davies-Thomas and Pickett's British and Leslie's New Zealand series, the permanent canines and the two premolars precede in eruption, in both jaws, the second permanent molars, the lower canine preceding the lower premolars and the upper canine appearing sometimes after and sometimes before the upper second premolar.

In Clements, Davies-Thomas and Pickett's Birmingham and Leslie's New Zealand series the second lower premolar succeeds the lower second permanent molar in eruption, in which these two series differ from all the other white series listed. Regarding the order of eruption of the teeth in the Birmingham series, Clements, Davies-Thomas and Pickett state: "*The eruption times of the I_1 and M_1 teeth and the Pm_1 , Pm_2 , and M_2 teeth are so similar that sampling varia-*

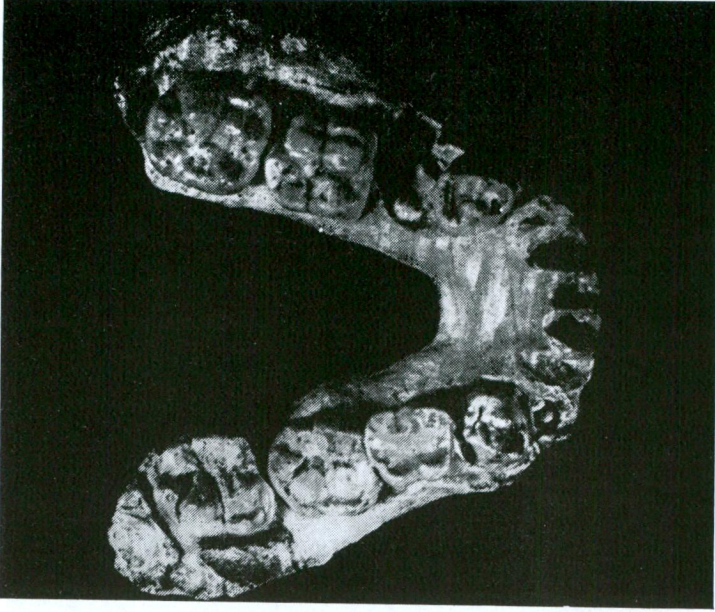


Fig. 1

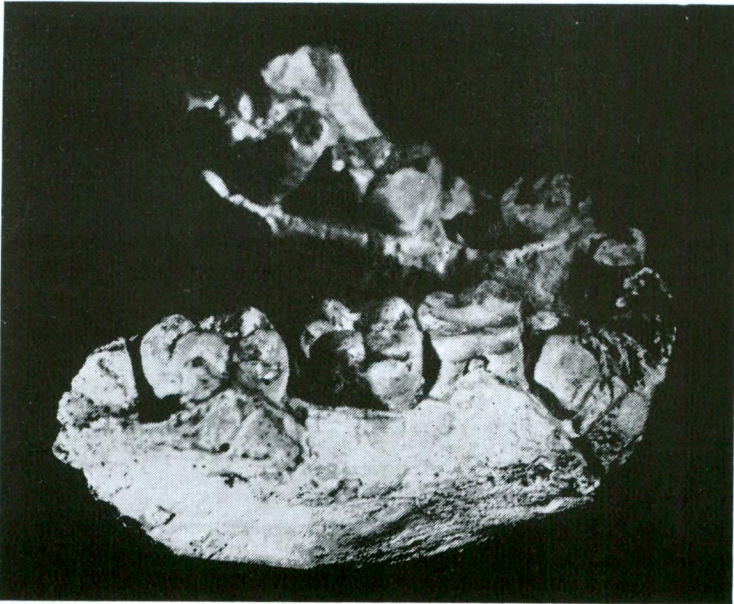


Fig. 2

M. Şenyürek

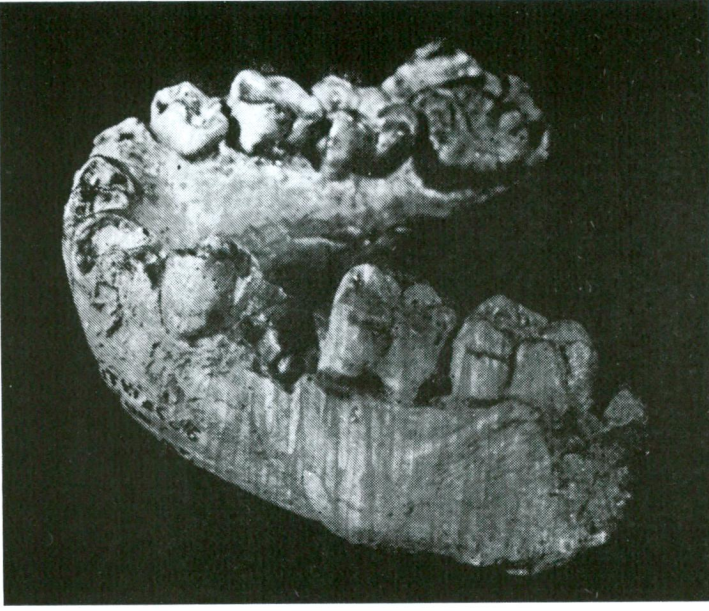

Fig. 3

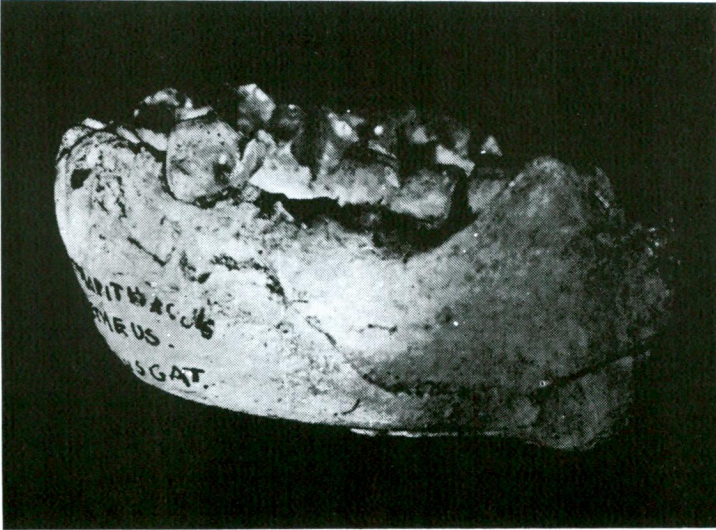

Fig. 4

tion can give rise to a different order of eruption in a proportion of determinations."¹⁵⁶ Indeed, a comparison of Birmingham series with Ainsworth's British series indicates that the difference observed in the position of P_2 in the more recent survey, is probably mainly due to sampling. But still, irrespective of this, it appears that there is an inherent tendency in modern Britishers to have lower P_2 erupt after M_2 , which also seems to be the case in the New Zealand series.

Although the sequence of eruption of the permanent teeth in the majority of the recent whites conspicuously differs from the ancestral condition, still some traces of the primitive condition are encountered among them. According to the findings of Clements, Davies-Thomas and Pickett, among the modern British population, in 4.5-7.7% of the boys and 5.7-6.3% of the girls the upper permanent canine and the two premolars and in 8.7-9.2% of the boys and 3.0-4.2% of the girls the lower permanent canine and the lower premolars erupt later than the upper and lower permanent second molars respectively.¹⁵⁷

This brief survey shows that the primitive condition where the premolars erupt before the second permanent molars is still retained, to various degrees, in some recent primitive peoples and even in some of the modern whites. The advanced condition where the premolars precede the second permanent molar in eruption is seen in modern whites, Zulus and even in some of the Australian aborigines.

SUMMARY AND CONCLUSION

This review has shown that the sequence of eruption of the permanent teeth in the earliest fossil hominids comes near to that of the living anthropoid apes, thus proving that the condition found in some recent men where the permanent canine and the two premolars erupt before the second permanent molar is a recent acquisition, as has already been concluded by Schultz.¹⁵⁸

¹⁵⁶ Ibid., p. 8

¹⁵⁷ Clements, Davies-Thomas and Pickett, 1953B, table III.

¹⁵⁸ See Schultz, 1935, p. 542. Schultz (1935, p. 542) states in this regard: "*The human specializations consist in the rapid succession in eruption of the M_1 and I_2 , in the complete replacement of the deciduous dentition before the M_2 are being added to the permanent dentition, and in the appearance of the lower C before at least the P_2 . In other words, it is unquestionably a new and exclusive acquisition of man that his M_2 erupt comparatively late and his Premolars and, particularly, Canines relatively early.*"

It is evident that all recent races of man have passed through a stage, still retained by some recent groups, where the two premolars erupted later than the second permanent molars. It is also clear that the modification of this ancestral pattern has not proceeded at the same pace in all modern races, so that some still retain more of this primitive condition, while in others, during the course of their evolution it has been modified to varying degrees.

It appears that the order of eruption of the permanent teeth in Swartkrans ape-man, as is indicated by the eruption of the two upper premolars later than the upper second molar in Krapina Neanderthals and the relatively late appearance of the permanent canines in the Afalou peoples, has been acquired independently of that of recent man. That is, the approachment of the sequence of eruption of the permanent teeth of Swartkrans ape-man to that of some modern men appears to be due to parallelism.

LITERATURE CITED

- ARAMBOURG, C., BOULE, M., VALLOIS, H. and VERNEAU, R. 1934. *Les grottes paléolithiques des Beni Sgoual (Algérie)*. Archives de l'Institut de Paléontologie Humaine, Mémoire 13, Paris.
- BAY, R. 1946—47 *Die Zahndurchbruchfolge in der menschlichen Stammesgeschichte*. Bulletin der Schweizerischen Gesellschaft für Anthropologie und Ethnologie, 23. Jahrgang, pp. 4-5.
- BLACK, D. 1934. *On the discovery, morphology and environment of Sinanthropus pekinensis*. Philosophical Transactions of the Royal Society of London, Series B, Vol. 223, pp. 57-120.
- BOULE, M. and VALLOIS, H. V. 1952. *Les hommes fossiles. Éléments de paléontologie humaine*. Paris.
- BRIGGS, L. C. 1955. *The stone age races of Northwest Africa*. American School of Prehistoric Research, Peabody Museum, Harvard University, Bulletin No. 18, Cambridge, Massachusetts.
- BROOM, R. 1934. *Les origines de l'homme*. Payot, Paris.
- BROOM, R. and SCHEPERS, G. W. H. 1946. *The South African fossil ape-men. The Australopithecinae* (Part I by Broom; Part II by Schepers). Transvaal Museum Memoir No. 2, Pretoria.
- BROOM, R., ROBINSON, J. T. and SCHEPERS, G. W. H. 1950. *Sterkfontein ape-man Plesianthropus* (Part I by Broom, and Robinson; Part II by Schepers). Transvaal Museum Memoir No. 4, Pretoria.

- BROOM, R. and ROBINSON, J. T. 1951. *Eruption of the permanent teeth in the South African fossil ape-men*. *Nature*, vol. 167, no. 4246, p. 443.
- BROOM, R. and ROBINSON, J. T. 1952. *Swartkrans ape-man Paranthropus crassidens*. Transvaal Museum Memoir No. 6, Pretoria.
- CAMPBELL, T. D. 1925. *Dentition and palate of the Australian aboriginal*. University of Adelaide. Publications under the Keith Sheridan Foundation, No. 1, Adelaide.
- CLARK, W. E. LE GROS. 1949. *History of the Primates. An introduction to the study of fossil man*. British Museum (Natural History), London.
- CLARK, W. E. LE GROS. 1952 *Hominid characters of the Australopithecine dentition*. *Journal of the Royal Anthropological Institute*, Vol. LXXX (1950), pp. 37-54.
- CLEMENTS, E. M. B., DAVIES-THOMAS, E. and PICKETT, K. G. 1953A. *Time of eruption of permanent teeth in British children in 1947-48*. *British Medical Journal*, Vol. i, June 27 (Reprint, 11 p.).
- CLEMENTS, E. M. B., DAVIES-THOMAS, E. and PICKETT, K. G. 1953B. *Order of eruption of the permanent human dentition*. *British Medical Journal*, Vol. i, June 27 (Reprint, 7 p.).
- CLEMENTS, E. M. B. and ZUCKERMAN, S. 1953. *The order of eruption of the permanent teeth in the Hominoidea*. *American journal of Physical Anthropology*, Vol. II, N. S., No. 3, pp. 313-332.
- DART, R. A. 1925. *Australopithecus africanus. The man-ape of South Africa*. *Nature*, London, CXV, pp. 195-199.
- DART, R. A. 1948. *The adolescent mandible of Australopithecus prometheus*. *American Journal of Physical Anthropology*, Vol. 6, N. S., No. 4, pp. 391-409.
- DART, R. A. 1954. *The second, or adult, female mandible of Australopithecus prometheus*. *American Journal of Physical Anthropology*, Vol. 12, N. S., No. 3, pp. 313-343.
- Drennan, M. R. 1932. *L'ordre d'éruption des dents parmanentes chez les Boschimans*. *L'Anthropologie*, Vol. XLII, Nos. 5-6, pp. 491-495.
- GAUDRY, A. 1903. *Contribution à l'histoire des hommes fossiles*. *L'Anthropologie*, Vol. XIV, pp. 1-14.
- GORJANOVIĆ-KRAMBERGER, K. 1906. *Der diluviale Mensch von Krapina in Kroatien. Ein Beitrag zur Paläoanthropologie*. Wiesbaden.

- GORJANOVIĆ-KRAMBERGER, K. 1907. *Die Kronen und Wurzeln der Mahlzähne des Homo primigenius und ihre genetische Bedeutung*. Anatomischer Anzeiger, Vol. 31, pp. 97-134.
- GREGORY, W. K. 1920-1921. *The origin and evolution of the human dentition. A palaeontological review*. The Journal of Dental Research, Vol. II, Nos. 1, 2, 3 and 4 (1920) and Vol. III, No. 1 (1921).
- GREGORY, W. K. and HELLMAN, M. 1926. *The dentition of Dryopithecus and the origin of man*. Anthropological papers of the American Museum of Natural History, Vol. XXVIII, Part I.
- HOOIJER, D. A. 1951. *The geological age of Pithecanthropus, Meganthropus and Gigantopithecus*. American Journal of Physical Anthropology, Vol. 9, N. S., No. 3, pp. 265-281.
- HOWE, B. and MOVIUS, H. L. 1947. *A stone age cave site in Tangier. Preliminary report on the excavations at the Mugharet El 'Aliya, or High Cave, in Tangier*. Papers of the Peabody Museum of American Archaeology and Ethnology, Harvard University, Vol. XXVIII-No. 1, Cambridge, Massachusetts.
- JONES, H. G. 1947. *The primary dentition in Homo sapiens and the search for primitive features*. American Journal of Physical Anthropology, Vol. 5, N. S., No. 3, pp. 251-274.
- KEITH, SIR A. 1931. *New discoveries relating to the antiquity of man*. London.
- MARTIN, H. 1926. *Recherches sur l'évolution du Moustérien dans le gisement de la Quina (Charente)*. Quatrième volume, *l'enfant fossile de la Quina*. Angoulême.
- MATIEGKA, J. 1934. *Homo predmostensis. Fossilni člověk z Predmosti na Moravě. I. Lebky. L'homme fossile de Predmosti en Moravie (Tchécoslovaquie). I. Les crânes*. Prague.
- MOVIUS, H. L., Jr. 1953. *The Mousterian cave of Teshik-Tash, south-eastern Uzbekistan, Central Asia*. American School of Prehistoric Research, Peabody Museum, Harvard University, Bulletin 17, pp. 11-17.
- OAKLEY, K. P. 1954. *Dating of the Australopithecinae of Africa*. American Journal of Physical Anthropology, Vol. 12, N. S., no. 1, pp. 9-23.
- PÉQUART, MARTHE and SAINT-JUST, BOULE, M. and VALLOIS, H. 1937. *Téviec, station-nécropole mésolithique du Morbihan*. Archives de l'Institut de Paléontologie Humaine, Mémoire 18, Paris.

- PHILIPPAS, G. G. 1952. *Effects of function on healthy teeth: the evidence of ancient Athenian remains*. The Journal of the American Dental Association, Vol. 45, pp. 443-453.
- ROBINSON, J. T. 1954A. *The genera and species of the Australopithecinae*. American Journal of Physical Anthropology, Vol. 12, N. S., No. 2, pp. 181-200.
- ROBINSON, J. T. 1954B. *Prehominid dentition and hominid evolution*. Evolution, Vol. VIII, No. 4, pp. 324-334.
- SCHULTZ, A. H. 1935. *Eruption and decay of the permanent teeth in Primates*. American Journal of Physical Anthropology, Vol. XIX, No. 4, pp. 489-581.
- SCHULTZ, A. H. 1940. *Growth and development of the chimpanzee*. Carnegie Institution of Washington publication No. 518, Contributions to Embryology, No. 170, pp. 1-63.
- SCHULTZ, A. H. 1941. *Growth and development of the Orang - Utan*. Carnegie Institution of Washington Publication No. 525, Contributions to Embryology, No. 182, pp. 57-110.
- SCHULTZ, A. H. 1944. *Age changes and variability in Gibbons. A morphological study on a population sample of a man-like ape*. American Journal of Physical Anthropology, Vol. 2, N. S. No. 1, pp. 1-129.
- SCHULTZ, A. H. 1950A. *Morphological observations on gorillas*. In The Henry Cushier Raven Memorial Volume: Contributions to the anatomy of the Gorilla, pp. 227-248. Columbia University Press, New York.
- SCHULTZ, A. H. 1950B. *The physical distinctions of man*. Proceedings of the American Philosophical Society, Vol. 94, No. 5, pp. 428-449.
- ŞENYÜREK, M. 1940A. *Fossil man in Tangier (With an introduction by Carleton S. Coon)*. Papers of the Peabody Museum of American Archaeology and Ethnology, Harvard University, Vol. XVI-No. 3, Cambridge, Massachusetts.
- ŞENYÜREK, M. 1940B. *The extension of Neanderthal Man into North Africa*. Man, Vol. 40, No. 153, p. 128.
- ŞENYÜREK, M. 1941. *The dentition of Plesianthropus and Paranthropus*. Annals of the Transvaal Museum, Vol. XX, Part 3, pp. 293-302.
- ŞENYÜREK, M. 1955. *A note on the teeth of Meganthropus africanus Weinert from Tanganyika territory*. Belleten, Vol. XIX, No. 73, pp. 1-54.

- SHAW, J. C. M. 1931. *The teeth, the bony palate and the mandible in Bantu races of South Africa*. London.
- SUK, V. 1919. *Eruption and decay of permanent teeth in Whites and Negroes, with comparative remarks on other races*. American Journal of Physical Anthropology Vol. II, No. 4, pp. 351-388.
- VAUFREY, R. 1950. In: *L'Anthropologie*, Vol. 53, Nos. 5-6, pp. 501-505.
- VERNEAU, R. 1906. *Les grottes de Grimaldi (Baoussé-Roussé)*. *Anthropologie*. Tome II, Fascicule I, Monaco.
- VIRCHOW, H. 1920. *Die menschlichen Skeletreste aus dem Kämpfe'schen Bruch im Travertin von Ehringsdorf bei Weimar*. Jena.
- WEIDENREICH, F. 1936. *The mandibles of Sinanthropus pekinensis: A comparative study*. *Palaeontologia Sinica*, Series D, Vol. VII, Fascicle 3, Peiping.
- WEIDENREICH, F. 1937. *The dentition of Sinanthropus pekinensis: A comparative odontography of the hominids*. *Palaeontologia Sinica*, New Series D, No. 1 (Whole Series No. 101), Peiping.
- WEIDENREICH, F. 1945A. *Giant early Man from Java and South China*. Anthropological Papers of the American Museum of Natural History, Vol. 40, Part I.
- WEIDENREICH, F. 1945B. *The paleolithic child from the Teshik-Tash cave in southern Uzbekistan (Central Asia)* American Journal of Physical Anthropology, Vol. 3, N. S., No. 2, pp. 151-162.
- ZEUNER, F. E. 1940. *The age of Neanderthal man with notes on the Cotte de St. Brelade Jersey, C. I.* University of London, Institute of Archaeology, Geochronological Table No. 2, London.

EXPLANATION OF THE FIGURES

Figs. 1 - 4. Four views of the cast of the adolescent mandible of *Australopithecus* from Makapansgat.

