

Clinical evaluation of treatment with hook plate in patients with acromioclavicular joint dislocation

İsmail Büyükceran¹, Hikmet Çinka², Alparslan Yurtbay³, Hüseyin Sina Coşkun¹, Abdurrahman Murat Yıldırım⁴, Davut Keskin¹

¹Department of Orthopedics and Traumatology, Ondokuz Mayıs University Faculty of Medicine, Samsun, Turkey; ²Department of Orthopedics and Traumatology, Sakarya Karasu State Hospital, Sakarya, Turkey; ³Department of Orthopedics and Traumatology, Samsun University Faculty of Medicine, Samsun, Turkey; ⁴Department of Orthopedics and Traumatology, Samsun Bafra State Hospital, Samsun, Turkey

ABSTRACT

Objectives: Treatment of acromioclavicular joint dislocations vary. In this study, we aim to examine the functional results of patients who underwent hook plate fixation due to dislocation of acromioclavicular joint.

Methods: We retrospectively observed 21 patients who had been treated with hook plate due to dislocation of acromioclavicular joint. At follow up, Constant-Murley scoring system was performed for shoulder function evaluation, while radiological results were performed by X-ray.

Results: Seventeen of these patients were male and four were female. Eleven of these patients had Rockwood type 5 joint dislocation and ten had Rockwood type 3 joint dislocation. The mean age was 36.7 ± 13.37 years (range: 19-61 years). The mean follow-up period was 27.3 ± 19.3 months (range: 10-59). Constant-Murley shoulder scoring was excellent in 18 patients (93.6) and good (82.5) in 3 patients. While one patient had wound site infection and one patient had plate broken, no one had any neurological damage. Except for the failed implant, plate removal was not performed because the patients did not have plate-related complaints. At follow-up, it was observed that the acromioclavicular joint was in the reduced position on direct radiographs.

Conclusions: We observed good clinical and functional results for the treatment of acromioclavicular joint dislocation with hook plate treatment. The hook plate method is a safe and effective method in the acute treatment of type 3-5 injuries according to the Rockwood classification

Keywords: Acromioclavicular joint, dislocation, Rockwood classification, hook plate

The acromioclavicular (AC) joint is damaged in approximately 9% of the shoulder girdle injuries [1]. AC joint damage often occurs as a result of falling on the open and adducted arm indirectly or direct trauma to the lateral side of the shoulder.

The Rockwood classification is generally used to define the type of dislocation and determine treatment algorithms for AC joint dislocations [2]. According to

the Rockwood classification, AC joint injuries are divided into six subgroups. The degree of injury and the patient's functional expectations are the primary indicators when choosing the treatment method of the patients. While type 1 and 2 injuries are followed with conservative methods, surgery is recommended for type 4-6 injuries. For type 3 injuries, the optimal treatment method for type 3 injuries is controversial [3].

Received: April 6, 2023; Accepted: May 15, 2023; Published Online: August 15, 2023



e-ISSN: 2149-3189

How to cite this article: Büyükceran İ, Çinka H, Yurtbay A, Coşkun HS, Yıldırım AM, Keskin D. Clinical evaluation of treatment with hook plate in patients with acromioclavicular joint dislocation. Eur Res J 2023;9(5):1124-1128. DOI: 10.18621/eurj.1278637

Address for correspondence: Hikmet Çinka, MD., Sakarya Karasu State Hospital, Department of Orthopedics and Traumatology, 54500 Karasu, Sakarya, Turkey. E-mail: hkmtcnk@gmail.com, Phone: +90 264 718 11 43



©Copyright © 2023 by Prusa Medical Publishing
Available at <http://dergipark.org.tr/eurj>
info@prusamp.com

Various surgical procedures are available for AC joint dislocation such as coracoclavicular (CC) fixation, TightRope® fixation, hook plate, coracoacromial ligament transfer, AC or CC reconstruction [4].

In our study, we retrospectively evaluated the functional results of 21 patients who underwent hook plate due to AC joint dislocation.

METHODS

In our study, we examined 21 patients who applied to our clinic with the complaint of post-traumatic shoulder pain between November 2016 and February 2022 and treated with hook plate after AC joint dislocation was detected. Diagnosis made by direct radiography and MRI was used for Rockwood classification (Fig. 1). The patients included in this study were acute injuries of type 3-5 according to the Rockwood classification, older than 18 years of age, had no history of shoulder trauma or surgery to the shoulder region, and were not accompanied by a clavicle fracture.

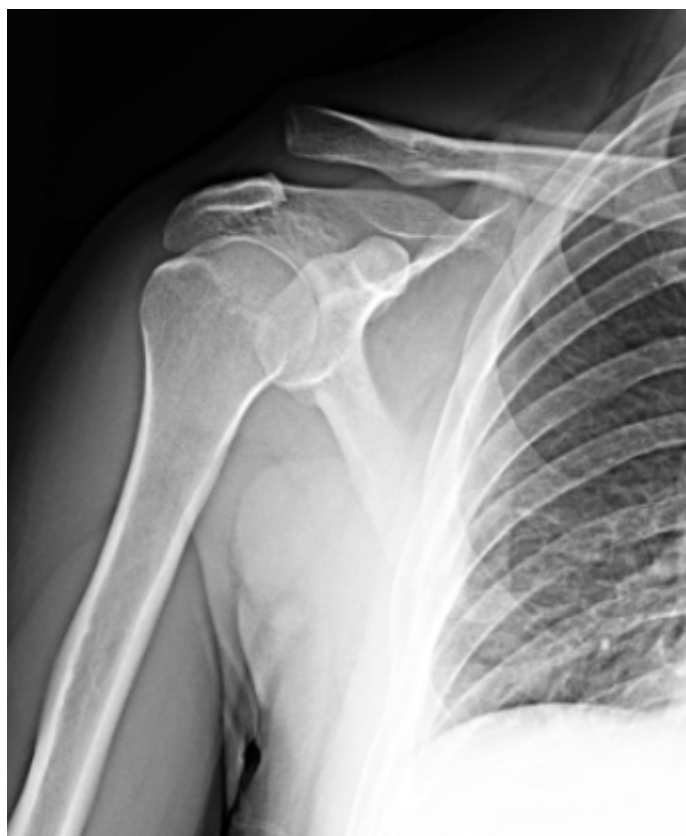

Fig. 1. X-ray image of acromioclavicular joint dislocation.

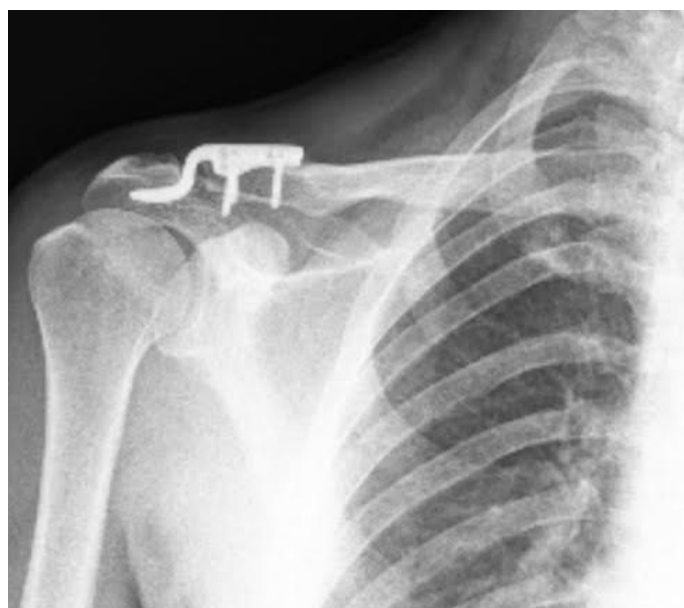


Fig. 2. Postoperative x-ray image

Surgical Technique

All of the patients were treated by the same surgical team and with the same surgical method. A skin incision of approximately 4 cm was made over the AC joint in beach-chair position under general anesthesia for all patients. The AC joint was exposed. After the joint reduction, we placed the tip of the hook plate under the acromion and fixation was made with three screws (Fig. 2). Joint reduction was confirmed after control imaging with scopy. Since no sign of impingement was detected in the intraoperative examination, the operation was terminated.

Patients were followed up with velpau bandage for 3 weeks after surgery. At the end of 3 weeks, the patients were allowed to use their shoulders in daily activities and rehabilitation was started. All movements were allowed at the end of the postoperative 6th week. While radiological results were evaluated by X-ray in the routine follow-up of the patients, Constant-Murley shoulder scoring was used for functional results.

The study was approved by the local Ondokuz Mayıs University Clinical Researchs Ethics Committee (Date: 2020, Decision Number: B.30.2.ODM.0.20.08/09-73-102). In this prospective study, all procedures and practices are in accordance with the ethical standards of the national/ institutional research committee and the 1964 Helsinki declaration. Informed consent was obtained from all patients.

RESULTS

Twenty-one patients who had AC joint dislocation were treated with hook plate. 17 of these patients were male and 4 were female. The mean age of the patients was 36.7 ± 13.37 years (range: 19-61 years). Eleven of the patients had right AC joint dislocation and ten of them had left AC joint dislocation. Demographic data are shown in Table 1. Eleven of these patients had Rockwood type 5 and ten had Rockwood type 3 AC joint dislocations.

The mean follow-up period was 27.3 ± 19.3 months (range: 10-59). While radiological results were evaluated by x-ray, Constant-Murley shoulder scoring was used for functional results. Constant-Murley shoulder scoring was excellent in 18 patients (93.6) and good (82.5) in 3 patients.

During the follow-ups, superficial wound infection was observed in 1 patient, and broken plate was observed in 1 patient after falling again, and no neurological damage was observed in any patient.

DISCUSSION

While AC joint dislocation is frequently seen in young athletes, it can also be seen in patients exposed to direct trauma [2]. According to the Rockwood classification, conservative methods are preferred in type 1-2 injuries and surgical methods are preferred in type 4-6 injuries, while the treatment of type 3 injuries is still controversial. While some authors recommend conservative treatment in patients with type 3 injuries, there are also authors reporting good clinical results of patients followed by surgical method [3, 5-8].

Surgical treatment methods vary [4]. In our study,

we applied hook plate to patients with type 3-5 injuries according to the Rockwood classification, and we evaluated the clinical results of these patients retrospectively. Radiological evaluation was evaluated using direct radiographs and functional results were evaluated using Constant-Murley scoring. Complications which developed during the follow-up were also recorded.

In the evaluation of 21 cases, we found the Constant-Murley shoulder score to be excellent in 18 patients (93.6) and good (82.5) in 3 patients. Our results were compatible with the literature [9-12]. We evaluated isolated AC joint dislocations in our study. There are also studies comparing the results of hook plate and other methods in the treatment of AC joint dislocation. Xin Pan *et al.* [13] compared the results of tight rope and hook plate application in the treatment of AC joint dislocation in their meta-analysis study. According to their study, both TightRope and hook plate techniques were effective in relieving dislocation pain and improving AC joint function, and they found Constant Murley scores similar to our study.

Surgical treatment of AC joint dislocation with hook plate is relatively easy. It requires small incisions and minimal dissection, and its use is increasing. In addition to the treatment of AC joint dislocation, hook plate can also be used in distal clavicle fractures [7, 14]. With this method, the biomechanics of the AC joint are preserved in both AC joint dislocation and fracture treatment, allowing some degree of early mobilization after surgery [15]. Beside these, there are publications reporting that hook plate use may cause bone erosion, osteolysis and subacromial impingement in the postoperative period, as well as general complications such as nonunion, infection and implant failure [16-18].

After AC joint dislocation surgery, superficial wound infection has been reported in the literature at rates of 0-53%. [19, 20]. In this study, a superficial wound infection was detected in one patient, which was consistent with the literature, and healing was achieved after follow-up with oral antibiotics and wound dressing.

There are publications reporting broken plate after hook plate treatment [11, 21]. In one of our patients, implant failure (broken plate) occurred after falling on the same shoulder again. On this case, plate was re-

Table 1. Characteristics of the patients

Characteristics	Data
Age (years)	36.7 ± 13.37 (19-61)
Gender (female/ male)	4/17
Side (right/ left)	11/10
Follow-up period (months)	27.3 ± 19.3 (10-59)
Complication	2 (9%)

moved. The AC joint was found to be stable in the intraoperative examination and scopy images.

In a cadaver study, it was shown that hook plate fixation allows physiological clavicular movement without deformation and shows similarity to the stiffness of the natural AC joint [22]. This study suggests that hook plates can be left in place in asymptomatic patients. In our study, apart from the patient who developed implant failure, we did not perform implant removal because other patients did not have any complaints. Thus, we thought that while avoiding the risk of loss of reduction after removal of the implant, we could avoid anesthesia-related risks and possible local complications due to additional surgery to be performed for removal.

Limitations

This study has some limitations. It was conducted in a single center and the number of patients was relatively low. Comparisons could be made with other surgical methods with larger series. ith other surgical methods with larger series.

CONCLUSION

In conclusion, we think that the hook plate method is a safe and effective method in the acute treatment of type 3-5 injuries according to the Rockwood classification. With the hook plate method, early functional treatment is possible and we can prevent limitations in postoperative shoulder function. We think that the risks of re-dislocation and a second surgical procedure can be avoided by not removing the plate in patients who do not have active complaints related to plate. However, larger series studies are also needed.

Authors' Contribution

Study Conception: İB; Study Design: HSC; Supervision: DK; Funding: N/A; Materials: AMY; Data Collection and/or Processing: HÇ; Statistical Analysis and/or Data Interpretation: AY; Literature Review: İB, HÇ, AY, HSC, AMY, DK; Manuscript Preparation: İB, HÇ and Critical Review: AY, HSC.

Conflict of interest

The author disclosed no conflict of interest during the preparation or publication of this manuscript.

Financing

The author disclosed that they did not receive any grant during conduction or writing of this study. grant during conduction or writing of this study.

REFERENCES

- Mazzocca AD, Arciero RA, Bicos J. Evaluation and treatment of acromioclavicular joint injuries. *Am J Sports Med* 2007;35:316-29.
- Phillips A, Smart C, Groom A. Acromioclavicular dislocation: conservative or surgical therapy. *Clin Orthop Rel Res* 1998;353:10-7.
- Spencer EE Jr. Treatment of grade III acromioclavicular joint injuries: a systematic review. *Clin Orthop Rel Res* 2007;455:38-44.
- Cote MP, Wojcik KE, Gomlinski G, Mazzocca AD. Rehabilitation of acromioclavicular joint separations: operative and non-operative considerations. *Clin Sports Med* 2010;29:213-28.
- Lizaur A, Sanz-Reig J, Gonzalez-Parreño S. Long-term results of the surgical treatment of type III acromioclavicular dislocations: an update of a previous report. *J Bone Joint Surg Br* 2011;93:1088-92.
- Hootman JM. Acromioclavicular dislocation: conservative or surgical therapy. *J Athl Train* 2004;39:10-1.
- Wu J, Liao Q, Chen G, Zhong D, Li K, Li R. [Clavicular hook plate in the treatment of dislocation of acromioclavicular joint and fracture of distal clavicle]. *Zhong Nan Da Xue Xue Bao Yi Xue Ban* 2006;31:595-8. [Article in Chinese]
- Reška M, Konečný J, Kašpar M, Kábelka M, Cierník J. [Stabilisation of the dislocated acromioclavicular joint and lateral fractures of the clavicle using a hook plate]. *Rozhl Chir* 2013;92:143-50. [Article in Czech]
- Oh JH, Min S, Jung JW, Kim H-J, Kim JY, Chung SW, et al. Clinical and radiological results of hook plate fixation in acute acromioclavicular joint dislocations and distal clavicle fractures. *Clin Shoulder Elbow* 2018;21:95-100.
- Baran MA, Dinçel YM, Beytemür O, Çağlar S, Adanır O, Alagöz E. [Clavicle hook plate technique and its functional results in the treatment of acromioclavicular joint dislocation]. *Kafkas J Med Sci* 2015;5::13-7. [Article in Turkish]
- Kienast B, Thietje R, Queitsch C, Gille J, Schulz A, Meiners J. Mid-term results after operative treatment of rockwood grade III-V acromioclavicular joint dislocations with an AC-hook-plate. *Eur J Med Res* 2011;16:52-6.
- Kashii M, Inui H, Yamamoto K. Surgical treatment of distal clavicle fractures using the clavicular hook plate. *Clin Orthop Relat Res* 2006;447:158-64.
- Pan X, Lv Ry, Lv Mg, Zhang Dg. TightRope vs clavicular hook plate for Rockwood III-V acromioclavicular dislocations: a meta-analysis. *Orthop Surg* 2020;12:1045-52.
- Tiren D, van Bommel AJ, Swank DJ, van der Linden FM. Hook plate fixation of acute displaced lateral clavicle fractures: mid-term results and a brief literature overview. *J Orthop Surg Res* 2012;7:1-8.

15. Charity R, Haidar S, Ghosh S, Tillu A. Fixation failure of the clavicular hook plate: a report of three cases. *J Orthop Surg* 2006;14:333-5.
16. Meda PV, Machani B, Sinopidis C, Braithwaite I, Brownson P, Frostick SP. Clavicular hook plate for lateral end fractures-a prospective study. *Injury* 2006;37:277-83.
17. Monsaert A, Steenbrugge F, Van Damme R, Claus B, De Witte E, Van Nieuwenhuysse W, et al. Repair of complete acromioclavicular separations: hook-plate versus K-wiring. In: *Folia traumatologica Lovaniensia* 2003. Leuven, Belgium: Folia traumatologica Lovaniensia; 2003. p. 14-7.
18. Nadarajah R, Mahaluxmivala J, Amin A, Goodier D. Clavicular hook-plate: complications of retaining the implant. *Injury* 2005;36:681-3.
19. Esenyel C, Ozturk K, Bulbul M, Ayanoglu S, Ceylan H. Coracoclavicular ligament repair and screw fixation in acromioclavicular dislocations. *Acta Orthop Traumatol Turc* 2010;44:194-8.
20. Mardani-Kivi M, Mirbolook A, Salariyeh M, Hashemi-Motlagh K, Saheb-Ekhtiari K. The comparison of Ethibond sutures and semitendinosus autograft in the surgical treatment of acromioclavicular dislocation. *Acta Orthop Traumatol Turc* 2013;47:307-10.
21. Chen C-H, Dong Q-R, Zhou R-K, Zhen H-Q, Jiao Y-J. Effects of hook plate on shoulder function after treatment of acromioclavicular joint dislocation. *Int J Clin Exp Med* 2014;7:2564-70.
22. McConnell AJ, Yoo DJ, Zdero R, Schemitsch EH, McKee MD. Methods of operative fixation of the acromio-clavicular joint: a biomechanical comparison. *J Orthop Trauma* 2007;21:248-53.



This is an open access article distributed under the terms of [Creative Commons Attribution-NonCommercial-NoDerivatives 4.0 International License](https://creativecommons.org/licenses/by-nc-nd/4.0/).