

# Evaluation of radiologic predisposing factors for greater trochanteric pain syndrome

Erdem Şahin<sup>✉</sup>, Altuğ Tanrıöver<sup>✉</sup>

Department of Orthopaedics and Traumatology, Private Çankaya Hospital, Ankara, Turkey

## ABSTRACT

**Objectives:** Greater trochanteric pain syndrome (GTPS) is one of the causes of lateral hip pain. We aimed to determine the significance of certain anatomical parameters related to GTPS in imaging tests.

**Methods:** Data of patients who were treated with glucocorticoid injection for trochanteric bursitis in our clinic between July 2019 and July 2022 for GTPS were analyzed. The control group was constituted of patients without GTPS but with hip and spinal problems who had pelvic computerized tomography (CT) images and undergone robotic-assisted knee arthroplasty. Standard anteroposterior pelvic radiograms, pelvic CTs, or magnetic resonance images were evaluated for anatomical parameters.

**Results:** Among anatomical parameters, acetabular anteversion, length of trochanter major, and abductor index were significantly different between the patients with and without GTPS. Although mean age was different between the GTPS and control patient groups, age was not found to be correlated with any anatomical parameter. Abductor lever arm length ( $p = 0.001$ ) and abductor index ( $p = 0.009$ ) were found to be correlated.

**Conclusions:** The length of trochanter major and abductor index were shown to be predisposing anatomical parameters for GTPS.

**Keywords:** Greater trochanteric pain syndrome, hip pain, acetabular anteversion, abductor index

Greater trochanteric pain syndrome (GTPS) is one of the common causes of intractable lateral-sided hip pain. Greater trochanteric pain syndrome usually arises from gluteal tendons, peritrochanteric bursae and surrounding tissue degeneration [1]. The underlying etiology is inflammation of the trochanteric bursa with repetitive microtrauma. Chronic gluteal tendinopathy is believed to be a result of hypercellularity, irregularity of collagen fibers, increased proteoglycan synthesis, and neovascularization. Studies have shown that the production of type I collagen fibers is de-

creased while type III collagen fibers are increased. This collagen fiber combination results in weakened cross-links between fibers and deterioration of mechanical strength [2].

The prevalence of GTPS in the general population is between 10-20% and its incidence is about 1.8 per 1000 people [3]. Greater trochanteric pain syndrome may be observed in all age groups but most commonly people in their 4th-6th decades are affected while female predominance over males is about 2-3/1 [4].

Research on predisposing factors for GTPS aims

Received: April 17, 2023; Accepted: May 16, 2023; Published Online: August 6, 2023



e-ISSN: 2149-3189

**How to cite this article:** Şahin E, Tanrıöver A. Evaluation of radiologic predisposing factors for greater trochanteric pain syndrome. Eur Res J 2023;9(5):1000-1004. DOI: 10.18621/eurj.1284544

**Address for correspondence:** Erdem Şahin, MD., Private Çankaya Hospital, Department of Orthopaedics and Traumatology, Barbaros, Bülten Sok., No:14, 06700 Çankaya, Ankara, Turkey. E-mail: dr.erdemsahin@gmail.com, Phone: +90 312 426 14 50



©Copyright © 2023 by Prusa Medical Publishing  
Available at <http://dergipark.org.tr/eurj>  
[info@prusamp.com](mailto:info@prusamp.com)

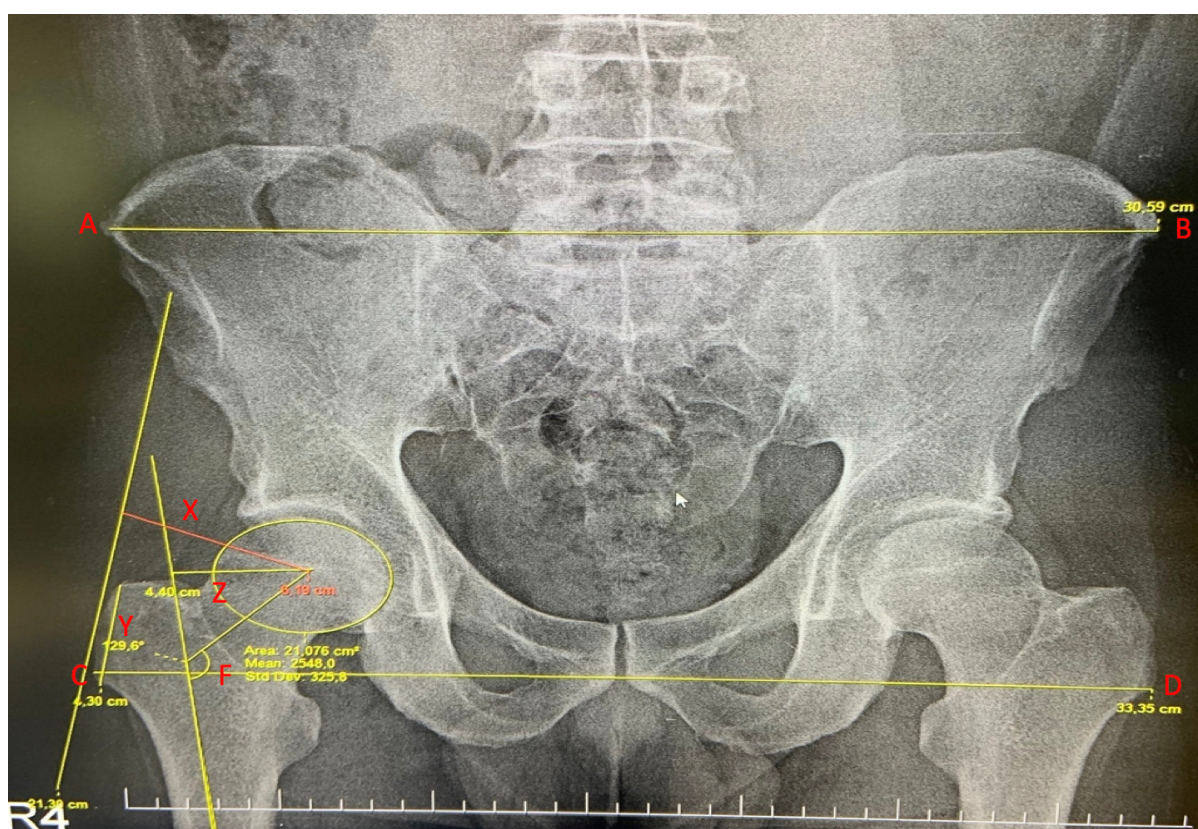
to define factors correlating with clinical outcomes and specific clinical conditions posing risks for the development of GTPS. We aimed to determine the significance of certain anatomical parameters related to GTPS in imaging tests.

## METHODS

Ethics board approval was obtained for this retrospective study. Patients who were between 30-80 years of age and treated with glucocorticoid injection for trochanteric bursitis in our clinic between July 2019 and July 2022 for GTPS were included in the GTPS patient group. Patients with hip osteoarthritis, rheumatoid conditions, history of previous hip surgery, and accompanying low back pain or previous spinal surgery were excluded. The control group was constituted of patients without GTPS but with hip and spinal problems who had pelvic computerized tomography (CT) images and had undergone robotic-assisted knee arthroplasty.

Greater trochanteric pain syndrome diagnosis was established with regard to clinical examination criteria defined by Ege Rasmussen and Fano [5]. Plain radiograms and magnetic resonance imaging (MRI) were used to evaluate gluteal tendinopathy and to exclude other pathologic conditions. Standard anteroposterior (AP) pelvic radiograms were obtained as patients were lying supine with both lower extremities in 20 degrees internal rotation and toes touching under 10% magnification.

Most lateral points of iliac crests and trochanter majors were marked on both sides and two transverse lines were drawn in AP pelvic radiograms of the GTPS patients. The ratio of length of distance between trochanter majors and iliac crests was calculated as a pelvic-trochanteric index. Anteroposterior pelvic radiograms were also used to calculate femoral offset, femoral neck-shaft angle, trochanter major length, and abductor lever arm length for patients' affected side (Fig. 1). The same measurements were obtained for the control group patients on their images of the operated knee and ipsilateral hip to prevent bias. Axial se-



**Fig. 1.** AB: Distance between most lateral points of iliac crests (cm). CD: Distance between most lateral points of trochanter majors (cm). X: Length of abductor lever arm (cm). Y: Length of trochanter major (cm). Z: Femoral offset.

**Table 1. Demographic characteristics of the GTPS and the control patients**

	GTPS	Control	<i>p</i> value
Age (years), mean ± SD	57.8 ± 13.2	70.1 ± 7.7	< 0.01
<b>Sex, n (%)</b>			
Male	6 (20)	2 (6.9)	0.276
Female	24 (80)	27 (93.1)	

GTPS = Greater trochanteric pain syndrome, SD = standard deviation,

ries of MRI of the GTPS patient group was used to determine acetabular anteversion (AA). Pelvic CT images were used to determine AA in the control patient group.

### Statistical Analysis

The distribution of numerical parameters was analyzed with the Kolmogorov-Smirnov test. Numerical parameters were expressed as mean (standard deviation). Categorical parameters were expressed as percentages. Numerical parameters of the GTPS and the control patient groups were compared with independent sample t-test. The correlation between parameters was tested with the Pearson correlation coefficient. *P* values lower than 0.05 was accepted as statistically significant.

### RESULTS

Anatomical measurements of 30 patients who were treated with corticosteroid injection for the diagnosis of GTPS were compared with the measurements of 29 patients who had undergone robotic assisted knee arthroplasty. Mean age of the control group was significantly higher (Table 1). Among anatomical parameters, acetabular anteversion, length of trochanter major and abductor index were significantly different between the GTPS and control patient groups (Table 2).

Although the mean age of the control group patients was higher, age was not found to be correlated with any anatomical parameter. Abductor lever arm length (*p* = 0.001) and abductor index (*p* = 0.009) was found to be correlated.

**Table 2. Comparison of anatomical parameters**

	GTPS	Control	<i>p</i> value
Acetabular anteversion (°)	19.0 ± 6.8	22.7 ± 6.1	<b>0.029</b>
Distance between most lateral points of iliac crests (cm),	32.6 ± 1.9	31.7 ± 2.6	0.187
Distance between most lateral points of trochanter majors (cm)	34.1 ± 1.6	33.2 ± 2.1	0.63
Pelvic-trochanteric index	0.95 ± 0.04	0.95 ± 0.06	0.741
Femur collum-diaphysis angle (°)	128.2 ± 6.9	127.0 ± 5.4	0.445
Femoral offset (cm)	4.7 ± 0.7	5.0 ± 0.7	0.110
Length of trochanter major (cm)	4.0 ± 0.4	3.7 ± 0.5	<b>0.001</b>
Length of abductor lever arm (cm)	6.1 ± 0.6	6.2 ± 0.7	0.173
Abductor index	0.7 ± 0.1	0.6 ± 0.1	< <b>0.01</b>

Data are shown as mean±standard deviation. GTPS = Greater trochanteric pain syndrome

Pelvic trochanteric index = ratio of length between most lateral points of iliac crests (cm) to length between most lateral points of trochanter majors(cm). Abductor index = ratio of length of trochanter major (cm) to length of abductor lever arm(cm).

## DISCUSSION

Greater trochanteric pain syndrome is a complex phenomenon with symptoms that may also be present in many other conditions [6]. The term GTPS has replaced trochanteric bursitis due to various etiologic factors causing posterolateral hip pain. Relation of the iliotibial tract and mid-lumbar dermatomes (L2-L4) to surrounding neural structures as superior and inferior gluteal nerves causes radiation of pain in the posterolateral region [7]. These nerves innervate the femoral neck, three gluteal muscles, and tensor fascia which may be relevant to pain in femoro-acetabular impingement syndrome [8].

Many etiologic factors had been described in the literature for GTPS. These are: repetitive activities, mechanical overload affecting cellular response, erroneous and high-intensity exercise, sedentary lifestyle, fatty infiltration, scoliosis, and limb length discrepancy [1, 2].

Pelvic morphotype was assumed to be a risk factor for lateral hip pain. It was shown that trochanter major is more prominent in people with femoral neck varus, resulting in more pressure on gluteus medius and minimus tendons by iliotibial band causing chronic inflammation [9]. In our study, a comparison of the femoral collum-diaphyseal angle measurements between the GTPS and the control patients has not yielded significant difference, which does not support the hypothesis.

Govaert *et al.* [10] reported pain-free survival in 7 patients out of 12 patients with intractable GTPS who had undergone retrochanteric reduction osteotomy with an aim to decrease the femoral offset. Our data showed no significant difference with regard to femoral offset between the GTPS and the control patients. This may be interpreted as femoral reduction osteotomy to decrease femoral offset may have a limited role in the treatment of GTPS.

Another study by Pelsser *et al.* [11] demonstrated that increased acetabular anteversion was related to gluteal tendinopathy and trochanteric bursitis by interfering with the biomechanics of gluteal tendons. In contrast, increased anteversion of acetabulum was observed more frequently in the control group in our study.

Santos *et al.* [12] showed that pelvic trochanteric index was increased in females with GTPS. However,

we didn't demonstrate any significant difference with regards to the pelvic trochanteric index when the GTPS and control group patients or males and females were compared.

Length of trochanter major and abductor index were significantly higher in GTPS patients when compared to the control patients. We hypothesized that; increased length of trochanter major is a predisposing factor for GTPS, independent of the abductor lever arm, as it increases the surface area thus advancing cellular strain and decreasing healing response to microtraumas.

Canetti *et al.* [13] demonstrated that decreased sacral slope was associated with decreased pelvic tilt, and this interferes with gluteal tendon biomechanics. Hence, patients having GTPS also suffer from low back pain [13]. Likewise, in a study on 247 patients with low back pain, Tortelani *et al.* [7] indicated 20% of patients had GTPS simultaneously. In our study, we excluded patients with back pain and history of spinal surgery thus avoided spinopelvic predisposing factors to have a bias on the interpretation of the results.

## Limitations

Our study has some limitations. First of all, it has a retrospective design. Second, as only anatomical predisposing factors were inspected, clinical parameters known to be relevant as body mass index or smoking were not evaluated.

## CONCLUSION

Length of trochanter major and abductor index have been shown to be predisposing anatomical parameters for GTPS. Similar studies on large patient series may guide the way for possible treatment options.

## Authors' Contribution

Study Conception: EŞ; Study Design: EŞ; Supervision: AT; Funding: EŞ, AT; Materials: EŞ, AT; Data Collection and/or Processing: AT; Statistical Analysis and/or Data Interpretation: EŞ; Literature Review: EŞ; Manuscript Preparation: EŞ, AT and Critical Review: AT.

## Informed consent

Institutional review board approval was obtained for this cohort study (No: KAEK 2021/12-204). Con-

sent was obtained from the patients who were included in the study.

### *Conflict of interest*

The author disclosed no conflict of interest during the preparation or publication of this manuscript.

### *Financing*

The author disclosed that they did not receive any grant during conduction or writing of this study.

## REFERENCES

1. Fearon A, Stephens S, Cook J, Smith P, Neeman T, Cormick W, et al. The relationship of femoral neck shaft angle and adiposity to greater trochanteric pain syndrome in women. a case control morphology and anthropometric study. *Br J Sports Med* 2012;46:888-92.
2. Reid D. The management of greater trochanteric pain syndrome: a systematic literature review. *J Orthop* 2016;13:15-28.
3. Lievense A, Bierma-Zeinstra S, Schouten B, Bohnen A, Verhaar J, Koes B. Prognosis of trochanteric pain in primary care. *Br J Gen Pract* 2005;55:199-204.
4. Long SS, Surrey DE, Nazarian LN. Sonography of greater trochanteric pain syndrome and the rarity of primary bursitis. *AJR Am J Roentgenol* 2013;201:1083-6.
5. Ege Rasmussen KJ, Fanø N. Trochanteric bursitis. Treatment by corticosteroid injection. *Scand J Rheumatol* 1985;14:417-20.
6. Williams BS, Cohen SP. Greater trochanteric pain syndrome: a review of anatomy, diagnosis and treatment. *Anesth Analg* 2009;108:1662-70.
7. Tortolani PJ, Carbone JJ, Quartararo LG. Greater trochanteric pain syndrome in patients referred to orthopedic spine specialists. *Spine J* 2002;2:251-4.
8. Dunn T, Heller CA, McCarthy SW, Dos Remedios C (2003) Anatomical study of the “trochanteric bursa”. *Clin Anat* 2003;16:233-40.
9. Grimaldi A, Fearon A. Gluteal tendinopathy: integrating pathomechanics and clinical features in its management. *J Orthop Sports Phys Ther* 2015;45:910-22.
10. Govaert LH, van der Vis HM, Marti RK, Albers GH. Trochanteric reduction osteotomy as a treatment for refractory trochanteric bursitis. *J Bone Joint Surg Br* 2003;85:199-203.
11. Pelsler V, Cardinal E, Hobden R, Aubin B, Lafortune M. Extraarticular snapping hip: sonographic findings. *AJR Am J Roentgenol* 2001;176:67-73.
12. Santos LEN, Navarro TP, Machado CJ, de Amorim Cabrita HAB, Pires RE, Figuriado LB, et al. Relationship of the Pelvic-Trochanteric Index with greater trochanteric pain syndrome. *Clinics (Sao Paulo)*. 2021;76:e3312. Published 2021 Nov 26. doi:10.6061/clinics/2021/e3312
13. Canetti R, de Saint Vincent B, Vieira TD, Fièrè V, Thaunat M. Spinopelvic parameters in greater trochanteric pain syndrome: a retrospective case-control study. *Skeletal Radiol* 2020;49:773-8.



This is an open access article distributed under the terms of [Creative Commons Attribution-NonCommercial-NoDerivatives 4.0 International License](https://creativecommons.org/licenses/by-nc-nd/4.0/).