

# Chest Pain in Children

## Çocuklarda Göğüs Ağrısı

Utku PAMUK, Hazım Alper GÜRSU

Department of Pediatric Cardiology, University of Health Sciences, Ankara City Hospital, Ankara, Turkey



### ABSTRACT

Chest pain is one of the most common reasons for admission to the emergency department, pediatrics and pediatric cardiology clinics in childhood. While pain is not usually caused by a serious cause, it can be of concern to the patient and their parents. Clinicians should inform the family of the benign nature of chest pain, unless they consider an important underlying cause. Routine referral of these patients to the cardiology department is not recommended, as it increases family and patient anxiety and may cause unnecessary evaluation. Chest pain can occur at any age, but its incidence increases after 10 years of age. The most frequent causes are costochondritis, chest wall muscle pain due to trauma or muscle strain and respiratory tract diseases. Cardiac reasons are rare with a prevalence of less than 6% and further diagnostic studies does not always necessary.

**Key Words:** Chest pain, Children, Pediatric cardiology

### ÖZ

Göğüs ağrısı, çocukluk çağında acil servis, pediatri ve çocuk kardiyoloji kliniklerine en sık başvuru nedenlerinden biridir. Ağrı genellikle ciddi bir nedenden kaynaklanmasa da, hasta ve ebeveynleri için endişe kaynağı olabilir. Klinisyenler, alta yatan önemli bir neden olduğunu düşünmedikçe, aileyi göğüs ağrısının iyi huylu doğası hakkında bilgilendirmelidir. Aile ve hasta kaygısını arttırdığı ve gereksiz değerlendirmelere neden olabileceği için bu hastaların rutin olarak kardiyoloji bölümüne sevk edilmesi önerilmemektedir. Göğüs ağrısı her yaşta ortaya çıkabilir, ancak 10 yaşından sonra görülme sıklığı artar. En sık nedenler kostokondrit, travma veya kas gerilmesine bağlı göğüs duvarı kas ağrısı ve solunum yolu hastalıklarıdır. Kardiyak nedenlerin prevalansı %6'dan daha azdır ve daha ileri tanısal çalışmalar her zaman gerekli değildir.

**Anahtar Kelimeler:** Göğüs ağrısı, Çocuklar, Pediatrik kardiyoloji

### INTRODUCTION

Chest pain is one of the most common reasons for admission to the emergency department, pediatrics and pediatric cardiology clinics in childhood (1, 2). While pain is not usually caused by a serious cause, it can be of concern to the patient and their parents. Clinicians should inform the family of the benign nature of chest pain, unless they consider an important underlying cause. Routine referral of these patients to the cardiology

department is not recommended, as it increases family and patient anxiety and may cause unnecessary evaluation (3).

Chest pain can occur at any age, but its incidence increases after 10 years of age. The most frequent causes are costochondritis, chest wall muscle pain due to trauma or muscle strain and respiratory tract diseases. Although cardiac causes have been shown to be as high as 17% in pediatric cardiology outpatient admissions, they are rare with a prevalence of less than 6% in pediatric polyclinics and pediatric emergency department

0000-0001-7046-8571 : PAMUK U  
0000-0003-4795-4066 : GÜRSU HA

**Conflict of Interest / Çıkar Çatışması:** On behalf of all authors, the corresponding author states that there is no conflict of interest.

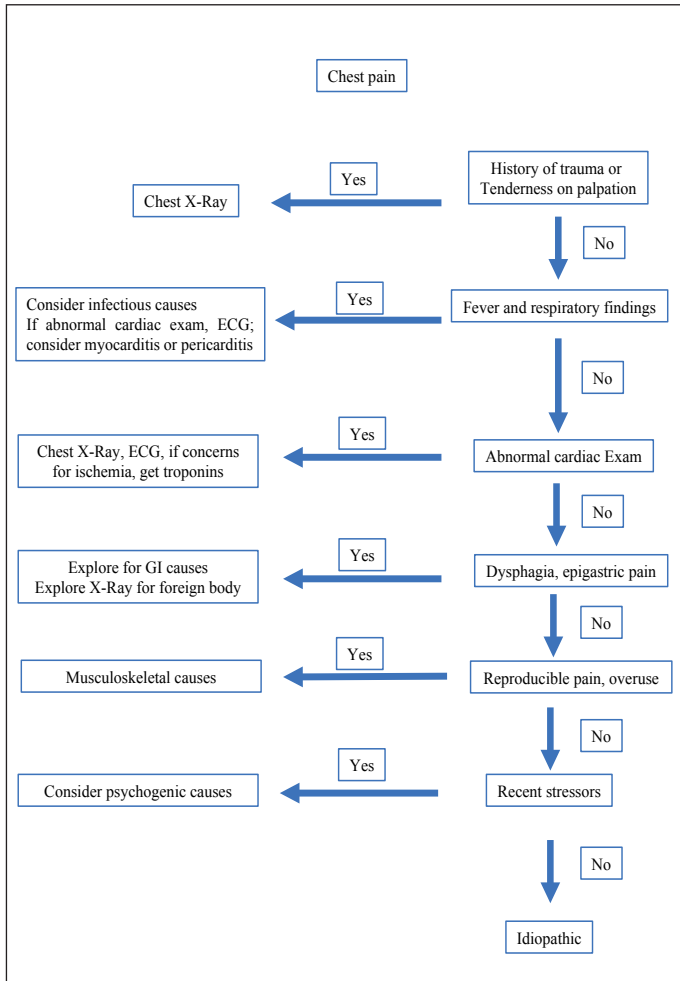
**Contribution of the Authors / Yazının Katkısı:** **PAMUK U:** Constructing the hypothesis or idea of research and/or article, Planning methodology to reach the Conclusions, Organizing, supervising the course of progress and taking the responsibility of the research/study, Taking responsibility in patient follow-up, collection of relevant biological materials, data management and reporting, execution of the experiments, Taking responsibility in logical interpretation and conclusion of the results, Taking responsibility in necessary literature review for the study, Taking responsibility in the writing of the whole or important parts of the study, Reviewing the article before submission scientifically besides spelling and grammar. **GÜRSU HA:** Constructing the hypothesis or idea of research and/or article, Planning methodology to reach the Conclusions, Organizing, supervising the course of progress and taking the responsibility of the research/study, Taking responsibility in patient follow-up, collection of relevant biological materials, data management and reporting, execution of the experiments, Taking responsibility in logical interpretation and conclusion of the results, Taking responsibility in necessary literature review for the study, Taking responsibility in the writing of the whole or important parts of the study, Reviewing the article before submission scientifically besides spelling and grammar.

**How to cite / Atıf Yazım Şekli :** Gürsu HA and Pamuk U. Chest Pain in Children. Turkish J Pediatr Dis 2023;17:328-333.

Correspondence Address / Yazışma Adresi:

**Hazım Alper GÜRSU**  
Department of Pediatric Cardiology,  
University of Health Sciences, Ankara City Hospital, Ankara, Turkey  
E-posta: hagursu@yahoo.com.tr

Received / Geliş tarihi : 06.05.2023  
Accepted / Kabul tarihi : 07.06.2023  
Online published : 20.07.2023  
Elektronik yayın tarihi  
DOI: 10.12956/tchd.1287099



**Figure 1:** Chest pain diagnostic algorithm

admissions, and further diagnostic studies are not always necessary (2, 4-6) (Figure 1). Table I lists common non-cardiac causes of chest pain in children.

### Noncardiac Chest Pain

Chest pain is noncardiac in origin in more than 98% of children (7). Causes are most often found on thorax and respiratory system (3). Noncardiac causes can be classified as musculoskeletal, pulmonary, gastrointestinal, and miscellaneous.

#### Musculoskeletal / Chest-Wall Pain

The most common cause of chest pain in children is chest-wall pain. The prevalence can reach up to 31% (8). Idiopathic causes being the most frequent; costochondritis, Tietze syndrome, trauma and muscle strain, xiphoid pain are the main causes.

Costochondritis is characterized by unilateral sharp pain along upper costochondral joints. It is more common in girls older than 12 years of age. Pain is usually exaggerated by deep breathing or a specific position and lasts from a few seconds to minutes. Tenderness on palpation on the affected area is diagnostic. There is no sign of inflammation. It is a benign, self-limited situation but pain can persist for several months.

**Table I: Non-cardiac Causes of Chest Pain in Children**

Musculoskeletal
Costochondritis
Muscle strains
Trauma to chest wall
Abnormalities of the thoracic spine
Tietze syndrome
Respiratory
Asthma
Pneumonia
Pleural effusion
Pneumothorax or pneumomediastinum
Pulmonary embolism
Gastrointestinal
Gastroesophageal reflux disease
Peptic ulcers
Esophageal spasm
Esophagitis-gastritis
Cholecystitis
Pancreatitis
Psychogenic
Anxiety
Panic
Somatoform disorder (conversion)
Depression
Emotional distress
Miscellaneous
Mastalgia
Herpes zoster
Sickle cell disease
Precordial catch
Slipping rib syndrome
Pleurodynia
Thoracic tumor

Tietze's syndrome is nonsuppurative inflammation of the costochondral, costosternal or sternoclavicular joints particularly the second and third costochondral junctions, characterized by swelling and tenderness of the affected area. It can be preceded by a respiratory tract infection with coughing or retching (9). Symptoms are usually accompanied by radicular arm pain. It is usually self-limited and analgesics can be used. In its chronic, medically refractory form intercostal nerve block or surgical intervention has been suggested (10).

Musculoskeletal chest pain is caused by strains of the muscles after exercise, coughing, trauma as well as continued muscle strain from video gaming. Rest and reassurance are the primary treatments but for the patients who have severe pain non-steroidal anti-inflammatory drugs for 1 week can be helpful.

#### Respiratory

The prevalence of chest pain due to air-way and pulmonary causes is 10% to 20% (3). Pulmonary pain can be originated from the main air-ways, parietal pleura, chest-wall muscles or diaphragm.

Asthma and exercise-induced bronchospasm are common causes of respiratory chest pain and should be considered in patients particularly with history or family history of asthma,

eczema, allergies. In these patients, chest pain is usually benign, not localized, retrosternal, and most likely secondary to chest-wall muscle strain after excessive cough and, dyspnea or hyperinflation (11). Rarely it is secondary to serious causes like pneumothorax or pneumomediastinum (5).

Chest pain in patients with pneumonia, parapneumonic effusion, pleuritis is typically sharp, and can be localized laterally. However, these patients are usually unwell. Respiratory pain can be resent as ipsilateral shoulder pain as a result of diaphragmatic irritation of the phrenic nerve.

Pulmonary embolism is extremely rare in children. It has been reported in children with hypercoagulation syndromes and female adolescents using oral contraceptives. It may manifest as hypoxia with the symptoms of dyspnea, pleuritic pain, cough, and fever(12).

### **Psychogenic**

Psychogenic chest pain is a diagnosis of exclusion, and should be considered after a thorough history taking and follow-up examination. Its incidence is higher in teenagers, especially girls (8, 14). Recent psychologic or emotional stress can trigger the pain and it may last longer than 6 months. It is more common in children with a family history of cardiac disease (15). This kind of pain is vague and may be localized over the heart and radiate to the left arm. It may occur at rest and does not worsen with exercise. Often, the parents are extremely anxious, while the child exhibits the classic indifference seen in many psychosomatic disorders.

Anxiety-related hyperventilation is a very common form of psychogenic pain. Although the cause is psychological, a hypocapnoeic alkalosis after dysfunctional breathing can cause coronary artery vasoconstriction, resulting in real physical pain (16). Physiotherapist can help the patient learn breathing techniques to prevent dysfunctional breathing.

Anxiety-related hyperventilation is a very common form of psychogenic pain. Although the cause is psychological, a hypocapnoeic alkalosis after dysfunctional breathing can cause coronary artery vasoconstriction, resulting in real physical pain (10). Physiotherapist can help the patient learn breathing techniques to prevent dysfunctional breathing.

### **Miscellaneous**

#### **•Breast development**

During puberty can cause pain in girls and boys with gynecomastia. Trauma, mastitis and particularly in post pubertal girls, breast cysts may lead to localized pain.

#### **•Herpes Zoster**

It can produce sharp, localized pain due to intercostal neuralgia. Pain can be present before the skin lesions and worsens with deep breathing and movement. With healing of skin eruptions, the pain typically resolves however postherpetic

neuralgia may persist. In these cases, gabapentin or local anesthetic blocks can be considered.

#### **•Precordial Catch Syndrome (Texidor's twinge)**

This is a sharp, brief, well-localized pain, most commonly seen in healthy individuals between 6 and 12 years of age (17). It is an extremely common but etiology is unknown. The origin of the pain may come from the parietal pleura or chest-wall muscles (18). The pain is typically localized below the left breast or left sternal border, rarely lasts longer than 1 min, does not radiate and usually worsens with deep inspiration (17). Careful history-taking is necessary to reveal diagnostic features of the syndrome. The pain may recur frequently. No treatment is needed but reassurance is helpful (19).

#### **•Slipping-Rib Syndrome**

It is an infrequent cause of recurrent chest or abdominal pain in children. It occurs as a result of luxation of the costal cartilage as a result of inadequacy or rupture of the interchondral fibrous ligaments in the 8th, 9th and 10th ribs which does not attach directly to the sternum (20). This can cause rib laxity and intercostal nerve entrapment. The hooking maneuver, a reproduction of the pain and producing a clicking and popping sound by pulling inferior ribs slightly superiorly, and anteriorly, is positive in these patients. Rest and anti-inflammatory medications may be helpful. In severe cases local anesthetic blocks, and surgery can be performed.

#### **•Pleurodynia (Devil's grip)**

Pleurodynia is also known as Bornholm disease, is a rare underdiagnosed etiology of chest pain in adolescents. It is caused by enterovirus infections, most commonly of the Coxsackie B group. It is characterized by sudden episodes of pleuritic and abdominal pain. The pain may be accompanied by fever, myalgia, and upper respiratory symptoms. It is self-limited and usually resolves within 1 to 7 days.

### **Cardiac Causes of Chest Pain**

Chest pain, although only 2% to 5% of children are of cardiac origin, is a concern for the patient and their parents (3). One study reported that up to 56% of adolescents with chest pain believed they had heart disease (21). Cardiac causes was found to be statistically significant in patients with chest pain accompanied by fever, dyspnea, palpitations, pallor and pathological murmur on examination (22). Patients feel the pain in the precordial or substernal area as a deep, heavy pressure sensation, and the pain may radiate to the neck, jaw, arms, back, or the abdomen. Pericardial or myocardial inflammatory diseases, coronary artery abnormalities, increased myocardial demand or decreased supply, medication or drug abuse that may induce coronary vasoconstriction are the main causes of cardiac chest pain in children (23) (Table II).

**Table II: Cardiac Causes of Chest Pain in Children**

Inflammatory
Pericarditis
Myocarditis
Post-pericardiotomy syndrome
Ischemic
Coronary artery diseases
Kawasaki disease
Congenital coronary artery abnormalities
Cycle cell disease
Hypertension
Severe aortic stenosis, pulmonary stenosis
Eisenmenger's syndrome
Hypertrophic obstructive cardiomyopathy
Dilated cardiomyopathy
Mitral valve prolapse
Drug abuse
Aortic dissection (Marfan syndrome, Turner syndrome, Noonan syndrome)
Arrhythmias
Supraventricular tachycardia
Frequent premature ventricular contractions

**Inflammatory Causes: Pericarditis, Myocarditis**

Pericardial inflammation may occur in viral, bacterial, rheumatological causes and post-pericardiotomy syndrome after recent open-heart surgery. Patients identify a sharp, constant precordial pain, typically worsens by lying down and relieved by sitting or bending forward. ECG may show low QRS voltages due to pericardial effusion, widespread ST-T segment elevation, deflection of the PR segment in the direction opposite to P wave.

Myocarditis is a serious cause of chest pain in children. In children over 10 years of age, lightheadedness, syncope are more frequent, whereas respiratory presentations are more common in younger children (24). Tachypnoea, hepatomegaly and tachycardia are frequently present on physical examination. Common ECG findings include tachycardia, T wave and ST segment changes.

**Ischemic Myocardial Diseases**

In these diseases in which the oxygen demand of the heart or oxygen supply to the heart is diminished, chest pain typically tends to worsen with exercise and relieve with rest. Acute myocardial infarction is rarely seen in children. It can be seen in children with coronary artery diseases (Kawasaki disease, anomalous origin of coronary arteries, coronary arteriovenous or coronary cameral fistulae, Williams syndrome), familial hypercholesterolemia, previous heart transplant, sickle cell disease, cardiac myxoma, hypercoagulable states, drug abuse, and metabolic diseases such as homocystinuria and mucopolysaccharidosis. Cardiac examination may be normal but ECG may show ST-T segment changes or old myocardial infarction. For the diagnosis, computed tomography or coronary angiography may be indicated.

Severe congenital obstructive lesions such as aortic or subaortic stenosis, and pulmonary stenosis may result in chest pain because of increased oxygen demand from tachycardia and increased pressure work of the ventricle. A prominent murmur is heard on examination and ventricular hypertrophy or strain pattern is found on ECG. Echocardiography is diagnostic.

Pulmonary arterial hypertension is a rare but serious clinical condition and can cause chest pain. It can be difficult to diagnose and often has a fatal course. It may be secondary to congenital heart diseases, pulmonary and collagen tissue diseases or it may be idiopathic. The most common symptom in these patients is dyspnea, especially with exercise, but 3% may have chest pain (25).

Hypertrophic or dilated cardiomyopathy can cause chest pain because of ischemia or arrhythmias.

About 3.5% of aortic dissection cases occur in the adolescent period (26). It is more common in patients with coarctation of the aorta, aortic stenosis, Turner's syndrome, Marfan's, Ehler-Danlos and Noonan's syndrome (27). Trauma, cocaine use and weight lifting are other risk factors. Echocardiography or computed tomography is helpful for diagnosis.

Vague, brief chest pain not associated with exercise has been identified in 20% of patients with mitral valve prolapse (3). The etiology is not clearly understood, but it is thought to be due to tension of the papillary muscles.

**Arrhythmias**

Arrhythmia is a common cause of chest pain of cardiac origin in children. It has been found to occur with a frequency of 2% in children presenting to the emergency department with chest pain (22). Especially in tachyarrhythmias, it occurs due to both increased oxygen demand of the heart and decreased blood supply due to shortened diastole time.

**Approach to the Pediatric Patient with Chest Pain**

In children with chest pain, care should be taken to ensure that the pain is not due to a cardiac or other important etiology. Even though a detailed anamnesis and physical examination are usually sufficient for this, further investigations may be performed in patients in whom the cause cannot be identified.

**History**

As organic causes are more common in acute pain, the onset of pain should be questioned in history. In patients with pain that awakens from sleep and is exacerbated by exercise, organic causes have been found to be more common. Factors such as eating, exercise, trauma, and psychological stressors that aggravate or elicit pain should be questioned. Children may not always be able to describe the sensation of pressure, crushing and squeezing radiating to the neck, which are typical characteristics of cardiac pain. Causes involving the chest wall increase with motion, whereas in patients with pericarditis, the pain relieves when the patient sits or leans forward and worsens when lying down.



Cardiac causes are more common in patients with palpitations and syncope. History of fever may be due to cardiac causes such as myocarditis, pericarditis as well as other diseases such as pneumonia.

In addition, drug use such as oral contraceptives or the use of drugs that cause coronary vasospasm in adolescents should be questioned.

Medical history should include Kawasaki disease, asthma, diabetes mellitus, sickle cell disease, connective tissue disease, and Marfan syndrome. Family history should focus on the presence of a family member with unexplained or sudden death.

### **Physical Examination**

Physical examination should start with vital signs, followed by the patient's general appearance in terms of anxiety, skin color, and level of alertness. Tachycardia or tachypnea may be identified in patients with severe cardiac or respiratory organic disease. In patients with fever, infectious or inflammatory causes may be underlying. In children with familial hypercholesterolemia, xanthomas can be detected on the skin, especially on the palms, elbows, knees and buttocks. Attention should be paid to the presence of stigmata of Marfan syndrome and other connective tissue diseases, which can potentially lead to serious heart disease.

Palpation of the chest wall is usually painful in patients with musculoskeletal problems. Subcutaneous emphysema may be present over the neck and supraclavicular region in patients with pneumomediastinum. In patients with coarctation or aortic dissection, there is a pressure gap between the upper and lower extremities and the femoral pulse is weak or absent.

On lung auscultation, wheezing, crackles, decreased breath sounds are found in patients with lung disease. The heart should be auscultated to identify murmurs, rhythm irregularities, gallop rhythm and rub. Distant heart sounds, jugular venous distention and narrow pulse pressure can be found in significant pericardial effusion.

Hepatomegaly may suggest heart failure. A study found epigastric tenderness in 33% of patients presenting to a pediatric cardiology outpatient clinic with chest pain, with endoscopic abnormalities identified in 98% of them (28).

### **Investigations**

In the majority of patients, history and physical examination are usually satisfactory, but in a minority of patients, several investigations may be performed when a cardiac disease is strongly suspected.

Chest radiography should be obtained in patients with respiratory distress, abnormal heart or lung auscultation findings. It can reveal useful findings about the size of the heart, pericardial and pleural effusion and pulmonary pathologies.

ECG should be acquired in patients with syncope or pain with activity, abnormal cardiac auscultation finding, or in patients with clinically suspected myocarditis or pericarditis. ECG may reveal rhythm disturbances; ST-PR segment, T wave changes and low voltage in inflammatory or ischemic diseases; ventricular hypertrophy or strain sign in diseases such as valvular stenosis and aortic coarctation (29).

Laboratory tests are rarely necessary. Complete blood count and acute phase reactants may be useful in infectious diseases. Cardiac enzymes are helpful in ischemic or inflammatory disorders such as myocarditis. One study showed that troponin levels were found to be elevated in 54% of patients with myocarditis (30, 31). It can also be elevated in myopericarditis. D-Dimer can be high in patients with pulmonary thromboembolism.

Echocardiography is recommended especially in patients with exertional chest pain, abnormal ECG findings, family history of cardiomyopathy or sudden/unexplained death (32). Structural heart diseases, cardiomyopathies and most of the coronary artery diseases can be diagnosed with the help of echocardiography. It is not recommended in patients with benign family history, absence of ECG abnormalities and tenderness on chest wall palpation. Further cardiac imaging such as CT or MRI may be needed in patients whom echocardiographic imaging is not diagnostic.

### **Treatment**

Treatment of chest pain is based on the underlying cause. Since most patients have myalgia, it is usually helpful to inform the patient and family that the pain is not cardiac in nature and to reduce their anxiety related to the pain. Medication is usually not necessary but nonsteroidal anti-inflammatory drugs may be useful. If a cardiac etiology is suspected, referral to a further center is recommended.

## **REFERENCES**

1. Yeh TK, Yeh J. Chest pain in pediatrics. *Pediatric Annals* 2015;44:e274-e8.
2. Öztürk K, Çetin İ, Ekici F, Kocabaş A, Şaylı TR. Etiology of Chest Pain in Children. *Turkish J Pediatr Dis* 2015;9:248-53.
3. Park MK. Child with Chest Pain. *Pediatric cardiology for practitioners E-Book: Elsevier Health Sciences* 2014.
4. Fyfe DA, Moodie DS. Chest pain in pediatric patients presenting to a cardiac clinic. *Clinical pediatrics* 1984;23:321-4.
5. Öztürk K, Çetin İ, Özışık K, Ekici F, Şaylı TR. A Rare Cause of Chest Pain in Children: Spontaneous Pneumomediastinum. *Turkish J Pediatr Dis* 2013;7:1-3.
6. Chun JH, Kim TH, Han MY, Kim NY, Yoon KL. Analysis of clinical characteristics and causes of chest pain in children and adolescents. *Korean J Pediatr* 2015;58:440.
7. Johnson JN, Driscoll DJ. Chest pain in children and adolescents. *Moss and Adams' Heart Disease in Infants, Children, and Adolescents: Including the Fetus and Young Adult: Ninth Edition: Wolters Kluwer Health Adis (ESP);* 2016.

8. Selbst SM, Ruddy RM, Clark B, Henretig FM, Santulli Jr T. Pediatric chest pain: a prospective study. *Pediatrics* 1988;82:319-23.
9. Aeschlimann A, Kahn M. Tietze's syndrome: a critical review. *Clin Exp Rheumatol* 1990;8:407-12.
10. Fishman SM. Bonica's management of pain: 4<sup>th</sup> ed. Philadelphia: Lippincott Williams & Wilkins; 2012.
11. Ives A, Daubeney P, Balfour-Lynn I. Recurrent chest pain in the well child. *Arch Dis Child* 2010;95:649-54.
12. Agha BS, Sturm JJ, Simon HK, Hirsh DA. Pulmonary embolism in the pediatric emergency department. *Pediatrics* 2013;132:663-7.
13. Berezin S, Medow M, Glassman M, Newman L. Chest pain of gastrointestinal origin. *Arch Dis Child* 1988;63:1457-60.
14. Kenar A, Örün UA, Yoldaş T, Kayalı Ş, Bodur Ş, Karademir S. Anxiety, depression, and behavioural rating scales in children with non-cardiac chest pain. *Cardiol Young* 2019;29:1268-71.
15. Pillay A, Laloo M. Psychogenic pain disorder in children. *S Afr Med J* 1989;76:195-6.
16. Neill WA, Hattenhauer M. Impairment of myocardial O<sub>2</sub> supply due to hyperventilation. *Circulation* 1975;52:854-8.
17. Gumbiner CH. Precordial catch syndrome.(Featured CME Topic: Precordial Catch Syndrome). *South Med J* 2003;96:38-42.
18. Fam AG, Smythe HA. Musculoskeletal chest wall pain. *CMAJ* 1985;133:379-89.
19. Aygun E, Aygun ST, Uysal T, Aygun F, Dursun H, Irdem A. Aetiological evaluation of chest pain in childhood and adolescence. *Cardiol Young* 2020;30:617-23.
20. Saltzman DA, Schmitz ML, Smith SD, Wagner CW, Jackson RJ, Harp S. The slipping rib syndrome in children. *Pediatr Anesth* 2001;11:740-3.
21. Pantell RH, Goodman Jr BW. Adolescent chest pain: a prospective study. *Pediatrics* 1983;71:881-7.
22. Massin MM, Bourguignon A, Coremans C, Comté L, Lepage P, Gérard P. Chest pain in pediatric patients presenting to an emergency department or to a cardiac clinic. *Clin Pediatr* 2004;43:231-8.
23. Veeram Reddy SR, Singh HR. Chest pain in children and adolescents. *Pediatr Rev* 2010;31:e1-e9.
24. Freedman SB, Haladyn JK, Floh A, Kirsh JA, Taylor G, Thull-Freedman J. Pediatric myocarditis: emergency department clinical findings and diagnostic evaluation. *Pediatrics* 2007;120:1278-85.
25. van Loon RLE, Roofthoof MT, van Osch-Gevers M, Delhaas T, Strengers JL, Blom NA, et al. Clinical characterization of pediatric pulmonary hypertension: complex presentation and diagnosis. *J Pediatr* 2009;155:176-82. e1.
26. Fikar CR, Amrhein JA, Harris JP, Lewis ER. Dissecting aortic aneurysm in childhood and adolescence: case report and literature review. *Clin Pediatr* 1981;20:578-83.
27. Care RP. Health supervision for children with Marfan syndrome. *Pediatrics* 2013;132:e1059-e72.
28. Sabri M, Ghavanini A, Haghghat M, Imanieh M. Chest pain in children and adolescents: epigastric tenderness as a guide to reduce unnecessary work-up. *Pediatric Cardiol* 2003;24:3-5.
29. Friedman KG, Alexander ME. Chest pain and syncope in children: a practical approach to the diagnosis of cardiac disease. *J Pediatr* 2013;163:896-901. e3.
30. Durani Y, Egan M, Baffa J, Selbst SM, Nager AL. Pediatric myocarditis: presenting clinical characteristics. *Am J Emerg Med* 2009;27:942-7.
31. Brown JL, Hirsh DA, Mahle WT. Use of troponin as a screen for chest pain in the pediatric emergency department. *Pediatr Cardiol* 2012;33:337-42.
32. Chamberlain RC, Pelletier JH, Blanchard S, Hornik CP, Hill KD, Campbell MJ. Evaluating appropriate use of pediatric echocardiograms for chest pain in outpatient clinics. *J Am Soc Echocardiogr* 2017;30:708-13.